

## MALFORMAÇÃO ARTERIO-VENOSA NUM ADULTO JOVEM: QUANDO E COMO REPARAR

### ARTERIOVENOUS MALFORMATION IN A YOUNG ADULT: THE PARADIGM OF WHEN AND HOW TO REPAIR

Sara Luísa Vilela Leite de Magalhães<sup>2</sup>, Joana Ferreira<sup>\*1,3,4</sup>, Alexandre Carneiro<sup>5</sup>, Sandrina Braga<sup>1</sup>, João Correia Simões<sup>1</sup>, Celso Carrilho<sup>1</sup>, Amílcar Mesquita<sup>1</sup>

1. Vascular Surgery Department - Hospital da Senhora da Oliveira, Guimarães

2. Riga Stradins University

3. Life and Health Science Research Institute (ICVS), School of Medicine, University of Minho, Guimarães/Braga, Portugal

4. Centro Académico e de Formação Guimarães

5. Radiology Department - Centro Hospitalar de Trás-os-Montes e Alto Douro

Recebido a 05 de agosto de 2019

Aceite a 07 de outubro de 2019

### RESUMO

As malformações arteriovenosas são as anomalias vasculares mais raras, mas também as que estão associadas a pior prognóstico. Os autores apresentam o caso clínico de uma doente jovem com uma malformação arteriovenosa no ombro esquerdo. A indicação e as opções terapêuticas foram discutidas por peritos nacionais e internacionais numa reunião do Núcleo de Anomalias Vasculares Congénitas e Cirurgia Vascular Pediátrica que decorreu em Lisboa em 2018. Neste artigo os autores transmitem a opinião dos peritos e fazem uma revisão teórica sobre as opções terapêuticas neste tipo de malformação.

### Palavras-chave

Malformação arteriovenosa; Fístula arteriovenosa; Malformação de alto fluxo

### ABSTRACT

Arteriovenous malformations are the least common vascular anomalies, but they can have a worst prognosis when compared with other vascular anomalies. In this way, the authors present a case of young female with arteriovenous malformation on the left shoulder. The indication and the treatment options were discussed within national and international experts at the Conference of Vascular Anomalies in Lisbon in 2018. The authors shared their opinions and made a revision on this topic.

### Keywords

Arteriovenous malformation; Arteriovenous fistula; Fast-flow vascular malformation

### INTRODUCTION

Arteriovenous malformations (AVMs) are fast-flow vascular malformations with an abnormal connection between the arteries and veins, called a 'nidus' and arise due to developmental errors in the capillary bed during embryogenesis<sup>(1)</sup>. Many abnormal connections can be present in AVMs. They are the least common vascular anomalies, but they can behave aggressively when compared to other malformations<sup>(2,3)</sup>.

### CLINICAL CASE

A 21-years-old female patient was referred to our hospital, one year ago, due to a mass in her left shoulder and sporadic pain with no relation to movements. Presently the patient adds up that the left hand becomes tired after physical labor (more evident with internal rotation and flexion of the arm), however the daily activities were not impaired due to these complaints. This lady was born premature (28 weeks),

---

\*Autor para correspondência.

Correio eletrónico: joana222@hotmail.com (J. Ferreira).

is nullipara, uses the contraceptive pill, is a non-smoker, never underwent surgeries, denies any other pathologies and has no complaints regarding the other organic systems - with a special attention: non cardiac complain (the ECG and Echocardiogram performed had no changes).

In the Vascular Surgical anamnesis is important to highlight that: the limbs present equal size; there are prominent veins at left shoulder and chest; at touch there is no warmth sensation; the radial, cubital, brachial and axillary pulses are present; left bruit and thrill are present; without identifiable anisophymia (Figure 1). Auscultation of the heart and lungs is normal.

The Doppler- ultrasound and the angio-RM showed: an arteriovenous malformation (Figure 2 and 3).

So far no invasive procedures were performed nor specific medication was prescribed. This case was presented at the Conference of Vascular Anomalies in Lisbon 2018 (Núcleo de Anomalias Vasculares Congénitas e Cirurgia Vascular Pediátrica), where it was discussed within national and international experts. It was proposed a conservative treatment and flow-up, with regular clinical observation and echocardiogram. If the patient complains about heart failure, limb ischemia or recurrent ulcerations/bleeding an intervention will be taken

## DISCUSSION/CONCLUSION

AVMs are challenging lesions to treat and the indication is based on the presence of complications.

Although AVMs are present at birth, they might not become evident until childhood or later in life<sup>(1)</sup>. AVMs are sensitive to hormonal changes and often progress in adolescence, during pregnancy, and during estrogenic medication<sup>(1)</sup>. Often, they are evident in the second or third decade of life and persist throughout, they are sometimes misdiagnosed as haemangiomas or capillary malformations<sup>(1)</sup>. Lesions are pulsatile with a palpable bruit or thrill, warm, and not easily compressible<sup>(1)</sup>. The rapid shunting of blood leads to insufficient capillary perfusion with reduced oxygen delivery causing ischemia, pain, and development of wounds and bleedings<sup>(2)</sup>.

When large enough, AVMs can cause congestive heart failure and compression of the surrounding<sup>(2)</sup>. Treatment of AVMs is based on endovascular embolization, surgical resection, or a combination of both. Complete cure is rare, and treatments therefore aim at controlling the vascular anomaly symptoms<sup>(1)</sup>. The treatment options are conservative measures, endovascular and surgical excision. The endovascular treatment success is based on nidus obliteration<sup>(1)</sup>. Endovascular embolization can be performed using transarterial, transvenous,

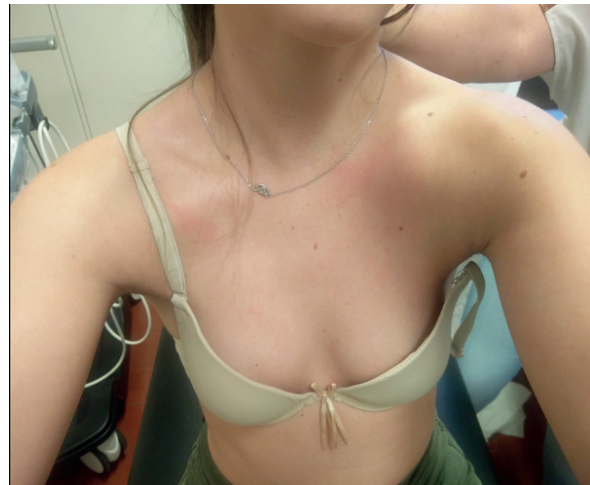

Fig. 1 Visible enlargement on the left shoulder girdle

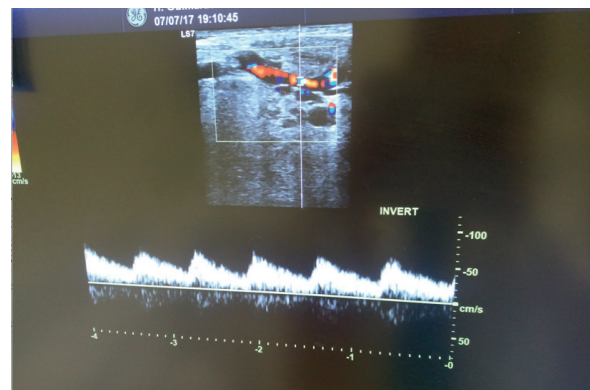


Fig. 2 AVF anomaly on color Doppler US.

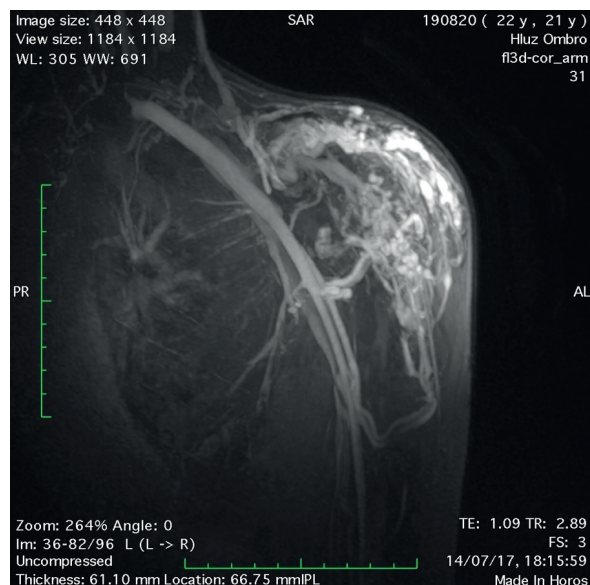


Fig. 3 MRI showing the extension of the AVF malformation



or direct-puncture techniques, and techniques are often combined<sup>(1)</sup>. The embolic material can be liquid or solid, such as coils, plugs, and particles<sup>(3)</sup>. This therapeutic modality can be used also preoperative or postoperative to improve surgical results<sup>(2)</sup>. The surgical excision is the initial choice in well-circumscribed and surgically accessible lesions<sup>(4)</sup>. The nidus of the malformation must be resected<sup>(4)</sup>. In this way, it will be possible to eradicate the vascular anomaly<sup>(4)</sup>. In the case described the patient does not have yet indication to perform an intervention, due to the absence of significant complaints.

## REFERENCES

1. Cox JA, Bartlett E, Lee EI. Vascular Malformations: A Review. *Semin Plast Surg* 2014;28:58-63.
2. Ranieri M, Wohlgemuth W, Müller-Wille R, Prantl L, Kehrer A, Geis S et al. Vascular malformations of upper and lower extremity - from radiological interventional therapy to surgical soft tissue reconstruction - an interdisciplinary treatment. *Clinical Hemorheology and Microcirculation* 2017;67:3-4.
3. Ramírez-Senent B, Abadal JM, Vázquez E, Lago I, Gálvez E, Araujo MA, et al. Endovascular Management of a Giant High-Flow Lower Limb Arteriovenous Malformation. *Vascular and Endovascular Surgery* 2017;51(8):572-576.
4. Kim JY, Kim DI, Do YS, Lee BB, Kim YW, Shin SW, Byun HS, Roh HG, Choo Iw, Hyon WS, Shim JS, Choi JY. Surgical treatment of congenital arteriovenous malformations: 10 years' experience. *Eur J Vasc Endovasc Surg* 2006;32:101