

## RUPTURA DE ANEURISMA DA ARTÉRIA POPLÍTEA – UMA APRESENTAÇÃO POUCO USUAL

### RUPTURED POPLITEAL ARTERY ANEURYSM – AN UNCOMMON PRESENTATION

Rita Augusto<sup>\*1,2</sup>, Jacinta Campos<sup>1,2</sup>, Andreia Coelho<sup>1,2</sup>, Nuno Coelho<sup>1,2</sup>, Evelise Pinto<sup>1</sup>, Ana Semião<sup>1</sup>, João Ribeiro<sup>1</sup>, João Peixoto<sup>1</sup>, Daniel Brandão<sup>1,2</sup>, Alexandra Canedo<sup>1,2</sup>

1. Serviço de Angiologia e Cirurgia Vascular, Centro Hospitalar de Vila Nova de Gaia/Espinho, Vila Nova de Gaia, Portugal

2. Unidade de Angiologia e Cirurgia Vascular da Faculdade de Medicina da Universidade do Porto, Porto, Portugal

Recebido a 17 de novembro de 2019

Aceite a 22 de maio de 2020

#### Palavras-chave

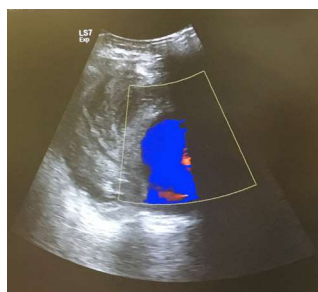Artéria poplítea; Aneurisma; Ruptura

#### Keywords

Popliteal artery; Aneurysm; Rupture

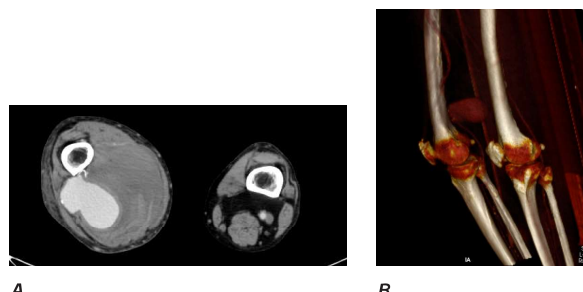
#### CLINICAL CASE

A 89-year-old male, with a prior medical history of diabetes, hypertension, bladder cancer, dyslipidemia and smoking was referred to vascular surgery urgency due to a severe swelling and pain in the popliteal space and distal limb edema of the right leg, with some weeks of evolution. The patient did not had peripheral neurological or motor deficits. He was a fragile patient but still autonomous for most of the daily activities. On admission, the patient was found to be hemodynamically stable. The femoral pulses were normal bilaterally, but the popliteal and distal pulses in the right lower limb were absent. He was submitted to a duplex ultrasound – Figure 1 – that showed a large heterogeneous tumefaction (77×47 mm) in the distal and posterior thigh: in the peripheral area predominantly hyperechoic and in central area hypoechoic with the presence of Doppler colour inside, consistent with a large popliteal artery aneurysm. He also presented a deep venous thrombosis (DVT) of the popliteal vein.



**Figure 1** Large heterogeneous tumefaction (77×47 mm) in the distal and posterior thigh. Deep venous thrombosis of the popliteal vein.

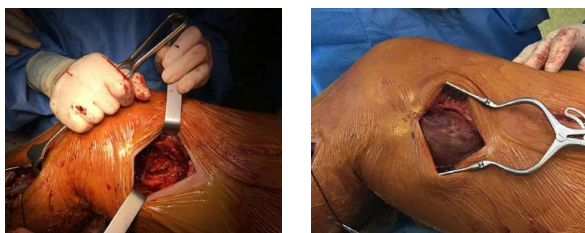
Computed tomography angiography (CTA) revealed a contained ruptured aneurysm originated from the proximal portion of the popliteal artery surrounded by a voluminous hematoma and patent distal arteries – Figure 2, being excluded the synchronous presence of aneurysms of other territories. Subsequently, the authors performed an open surgery – Figure 3 – as it follows: the superficial femoral artery proximal to the aneurysm and the below-knee popliteal artery were controlled and a large amount of thrombus involved in a pseudocapsule was removed. An interposition venous graft with homolateral reversed greater saphenous vein was made. The procedure was performed under anticoagulation and the surgeons had particularly caution with the dissection, due to the DVT. The patient was discharged one week later, with palpable anterior tibial artery pulse. He was medically treated with chronic antiaggregation and anticoagulation for the DVT. Unfortunately, he died from congestive heart failure 3 months after.



**Figure 2** A: CTA in axial plan showing a contained ruptured aneurysm (proximal portion of the popliteal artery) surrounded by a voluminous hematoma; B – CTA reconstruction

\*Autor para correspondência.

Correio eletrónico: rita.augusto1988@gmail.com (R. Augusto).



**Figure 3** A and B: Control of the superficial femoral artery proximal to the aneurysm and the below-knee popliteal artery popliteal artery. A large amount of thrombus involved in a pseudocapsule was removed. An interposition venous graft with reversed greater saphenous vein was made.

## DISCUSSION

Popliteal artery aneurysms (PAAs) are rare in the general population although they represent at least 70% of peripheral aneurysms and appear to occur preferentially in the proximal part or midportion of the artery<sup>(1)</sup>. PAAs are found almost exclusively in men. Thrombosis and distal embolization are the most common complications of PAA and can lead to severe limb-threatening ischemia<sup>(2,3)</sup>. Rupture is an unusual complication that occurs at a rate of an average of about 2-5% in larger series<sup>(2,4-6)</sup>. Around 14% have an associated popliteal vein thrombosis and hemorrhagic shock is rare because of containment of the hematoma by the small confines of the popliteal space<sup>(1)</sup>.

The risk of rupture of PAA with different diameters is virtually unknown<sup>(7)</sup>.

Although the endovascular treatment of popliteal aneurysm has become popular, open surgical repair is required in many cases, including rupture, giant aneurysm, compression syndrome, poor run-off, good saphenous vein conduit, young patient, and the presence of infection<sup>(8,9)</sup>.

Operative repair should be performed quickly. The two goals are control of bleeding and reestablishment of distal perfusion, and decompression, that is usually accomplished without special effort during the procedure itself.

A recent study based on Swedish Vascular Registry, with a cohort of forty-five patients concludes that the immediate outcome after surgery to correct ruptured PAAs was good, however, there was a high risk of death within 1 year, explained mostly by old age and frequent cardiopulmonary co-morbidities<sup>(7)</sup>.

In this particular case, the ultrasound and the AngioCT performed at admission, showed patency of distal arteries, however, the distal pulses were absent prior to the surgery. In the author's opinion, this fact is explained by the major compression of the hematoma at popliteal level, which was drained during the surgery allowing the presence of palpable distal pulses after the procedure.

Popliteal artery aneurysm presenting as rupture is an uncommon event. In this clinical case the authors highlighted the importance of an accurate clinical evaluation and diagnosis as the challenge of the management of a rare but potentially harmful entity.

## BIBLIOGRAPHY

1. Sidawy AP; Perler BA. Rutherford's Vascular Surgery and Endovascular Therapy. 9th edition ed: Elsevier; 2018
2. Ravn H, Bergqvist D, Björck M; Swedish Vascular Registry. Nationwide study of the outcome of popliteal artery aneurysms treated surgically. Br J Surg 2007; 94: 970-977
3. Ravn H, Björck M. Popliteal artery aneurysm with acute ischemia in 229 patients. Outcome after thrombolytic and surgical therapy. Eur J Vasc Endovasc Surg 2007; 33: 690-695
4. Cervin A, Tjärnström J, Ravn H, Acosta S, Hultgren R, Welander M et al Treatment of popliteal aneurysm by open and endovascular surgery: a contemporary study of 592 procedures in Sweden. Eur J Vasc Endovasc Surg 2015; 50: 342-350
5. Sie RB, Dawson I, van Baalen JM, Schultze Kool LJ, van Bockel JH. Ruptured popliteal artery aneurysm. An insidious complication. Eur J Vasc Endovasc Surg 1997; 13: 432-438
6. Roggo A, Brunner U, Ottinger LW, Largiadier F. The continuing challenge of aneurysms of the popliteal artery. Surg Gynecol Obstet 1993; 177: 565-572.
7. Cervin A, Ravn H, Björck M. Ruptured popliteal artery aneurysm. Br J Surg. 2018 Dec;105(13):1753-1758
8. Mohan I.V., Stephen M.S. Peripheral arterial aneurysms: open or endovascular surgery? Prog Cardiovasc Dis. 2013;56:36-56
9. Huang Y., Gloviczki P., Oderich G.S., Duncan A.A., Kalra M., Fleming M.D. Outcomes of endovascular and contemporary open surgical repairs of popliteal artery aneurysm. J Vasc Surg. 2014;60:631-638.e2

