

TRATAMENTO ENDOVASCULAR DE ANEURISMAS ILÍACOS BILATERAIS COM PERFUSÃO RETRÓGRADA 10 ANOS APÓS BYPASS AORTO-BIFEMORAL

ENDOVASCULAR TREATMENT OF RETROGRADE FED BILATERAL ILIAC ARTERY ANEURYSMS 10 YEARS AFTER AORTOBIFEMORAL BYPASS

Carlos Veiga¹, Duarte Rego¹, Ivone Silva¹, Daniel Mendes¹, Carlos Veterano¹, Henrique Rocha¹, João Castro¹, Andreia Pinelo¹, Henrique Almeida¹, Carolina Vaz¹, Rui Almeida¹

1. Serviço de Angiologia e Cirurgia Vascular, Centro Hospitalar Universitário do Porto

Recebido em: 28/07/2021

Aceite para publicação em: 24/09/2021

RESUMO

Introdução: O desenvolvimento de aneurismas em artérias ilíacas excluídas do fluxo de alta-pressão direto da aorta é muito incomum. Reportamos um caso de tratamento eficaz de aneurismas ilíacos metácronos (AIM) bilaterais, diagnosticados 10 anos após cirurgia de *bypass* aorto-bifemoral, apenas com perfusão retrógrada pelas artérias femorais comuns.

Caso Clínico: Um homem de 76 anos foi encaminhado para avaliação após um achado incidental de AIMs bilaterais, 10 anos após uma cirurgia de *bypass* aorto-bifemoral para tratamento de um aneurisma da aorta abdominal (AAA). O angioTAC revelou um aneurisma de 43-mm de diâmetro da artéria ilíaca interna (AII) direita e um aneurisma de 45-mm de diâmetro da artéria ilíaca comum (AIC) esquerda, que não estavam presentes 10 anos antes. A exclusão do aneurisma da AIC esquerda foi conseguida libertando dois *stents* recobertos desde a AII esquerda até à artéria ilíaca externa (AIE) de acordo com a técnica da “banana”. O aneurisma da AII direita foi excluído com embolização distal dos ramos da ilíaca interna e do saco aneurismático com *coils* e oclusão da AIE proximal com um oclisor. Não ocorreram complicações no pós-operatório. O angioTAC dois meses após a cirurgia mostrou total exclusão do aneurisma da AIC esquerda e normal preenchimento da AII esquerda, assim como oclusão completa do aneurisma da AII direita.

Conclusão: Este caso realça que a degenerescência aneurismática das artérias ilíacas pode ocorrer mesmo quando estas são perfundidas apenas por via retrógrada após tratamento de AAAs com *bypass* aorto-bifemoral. Uma abordagem endovascular com a utilização da técnica da “banana” mostrou-se eficaz no tratamento dos AIMs, com preservação do fluxo de uma AII.

Palavras-chave

Aneurismas ilíacos metácronos; Endovascular; Técnica da banana

ABSTRACT

Introduction: The development of aneurysms in iliac arteries excluded from high-pressure direct flow from the aorta is very uncommon. We report a case of successful treatment of bilateral metachronous iliac artery aneurysms (MIA), found 10 years after an aortobifemoral bypass, with perfusion only by retrograde flow from the common femoral arteries (CFA).

Case Report: A 76-year-old man came for consultation after incidental finding of bilateral MIAs, 10-years after aorto-bifemoral bypass for treatment of an aortic abdominal aneurysm (AAA). Computed tomography angiography (CTA) showed a right internal iliac artery (IIA) aneurysm of 43-mm diameter and a left common iliac artery (CIA) aneurysm of 45-mm diameter that were not present 10-years before. Exclusion of the left CIA aneurysm was achieved with a left IIA to

*Autor para correspondência.

Correio eletrónico: carlosdfveiga@gmail.com (C. Veiga).

external iliac artery (EIA) endograft using two covered stents (“banana” technique). The right IIA aneurysm was excluded with embolization of the distal internal iliac branches and aneurysm sac with coils and occlusion of the proximal EIA with an occluder. There were no postoperative complications. A CTA two months after surgery showed total exclusion of the left CIA aneurysm and normal filling of the left IIA, as well as complete occlusion of the right IIA aneurysm.

Conclusion: This case highlights that aneurysmal degeneration of iliac arteries can be generated by retrograde blood flow after treatment of AAAs with aortobifemoral grafts. An endovascular approach using the “banana” technique proved to be effective in treating MIAs while maintaining patency of one IIA.

Keywords

Metachronous iliac aneurysm; Endovascular; Banana technique

INTRODUCTION

Iliac arteries aneurysms can develop several years after AAA repair. These are referred to as metachronous iliac aneurysms (MIA). There are a few cases described in the literature, and incidence rate after AAA open-repair is 10.2% in 10-year follow-up⁽¹⁻⁵⁾. Even though in most cases MIAs do not grow substantially to warrant surgical repair, up to 9% of reported cases present with rupture^(2,6).

We report a rare case of bilateral MIAs (left CIA and right IIA) diagnosed 10-years after an aortobifemoral bypass. Aneurysms were successfully treated with bilateral endovascular exclusion. The left CIA aneurysm was treated by exclusion using a self-expandable stent graft (IIA to EIA endograft) in a “C” shaped manner (“banana” technique)^(7,8). The right IIA aneurysm was excluded after coil embolization and occlusion of the EIA. The patient gave consent for publication of the case report.

CASE REPORT

A 76-year-old man came for consultation after incidental finding of asymptomatic bilateral iliac artery aneurysms during the study of a renal cyst. Past medical history included obesity, smoking, hypertension, dyslipidemia, and ischemic heart disease. Ten years earlier, he had undergone emergent surgical repair of an 87-mm diameter ruptured AAA with a 39-mm diameter synchronous right CIA aneurysm. Intraoperatively the right CIA had been isolated and ligated distally to the right CIA aneurysm. The left CIA had been oversewn at the ostium after the sac was opened because of its tortuous path that complicated isolation. Due to the emergent character of the procedure an aortobifemoral bypass had been performed and flow was preserved to the iliac arteries by

retrograde perfusion. At that time the left CIA was 18-mm in diameter and the right IIA was 10-mm in diameter (FIGURE 1).

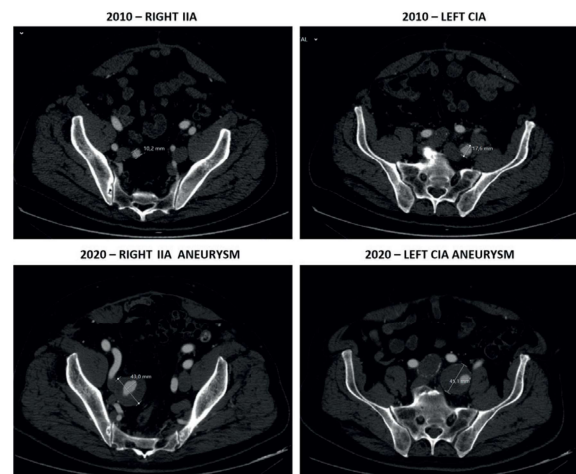


Figure 1 CTA showing right IIA and left CIA degeneration from 2010 to 2020.

A computed tomography angiography (CTA) scan was performed and confirmed aortobifemoral graft patency with the presence of a 43-mm diameter right IIA aneurysm and a 45-mm diameter left CIA aneurysm (FIGURE 1). Both EIAs and left IIA were normal in diameter. Common and superficial femoral arteries were bilaterally patent. Because of the presence of a hostile abdomen, the deep location of the iliac aneurysms and the patient increased surgical risk, we decided to perform an endovascular exclusion of both iliac aneurysms. We opted to occlude the right IIA aneurysm with coil embolization and to exclude the left CIA aneurysm with an IIA to EIA self-expanding endograft, positioned in a “C” shaped manner (“banana” technique)⁽⁷⁻⁹⁾.

The procedure was performed under general anesthesia because of the expected length of surgery and the need for surgical approach of the superficial

femoral artery (SFA). We considered surgical approach of the SFA to be safer due to the need to use large sheaths and because CFA percutaneous access was limited owing to previous aortobifemoral bypass. Retrograde access was obtained after bilateral SFA approach and insertion of 6F sheaths. The left IIA was cannulated using a 0.035-in hydrophilic guidewire and a cobra catheter. A superstiff guidewire was then positioned in the IIA and the left access was exchanged to a 10F sheath. After administration of 2 500 units of heparin a 10×100mm self-expanding endograft (Viabahn, W. L. Gore, Flagstaff, Ariz) was delivered from the distal IIA to the EIA to exclude the left CIA aneurysm. The implant was distally completed by inserting a 13×100mm self-expanding endograft with 5-cm overlap. We used endografts with different diameters because of the difference in sizes between the distal IIA (diameter of 9mm) and the EIA (diameter of 11mm). Final angiogram confirmed complete exclusion of the left CIA aneurysm with preservation of the internal iliac flow through the “C” shaped endograft (FIGURE 2).

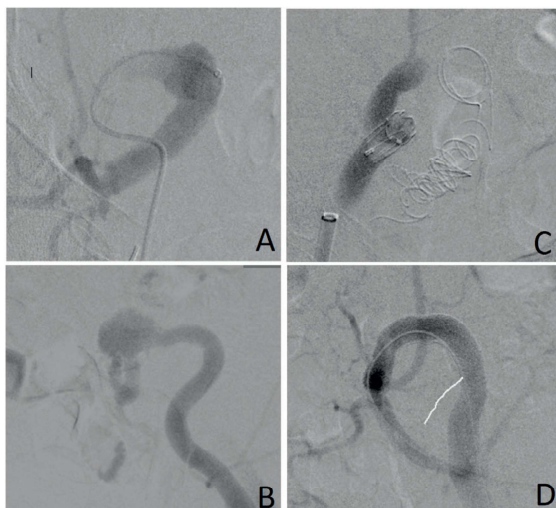


Figure 2 Pre-procedural angiograms showing patent right IIA (A) and left CIA (B). Post-procedural angiograms showing total occlusion of right IIA aneurysm after coil embolization and occlusion of the EIA (C), and total exclusion of the CIA aneurysm with an IIA to EIA endograft in a “C” shaped manner (D).

The right IIA aneurysm was then cannulated in the same fashion and a superstiff guidewire was used to introduce a 65-mm 6F sheath in the distal portion of the aneurysm. To distally exclude the IIA aneurysm, embolization of both anterior and posterior IIA branches was performed using 8-mm and 10-mm coils (Nester Embolization Coils, Cook, Inc., Bloomington, IN). The 6F sheath was then retracted and embolization of the aneurysm sac was performed with two 20-mm coils.

Occlusion of the proximal EIA was achieved with delivery of a 14-mm occluder in a 17.5F sheath (Talent Occluder, Medtronic, Minneapolis, Minn). The final angiogram confirmed complete occlusion of the right IIA aneurysm (FIGURE 2). Total procedure time was 2 hours and 54 minutes.

There were no adverse events in the postoperative period and the patient was discharged after two days in good general condition. Dual antiplatelet therapy with clopidogrel 75 mg and acetylsalicylic acid (ASA) 100 mg once daily was prescribed for a month with subsequent ASA long-term therapy. CTA scan two months after surgery showed complete success of the procedure with total exclusion of the left CIA aneurysm without endoleaks, good positioning and patency of the stent grafts and with normal filling of the left IIA artery, as well as complete occlusion of the right IIA aneurysm and EIA (FIGURE 3). At 12-months follow-up the patient is asymptomatic, with no complications associated to the procedure or reinterventions needed.

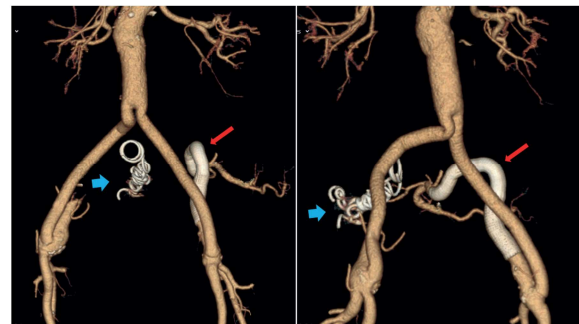


Figure 3 3D reconstruction of postoperative CTA.

DISCUSSION

The development MIAs in iliac arteries excluded from high-pressure direct flow from the aorta is very uncommon and there are only a small number of cases described in the literature^(1,3-5,10,11). When aortobifemoral bypass grafts are performed for AAA open-repair, iliac vessels perfusion is maintained only by retrograde flow from the femoral arteries. There is little evidence available concerning the natural history of iliac circulation with retrograde perfusion after AAA open-repair. In 1998, Hill et al⁽¹²⁾ presented a series of 32 patients with AAA treated by aortobifemoral bypass with a mean follow-up time of 39.3 months and reported that iliac arteries remained stable in size or thrombosed in all patients. This study included patients with pre-existing iliac artery dilation or atherosclerotic disease, emphasizing the low risk of

aneurysmal degeneration with retrograde perfusion in the short-term even in high-risk patients. The fate of iliac circulation after aortobifemoral bypass in the long-term is still undefined. Because MIAs reported in the literature required treatment between 6 to 13 years after aortobifemoral AAA open-repair, long-term follow-up is needed to better understand the risk of aneurysmal degeneration and rupture^(1,3-5,9,11).

Theoretically, by preserving direct antegrade flow to the iliac vessels, aortic tubes render a greater risk of progression of iliac aneurysmal disease when compared to aortobifemoral grafts. There appears to be no evidence in the literature to corroborate this belief. The fate of iliac circulation after aorto-aortic graft repair of AAA, with preservation of antegrade flow, has been reported in several clinical series^(2,13-15). Lavee et al⁽¹⁴⁾ (1988) followed 23 patients for 5 years after AAA tube repair and reported no significant aneurysmal degeneration of iliac vessels. Ballotta et al⁽²⁾ (2008) prospectively followed 201 patients for a mean of 7.1 years and reported low rates iliac arteries growth, with development of iliac aneurysms above 25mm only in 3 patients, none of which required surgical repair. Other authors reported similar results, concluding that most CIAs do not expand after tube graft insertion for AAA open-repair, and even when they do the degree of dilation is minimal^(13,15,16).

MIAs are usually detected during follow-up or surveillance imaging of patients previously submitted to AAA open-repair. Most patients are asymptomatic (43%), but up to 9% may present with rupture⁽⁶⁾. Most frequent symptoms are abdominal pain (35%), limb ischemia (9%) and hydronephrosis (4%)⁽⁶⁾. The management of MIAs after AAA open-repair may involve surgical exclusion with bypass graft, ligation or endoaneurysmorrhaphy. Surgical treatment of iliac aneurysms can be challenging because of the risk of major complications such as ureteral or venous injury, damage to adjacent viscera or nerves, acute limb ischemia and death⁽¹⁷⁾. In patients with previous intra-abdominal surgery, the risks associated with open reintervention are even higher. Iliac aneurysms open-repair is associated with high early-morbidity rates (43%) when compared to endovascular treatment (8%)⁽¹⁷⁾. Series report mortality rates up to 10%, higher than those reported for AAA open-repair^(8,19).

In recent years, endovascular treatment of iliac aneurysms with embolization, iliac branch endograft placement or IIA to EIA endografting proved to be a safe, simple and effective solution, associated with

low morbidity and mortality rates^(17,18). However, even these techniques are not free from complications such as graft thrombosis, endoleaks, and conversion to open surgery. The introduction of minimally invasive endovascular options in the treatment of MIAs has unlocked less aggressive ways of treatment. However, maintaining the patency of pelvic circulation must be considered when choosing the best approach. Sacrifice of unilateral or bilateral IIA perfusion is not benign and leads to pelvic ischemic complications in a significant proportion of patients. The overall incidence of buttock claudication was 28% in patients with unilateral occlusion of IIA, and 42% in patients with bilateral IIA embolization. Younger and physically active patients were at higher risk of developing these symptoms⁽²⁰⁾. In the case presented we opted to embolize the right IIA aneurysm because it ended at the bifurcation of the IIA into anterior and posterior divisions and did not present an adequate sealing length, making it technically challenging for endovascular repair. Maintaining patency of the left IIA was therefore fundamental to avoid severe complications such as gluteal/perineal skin necrosis, spinal cord ischemia and intestinal ischemia⁽²¹⁾.

The use of an IIA to EIA endograft in the treatment of iliac artery aneurysms has been previously described in the literature. In 1999, Hoffer et al⁽⁸⁾ first described its use in the treatment of bilateral CIA aneurysms combined with an aortouni-iliac stent graft, right IIA coil embolization and a right to-left femoral-femoral bypass graft. Since then, different authors have reported its effectiveness in the management of MIAs originating several years after aortobifemoral grafting for AAA open-repair^(1,9-11). In 2011, Mosquera Arochena et al⁽⁷⁾ described the procedure in the treatment of bilateral CIA aneurysms and named it the “banana” technique. Procedural success of this technique depends on choosing an appropriate stent. The advantage of using this endograft (Viabahn, W. L. Gore, Flagstaff, Ariz) is that it is extremely flexible, minimizing the risk of occlusion because of kinking in the tortuous iliac arteries.

The case described highlights the risk of aneurysmal degeneration of iliac vessel after aortobifemoral graft for AAA open-repair and demonstrates that retrograde perfusion of iliac vessels can lead to MIAs formation in the long-term. Longer follow-up and surveillance imaging of patients after AAA open-repair with aortobifemoral grafts must be contemplated, especially because most MIAs are asymptomatic and presentation might occur only at rupture.

CONCLUSION

Although this case describes a rare occurrence, it highlights that aneurysmal degeneration of iliac arteries can be generated by retrograde blood flow after treatment of AAA by aortobifemoral bypass. Endovascular embolization of the right IIA aneurysm, combined with a “C” shaped left IIA to EIA stent-endograft to exclude the left CIA aneurysm was effective in treating both aneurysms while preserving flow to the left IIA.

REFERENCES

1. Ferrero E, Psacharopulo D, Ripepi M, et al. U Stent-Graft Technique as a Treatment for Homolateral Metachronous Common Iliac and Internal Iliac Arteries Aneurysms after Open Surgery. *Ann Vasc Surg.* 2015;29(8):1659.e1-1659.e7.
2. Ballotta E, Da Giau G, Gruppo M, Mazzalai F, Toniato A. Natural history of common iliac arteries after aorto-aortic graft insertion during elective open abdominal aortic aneurysm repair: A prospective study. *Surgery.* 2008;144(5):822-826.
3. Fahlke J, Tautenhahn J, Halloul Z, Bürger T. Aneurysmaentwicklung und spätruptur von retrograd perfundierten iliakalarterien. *Zentralbl Chir.* 2001;126(12):1009-1011.
4. Mylankal KJ, Baxter Z, Perry EP. Common Iliac Aneurysm Rupture after Previous Aortic Aneurysm Resection. *Ann Vasc Dis.* 2010;3(1):74-76.
5. Duysens C, Quaniers J, Van Damme H, Limet R. Rupture d'un anévrysme iliaque externe six ans après un bypass aorto-bi-fémoral. *Rev Med Liege.* 2007;62(1):7-10.
6. Dosluoglu HH, Dryjski ML, Harris LM. Isolated iliac artery aneurysms in patients with or without previous abdominal aortic aneurysm repair. *Am J Surg.* 1999;178(2):129-132.
7. Mosquera Arochena N, Molina Herrero F, Carbalho Fernandez R, et al. Hybrid approach to AAA: bilateral “banana” technique to preserve hypogastric artery in complex anatomy aorto-biiliac aneurysm. *Rev Port Cir Cardiorac Vasc.* 2011;18(4):225-230.
8. Hoffer EK, Nicholls SC, Fontaine AB, Glickerman DJ, Borsa JJ, Bloch RD. Internal to external iliac artery stent-graft: A new technique for vessel exclusion. *J Vasc Interv Radiol.* 1999;10(8):1067-1073.
9. Salomon du Mont L, Rinckenbach S. Double Banana Technique: A Fruity Solution for Treating Iliac Aneurysms After Aortic Surgery. *Eur J Vasc Endovasc Surg.* 2018;55(4):510.
10. Derom A, Vermassen F, Ongena K. Endograft exclusion of residual common iliac artery aneurysms. *J Endovasc Ther.* 2000;7(3):251-254.
11. Kabutey NK, Deso S, Vilvendhan R, Woodson J, Kim D. External-to-internal iliac bypass using an endograft-within-wall-stent technique. *Vasc Endovascular Surg.* 2010;44(5):372-376.
12. Hill AB, Ameli FM. Fate of the iliac arteries after repair of abdominal aortic aneurysm with an aortobifemoral bypass graft. *Ann Vasc Surg.* 1998;12(4):330-334.
13. Glickman MH, Julian CC, Kimmins S, Evans WE. Aortic aneurysm: to tube or not to tube. *Surgert.* 1982;91(5):603-605.
14. Lavee J, Schneiderman J, Bass A, Amsterdam E, Walden R, Adar R. Tube graft replacement of abdominal aortic aneurysm: is concomitant iliac disease a contraindication? *J Cardiovasc Surg.* 1988;29(4):449-452.
15. Provan J, Fialkov J, Ameli FM, St Lous EL. Is tube repair of aortic aneurysm followed by aneurysmal change in the common iliac arteries? *Can J Surg.* 1990;33(5):394-397.
16. Hassen-Khodja R, Feugier P, Favre J, Nevelsteen A, Ferreira J. Outcome of common iliac arteries after straight aortic tube-graft placement during elective repair of infrarenal abdominal aortic aneurysms. *J Vasc Surg.* 2006;44(5):943-948.
17. Rana MA, Kalra M, Oderich GS, et al. Outcomes of open and endovascular repair for ruptured and nonruptured internal iliac artery aneurysms. *J Vasc Surg.* 2014;59(3):634-644.
18. Boules TN, Selzer F, Stanziale SF, et al. Endovascular management of isolated iliac artery aneurysms. *J Vasc Surg.* 2006;44(1):29-37.
19. Richardson JW, Greenfield LJ. Natural history and management of iliac aneurysms. *J Vasc Surg.* 1988;8(2):165-171.
20. Lin PH, Chen AY, Vij A. Hypogastric Artery Preservation during Endovascular Aortic Aneurysm Repair: Is It Important? *Semin Vasc Surg.* 2009;22(3):193-200.
21. Mehta M, Veith FJ, Darling RC, et al. Effects of bilateral hypogastric artery interruption during endovascular and open aortoiliac aneurysm repair. *J Vasc Surg.* 2004;40(4):698-702.