

Internal carotid artery trauma due to elongated styloid process – a review of case reports

Celso M.D. Nunes , Juliana Sousa , Joana Silva , Vânia Constâncio , Eduardo Silva , Leonor Baldaia , Miguel Silva 

Department of Angiology and Vascular Surgery, Centro Hospitalar e Universitário de Coimbra, Portugal

Submitted: June 9, 2022; Reviewed: July 10, 2022; Accepted: August 4, 2022

Presented at: 21.º Congresso da SPACV - Sociedade Portuguesa de Angiologia e Cirurgia Vascular

ABSTRACT

INTRODUCTION: Stylo-carotid syndrome is caused by the conflict between the styloid process and the vascular structures leading to carotid artery dissection (CAD) or compression. Being headache the most common initial symptom in patients with spontaneous CAD, eagle syndrome could be one explanation for some so-called spontaneous dissections since this symptom is also common in this syndrome.

METHODS: After analyzing the reported cases on Pubmed and Embase databases we divided the cases in compression and CAD groups ending up with completely different groups in terms of clinical presentation, management and follow-up.

RESULTS: While management of compression group seems quite straightforward, the same is not true when CAD is present. Whether delayed styloidectomy after medical management plays a role in CAD, as it does for the compression group, is something to investigate.

Keywords: Carotid artery dissection; carotid artery compression; Eagle syndrome; Stylo-carotid syndrome; elongated styloid process; internal carotid artery; stroke.

INTRODUCTION

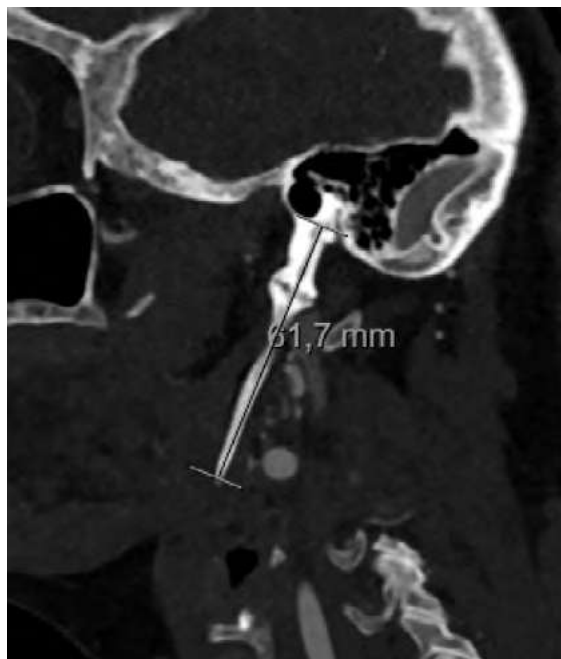The Eagle syndrome was first described by W. Eagle in 1937 who estimated the length of a normal styloid process at 2.5–3.0 cm.^[1] Two groups have been defined with elongated styloid (or calcified stylohyoid ligament), the classic form group and the vascular form group. The classic form is typically seen in patients after pharyngeal surgery. Ipsilateral cervical pain, dysphagia, sensation of a foreign body in the throat, tinnitus, or otalgia are all possible symptoms due to the anatomical proximity of cranial nerves V, VII, IX, or X. The vascular form, a rare presentation of this syndrome, is caused by the conflict with the vascular structures leading sometimes to carotid artery compression or even dissection and consequently aphasia, visual symptoms and limb motor and sensory deficit can be present. In addition, the simple stimulation of the

artery sympathetic nerve plexus can cause pain along the artery course, as also eye pain and parietal headache. Being headache the most common initial symptom in patients with spontaneous dissection of the internal carotid artery,^[2] Eagle syndrome could be one explanation for some so-called spontaneous dissections, since the estimated incidence shows that 4% of population has an elongated process^[3,4] and, even though it is a rare condition, it may be under-reported. Despite this considerable incidence on general population, only a minority (4%) of these individuals present with symptoms, both in classical and vascular forms.

The aim of this review is to summarize the current evidence on the incidence and clinical implications of the vascular form of the Eagle syndrome.



Figure 1. Computed tomography (CT) reconstruction illustrating an elongated styloid process.



METHODS

We performed an electronic search of the literature using PubMed and Embase databases. The combination of key words used in our search strategy were the following: (Eagle syndrome OR stylo-carotid syndrome) AND (carotid artery dissection OR compression OR stenosis). Only original publications in English and French were considered. Publications with insufficient information regarding patient characteristics, symptoms and treatment strategies were excluded.

Data on patient characteristics, presenting symptoms and treatment strategies were extracted to compose our case study. For analysis, cases were included in one of two groups: internal carotid compression only and carotid dissection associated with elongated styloid process.

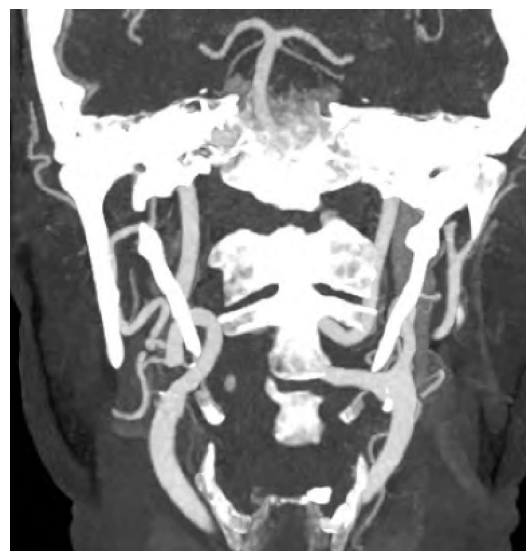
RESULTS

After removing duplicated articles and fully reading the remaining articles, our focus was established in 44 case studies. After eliminating four cases with insufficient information, 40 cases reported in 33 publications were left.^[5-37] From these, 8 cases related to carotid artery compression and 32 cases of carotid artery dissection (CAD).

The carotid artery compression group consisted of 1 female and 7 male patients, with a mean age of 55.8 years. All cases presented with symptoms of hemihypoesthesia and/or weakness of one side of the body. Aphasia was reported in three cases and reduced field of vision in one. These transient neurological events were reported to be triggered by cervical rotation to the contralateral side of the affected body in five patients and regressive in neutral position. Just one patient had a history of right hemiparesis and aphasia

resulting in long-term residual sequelae. Three case reports did not mention the cervical rotation as a factor, but multiple transient episodes were present in the clinical history. Six out of eight cases had clinical symptoms for over one year or more and only two patients presented with symptoms for less than a month. In terms of diagnostic imaging, dynamic computed tomographic angiography was the exam of election, which clearly showed an extrinsic compression of internal carotid artery in seven cases on the left side and in one on the right. Four patients had bilateral elongated styloid process and all patients were treated with surgical resection of the excessively long styloid process on the symptomatic side, except for one patient with bilateral involvement, who had a preventive resection. No patient had symptoms relapse after surgical management. Neither stenosis characterization nor medical treatment after surgical treatment were reported.

Figure 2. CT image showing the intimate relation between the internal carotid artery and the elongated styloid process leading to artery compression.



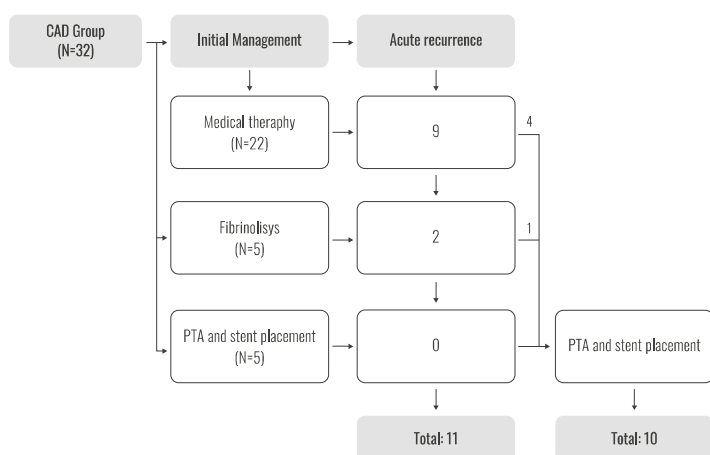
Among the 32 cases of CAD reported in the literature, 72% (23/32) were generally fit without reported comorbidities. The mean age of the group was 47.5 years old and 81% of the sample was in the interval of 40 to 60 years old. The condition was more common in men with a ratio of 2.2:1. Only 4 patients showed no focal neurological deficits and presented with sudden headache, being this symptom present in one third of the patients. Horner's syndrome was reported in three. Computed tomography and/or magnetic resonance imaging (MRI) was performed and revealed bilateral styloid elongation in 19 of 32 patients and bilateral CAD in eleven. It also showed ischemic infarcts in 59% patients and dissecting aneurysms in five.

Table 1. Synthesis of the 32 cases of CAD: demographic characteristics, clinical presentation and management;

Cases	Sex	Age	Clinical Presentation	Initial management	Acute recurrence	Bilateral dissection	Ischemic infarcts on CT/MRI	Styloidectomy
AlAbdulwahed et al ^[5]	M	35	Focal neurological deficits	Antiaggregation	Yes	No	Present	Yes
Zuber et al ^[6]	F	41	Focal neurological deficits	Anticoagulation	No	No	Not present	No
Soo-O-yan et al ^[7]	F	41	Focal neurological deficits	Anticoagulation	No	No	Not present	No
Faivre et al ^[8]	M	60	Focal neurological deficits	Fibrinolysis	No	Yes	Present	Yes
Razak et al ^[9]	M	41	Focal neurological deficits	Fibrinolysis	No	No	Not present	Yes
Todo et al ^[10]	M	57	Focal neurological deficits	Anticoagulation	Yes	Yes	Present	No
Ogura et al ^[11] (1)	M	55	Focal neurological deficits	Anticoagulation	Yes	Yes	Present	Yes
Ogura et al ^[11] (2)	M	55	Focal neurological deficits	Stent placement	Yes	No	Present	No
Sveinsson et al ^[12] (1)	M	38	Focal neurological deficits	Fibrinolysis	Yes	No	Present	Yes
Sveinsson et al ^[12] (2)	F	41	Headache	Anticoagulation	Yes	No	Not Present	No
Yammamoto et al ^[13]	M	51	Horner Syndrome	Antiaggregation	No	No	Not present	No
Ohara et al ^[14]	M	43	Focal neurological deficits	Antiaggregation	No	No	Not present	No
Jo et al ^[15]	F	38	Headache	Antiaggregation	No	No	Not present	Yes
Subedi et al ^[16]	M	57	Focal neurological deficits	Stent placement	No	No	Present	Awaiting
Heban et al ^[17]	M	57	Focal neurological deficits	Antiaggregation	No	No	Present	No
Smoot et al ^[18]	M	60	Focal neurological deficits	Anticoagulation	Yes	No	Present	No
Zammit et al ^[20]	F	45	Horner syndrome	Antiaggregation	Yes	Yes	Present	No
Torikoshi et al ^[21]	M	46	Focal neurological deficits	Antiaggregation	Yes	Yes	Present	Yes
Galletta et al ^[22]	M	53	Focal neurological deficits	Fibrinolysis	No	Yes	Present	Yes
Baldino et al ^[23]	F	41	Headache	Stent Placement	No	No	Not Present	No
Baldino et al ^[23]	M	48	Focal neurological deficits	Anticoagulation	No	No	Present	Yes
Baldino et al ^[23]	M	45	Focal neurological deficits	Anticoagulation	No	Yes	Not Present	Yes
Baldino et al ^[23]	M	49	Focal neurological deficits	Anticoagulation	No	Yes	Not Present	Yes
Baldino et al ^[23]	M	56	Headache	Anticoagulation	No	No	Not Present	Yes
Takagi et al ^[24]	M	30	Focal neurological deficits	Antiaggregation	Yes	Yes	Present	No
Duarte-Celada et al ^[25]	F	43	Horner Syndrome	Stent Placement	No	Yes	Not Present	Yes
Horio et al ^[26]	F	46	Focal neurological deficits	Stent Placement	No	Yes	Present	Yes
Brassart et al ^[27]	F	53	Focal neurological deficits	Antiaggregation	Yes	No	Present	Yes
Mattioli et al ^[27]	M	56	Focal neurological deficits	Anticoagulation	No	No	Not present	No
Xhaxho et al ^[28]	M	64	Focal neurological deficits	Antiaggregation	No	No	Present	No
Selvadurai et al ^[31]	M	17	Focal neurological deficits	Fibrinolysis	Yes	No	Present	Yes
Aydin et al ^[32]	F	57	Focal neurological deficits	Antiaggregation	No	No	Present	No

In terms of initial management, 22 patients were managed with medical therapy only: 11 with antiaggregating therapy and 11 with anticoagulation therapy, five underwent endovascular and/or intra-arterial fibrinolysis and five patients were managed initially with angioplasty and stent placement. Acute recurrence of symptoms was observed in 34% (11/32) of patients. Symptom recurrence was seen in nine patients who initially were treated with only medical therapy leading to balloon angioplasty and stent placement in four cases. Two of the five patients who underwent endovascular thrombectomy and/or intra-arterial fibrinolysis had also recurrence leading to stent placement in one. Overall,

angioplasty with stent placement was done in a total of 10 patients and no acute recurrence symptoms were reported. After initial management seventeen patients were selected for styloidectomy on a semi-elective basis. Mean follow-up was 15.4 months and three cases reported recurrence symptoms during follow-up: two cases after stent placement awaiting styloidectomy and one case under medical therapy not selected for this procedure.

Figure 3. Initial management and acute recurrence of CAD group.

DISCUSSION

Stylo-carotid syndrome can vary in its clinical presentation. On one hand, in the compression group, patients present with reproducible symptoms with cervical rotation. Neurological sequelae are not common since these events are most transient. After establishing the relationship between the carotid artery and the styloid process, the treatment with surgical resection seems logical and very effective. To establish this relation dynamic imaging plays an important role. On the other hand, in CAD group, clinical presentation is usually sudden, and the best treatment is still unknown.

As for CAD, in the general population, there is lack of level I evidence regarding the best treatment and no consensus exists whether either antiaggregating or anticoagulation is more effective^(39,41,42). In our review there was no significant difference between the antiaggregating and anticoagulation therapy in terms of symptoms recurrence. Regardless, the recurrence rate is quite high in this group, since more than one third of patients experienced symptoms despite medical treatment. Moreover, the presence of the elongated process can explain why patients keep experiencing symptoms, possibly due to the progression of the dissection and distal embolization explained by the continuous impingement of the styloid process into the carotid artery.

Surgical or endovascular intervention is usually reserved for patients with deteriorating clinical neurologic symptoms despite medical treatment, compromised cerebral blood flow, contraindications to antithrombotic therapy, symptomatic or expanding aneurysm, high grade stenosis after 6 months or new or persistent aneurysm greater than twice the diameter of the normal internal carotid segment.⁽²⁾ A recent systematic review revealed the safety and technical feasibility of stenting in CAD,⁽⁴³⁾ making it likely that this procedure could be the treatment of choice, if the patient meets the criteria described above and, given that deteriorating clinical neurological symptoms are common in this subgroup of CAD. But, in this case it is mandatory to consider styloidectomy to prevent compression and/or fracture of the stent, unless the presence of a post dissection thrombosed aneurysmal sac is present keeping the stent away from the styloid process. Whether delayed styloidectomy after medical management plays a

role in CAD, as it does for the compression group, remains undetermined.

CONCLUSION

Vascular Eagle syndrome should be considered part of differential diagnosis when confronting a young patient presenting either with transient neurological symptoms provoked by neck rotation or caused by CAD. Dynamic imaging is an important component in this setting as it can provide relevant information on surrounding relationship of the vascular structures. Although it is rare entity there is a growing number of case reports making it a possible explanation for some spontaneous CAD. Given the rarity of the condition, the ideal treatment has not yet been identified. Options include intra-arterial thrombolysis, surgical or endovascular repair, anticoagulation, and antiplatelet medication. Endovascular and surgical repair are considered a last resort but should be considered when dealing with a patient with recurrent dissection or lack of resolution. Resection of styloid process should also be contemplated on the management of carotid artery compression with or without CAD.

Acknowledgments: None

Conflicts of interest: None

Funding: None

REFERENCES

1. Eagle WW. Elongated styloid process: Report of two cases. *Arch Otolaryngol.* 1937;25:584-6
2. Sidawy, A. N., Perler, B. A., & Rutherford, R. B. (2019). *Rutherford's vascular surgery and endovascular therapy Volume 2; Chapter 96, 1269-76*
3. Raina D, Gothi R, Rajan S. Eagle syndrome. *Indian J Radiol Imaging* 2009;19:107-8
4. Rechtweg JS, Wax MK. Eagle's syndrome: A review. *Am J Otolaryngol.* 1998;19:316-21
5. AlAbdulwahed R, O'Flynn P. The Eagle Has Landed: an unusual case of Eagle's syndrome. *J Surg Case Rep* 2021;2021:rjab530
6. Zuber M, Meder JF, Mas JL. Carotid artery dissection due to elongated styloid process. *Neurology* 1999;53:1886-7
7. Soo-O-yan Y, Chan YL, Wong KS. Carotid artery dissection after prolonged head tilting while holding a newborn baby to sleep. *Neurology* 2004;62:1647-8
8. Faivre A, Abdelfettah Z, Rodriguez S. Neurological picture. bilateral internal carotid artery dissection due to elongated styloid processes and shaking dancing. *J Neurol Neurosurg Psychiatry* 2009;80:1154-5
9. Razak A, Short JL, Hussain SI. Carotid artery dissection due to elongated styloid process: a self-stabbing phenomenon. *J Neuroimaging* 2014;24:298-301
10. Todo T, Alexander M, Stokol C, Lyden P, Braunstein G, Gewertz B. Eagle syndrome revisited: cerebrovascular complications. *Ann Vasc Surg.* 2012;26:729.e1-5.
11. Ogura T, Mineharu Y, Todo K, Kohara N, Sakai N. Carotid Artery Dissection Caused by an Elongated Styloid Process: Three Case Reports and Review of the Literature. *NMC Case Rep J.* 2014;6:2:21-25.
12. Sveinsson O, Kostulas N, Herrman L. Internal carotid dissection caused by an elongated styloid process (Eagle syndrome). *BMJ Case Rep* 2013; bcr2013009878
13. Yamamoto S, Todo K, Kawamoto M, Kohara N. Carotid artery dissection associated with an elongated styloid process. *Intern Med.* 2013;52:1005-6.

14. Ohara N, Sakaguchi M, Okazaki S, Nagano K, Kitagawa K. Internal carotid artery dissection caused by an elongated styloid process: usefulness of transoral ultrasonography. *J Stroke Cerebrovasc Dis.* 2012;21:918.e7-8.
15. Jo H, Choi EH, Song J. Carotid artery dissection caused by Eagle syndrome: precision and future. *Medicine* 2017;1:173-6
16. Subedi R, Dean R, Baronos S, Dharmoon A. Carotid artery dissection: a rare complication of Eagle syndrome. *BMJ Case Rep.* 2017;13:bcr2016218184.
17. Hebant B, Guegan-Massardier E, Macaigne V, Triquenot-Bagan A. Ischemic stroke due to internal carotid artery dissection associated with an elongated styloid process (Eagle syndrome). *J Neurol Sci.* 2017 15;372:466-7
18. Smoot TW, Taha A, Tarlov N, Riebe B. Eagle syndrome: A case report of stylocarotid syndrome with internal carotid artery dissection. *Interv Neuroradiol.* 2017;23:433-6
19. Jelodar S, Ghadirian H, Ketabchi M, Ahmadi Karvigh S, Alimohamadi M. Bilateral Ischemic Stroke Due to Carotid Artery Compression by Abnormally Elongated Styloid Process at Both Sides: A Case Report. *J Stroke Cerebrovasc Dis* 2018;27:e89-e91
20. Zammit M, Chircop C, Attard V, D'Anastasi M. Eagle's syndrome: a piercing matter. *BMJ Case Rep* 2018;28;11:e226611
21. Torikoshi S, Yamao Y, Ogino E, Taki W, Sunohara T, Nishimura M. A Staged Therapy for Internal Carotid Artery Dissection Caused by Vascular Eagle Syndrome. *World Neurosurg.* 2019;129:133-9
22. Galletta K, Granata F, Longo M, Alafaci C, De Ponte FS, Squillaci D, De Caro J, Grillo F, Benedetto F, Musolino R, Grasso G, Siniscalchi EN. An unusual internal carotid artery compression as a possible cause of Eagle syndrome - A novel hypothesis and an innovative surgical technique. *Surg Neurol Int* 2019;10:10:174
23. Baldino G, Di Girolamo C, De Blasis G, Gori A. Eagle Syndrome and Internal Carotid Artery Dissection: Description of Five Cases Treated in Two Italian Institutions and Review of the Literature. *Ann Vasc Surg.* 2020;67:565.e17-24
24. Takagi M, Nishimura A, Ikenouchi H, Nishimura A, Yamaguchi E, Koge J, Saito K et al. Bilateral carotid artery dissection due to Eagle syndrome in a patient with vascular Ehlers-Danlos syndrome: a case report. *BMC Neurol* 2020;20:285
25. Duarte-Celada WR, Jin D, Neves G, Windisch T. Bilateral carotid dissection due to Eagle syndrome in a young female. *eNeurologicalSci.* 2021;16;24:100353
26. Horio Y, Fukuda K, Miki K, Hirao N, Iwaasa M, Abe H, Inoue T. Dynamic assessment of internal carotid artery and elongated styloid process in a case of bilateral carotid artery dissection. *Surg Neurol Int* 2020;27;11:163
27. Brassart N, Deforche M, Goutte A, Wery D. A rare vascular complication of Eagle syndrome highlight by CTA with neck flexion. *Radiol Case Rep* 2020;29;15:1408-12
28. Mattioli P, Baldino G, Castaldi A. A peculiar case of internal carotid dissection: "do not forget Eagle's syndrome!". *Neurol Sci* 2021;42:2527-9
29. Xhaxho S, Vyshka G, Kruja J. Eagle syndrome presenting as a neurological emergency: a case report. *Surg Neurol Int* 2021;12:257
30. Muthusami P, Kesavadas C, Sylaja PN, Thomas B, Harsha KJ, Kapilamoorthy TR. Implicating the long styloid process in cervical carotid artery dissection. *Neuroradiology* 2013;55:861-7
31. Selvadurai S, Williamson A, Virk JS, Clarke P. Eagle syndrome and carotid artery dissection: a rare skull base cause of stroke. *BMJ Case Rep* 2022;9;15:e247954
32. Usseglio J, Montoro FM, Martin S, Lerat J, Laloze J, Taibi A, Brie J. Accident ischémique transitoire, une manifestation rare du syndrome d'Eagle [Transient ischemic attack, a rare manifestation of Eagle syndrome] *Rev Stomatol Chir Maxillofac Chir Orale* 2016;117:421-4
33. David J, Lieb M, Rahimi SA. Stylocarotid artery syndrome. *J Vasc Surg* 2014;60:1661-3
34. Farhat HI, Elhammady MS, Ziayee H, Aziz-Sultan MA, Heros RC. Eagle syndrome as a cause of transient ischemic attacks. *J Neurosurg* 2009;110:90-3
35. Song JH, Ahn SK, Cho CB. Elongated styloid process as a cause of transient ischemic attacks. *JAMA Neurol* 2013;70:1072-3
36. Chuang WC, Short JH, McKinney AM, Anker L, Knoll B, McKinney ZJ. Reversible left hemispheric ischemia secondary to carotid compression in Eagle syndrome: surgical and CT angiographic correlation. *AJNR Am J Neuroradiol* 2007;28:143-5
37. Aydin E, Quliyev H, Cinar C, Bozkaya H, Oran I. Eagle Syndrome Presenting with Neurological Symptoms. *Turk Neurosurg* 2018;28:219-25
38. Menon R, Kerry S, Norris JW, Markus HS. Treatment of cervical artery dissection: a systematic review and meta-analysis. *J Neurol Neurosurg Psychiatry* 2008;79:1122-7
39. Lyrer P, Engelter S. Antithrombotic drugs for carotid artery dissection. *Cochrane Database Syst Rev* 2008;4:1-30
40. Pham MH, Rahme RJ, Arnaout O, Hurley MC, Bernstein RA, Batjer HH, Bendok BR. Endovascular stenting of extracranial carotid and vertebral artery dissections: a systematic review of the literature. *Neurosurgery.* 2011;68:856-66
41. Gompertz P, Price C, Kerry S, Norris J, Markus HS; CADISS Investigators. Antiplatelets vs anticoagulation for dissection: CADISS nonrandomized arm and meta-analysis. *Neurology* 2012;79:686-9
42. Cervical Artery Dissection in Stroke Study Trial Investigators. Antiplatelet therapy vs. anticoagulation in cervical artery dissection: rationale and design of the Cervical Artery Dissection in Stroke Study (CADISS). *Int J Stroke* 2007;2:292-6