

Vascular graft infections in open aortic surgery: who is at risk and how to treat? – a narrative review

António Duarte ^{a,b,f}, Diogo Mendes Pedro ^{b,c,d}, Ryan Gouveia e Melo ^{a,b,d,f}, Beatriz Martins ^{b,d},
Carla Mimoso Santos ^{b,c,d,e}, Gonçalo Sobrinho ^{a,b,d,f}, Ruy Fernandes e Fernandes ^{a,b,d,f}, Luís Mendes Pedro ^{a,b,d,f}

^a Division of Vascular Surgery, Heart and Vessels Department, Centro Hospitalar Universitário Lisboa Norte, Lisbon, Portugal; ^b Lisbon Academic Medical Centre, Lisbon Portugal; ^c Infectious Diseases Department, Centro Hospitalar Universitário Lisboa Norte, Lisbon, Portugal; ^d Faculty of Medicine, University of Lisbon, Lisbon, Portugal; ^e Local Coordination Group - Program for Prevention and Control of Infections and Antimicrobial Resistance (GCL-PPCIRA), Centro Hospitalar Universitário Lisboa Norte, ^f Centro Cardiovascular da Universidade de Lisboa (CCUL@RISE)

Submitted: July 9th, 2021; Reviewed: March 10th, 2022; Accepted: September 9th, 2022

ABSTRACT

INTRODUCTION: Vascular graft infections are a rare and severe complication of open aortic surgery. As such, strategies to improve diagnosis and management are paramount. Nevertheless, there is little evidence regarding the factors associated with a higher susceptibility of infection. Moreover, there is little consensus on the best diagnostic workup and most adequate approaches to control and mitigate this surgical complication. We aim to summarize the latest evidence on aortic graft infection through a narrative review.

METHODS: We conducted a literature search in a medical database (PubMed) and included studies on vascular graft infection and aortic repair.

RESULTS: So far, patient-related comorbidities (such as diabetes, smoking, advanced age and chronic kidney disease), as well as procedure-related factors (location and type of graft, postoperative hyperglycemia, bacteremia, emergency setting), have been reported. Unlike extracavitary infections, aortic graft infections may present with subtle or no clinical manifestations. Aortoenteric fistulas are the exception to the rule, carrying a significantly higher mortality rate. All patients should be thoroughly tested with full blood counts, blood cultures and extensive imaging studies. Adequate antibiotic therapy is one of the pillars of treatment and should not be delayed. The selection of the antimicrobial regimen should be personalized and made in a multidisciplinary team. Surgical strategies are of paramount importance in controlling infection. These can be divided into graft-sparing techniques and graft explantation. The choice of the appropriate approach depends on the surgeon's experience, the extent of disease and the patient's general status and comorbidities.

CONCLUSION: Aortic graft infections are a rare and severe complication of vascular surgery. A swift diagnosis and management are paramount. Despite significant efforts on how to treat the infection with more adequate antibiotic and surgical therapies, effective preventive measures and a clear definition of predisposing factors remain the main areas for future studies.

Keywords: Aortic surgery; vascular graft; graft infection; aortoenteric fistul

Corresponding Author:

António Duarte, MD | antoniomduarte94@gmail.com
Hospital de Santa Maria – Centro Hospitalar Universitário Lisboa Norte, EPE, Serviço de
Angiologia e Cirurgia Vascular. Avenida Professor Egas Moniz, 1649-028, Lisboa, Portugal.

Angiol Vasc Surg 2022;18(4):230-35
DOI: <https://doi.org/10.48750/acv.445>



INTRODUCTION

Vascular reconstruction using prosthetic vascular grafts has revolutionized the management of aortic diseases in the twentieth century, leading to a significant improvement in the quality of life of patients with vascular disease.^[1] Nevertheless, vascular graft infections (VGI), particularly in an intracavitary setting, persist as a rare but devastating complication of aortic surgery. This complication may affect both patients that underwent open aortic repair and endovascular aneurysm repair.^[2,3] Despite aggressive antimicrobial therapy and surgical treatment, the mortality and morbidity rates remain high.^[3] Reported incidence of intracavitary (i.e. intra-thoracic or intra-abdominal, such as aorto-femoral, aorto-iliac or ilio-femoral) aortic graft infections varies between 0.2% and 5%.^[4-6] Nevertheless, there are 2 characteristics that make its true incidence hard to assess: it varies according to anatomical site and emergency setting;^[4] and clinical signs of infection can appear months or years after index surgery.^[4,7]

As there is a lack of consensus and standardized evidence on aortic graft infections, we aim to summarize available data regarding key aspects of aortic graft infections, such as pathogenesis, risk factors, microbiology, diagnosis and treatment strategies.

METHODS

We conducted a literature search in Pubmed using the following search terms, either isolated or combined: “vascular graft infection”, “prosthetic infection”, “aortoenteric fistula”, “aortic repair”, “aortic surgery”. This narrative review follows the more recent publishing recommendations reported on the Scale for the quality assessment of narrative review articles (SANRA).^[8]

RESULTS

Pathogenesis and risk factors for infection

The pathogenesis of VGI is not fully understood and is likely multifactorial.

There are 2 peaks in onset of VGI after graft implantation. The first and most common occurs in the early postoperative period and is most likely related to intraoperative bacterial contamination of prosthetic graft or due to spread of infection from a contiguous site, namely following surgical wound infection. The second peak occurs at a later time and can happen due to extension from an intracavitary abscess, bacterial colonization of a thrombus, direct inoculation of infection during other surgical procedures (i.e. percutaneous drainage of a fluid collection or an abscess), new bacteremia or reactivation of a dormant graft infection.^[4] Aortoenteric fistulas can also be a source of infection in over 30% of intra-abdominal VGI, most often as a result of erosion of a graft into the duodenum and less frequently into the colon.^[4]

VGI are thought to happen most often due to either contamination at the index surgery, hematogenous infection or spread from a contiguous site. The risk of hematogenous VGI is highest in the first 2 months and decreases over

time thanks to partial endothelialization of the graft.^[4] Nevertheless, as the pseudo-intimal lining can take up to 1 year after implantation to develop, the vascular graft remains susceptible to secondary infection due to bacteremia.^[9] Contamination during surgery can occur due to the use of a breach in graft or procedure sterility, contamination from the patient's contiguous skin or exposure to visceral contents (namely in concomitant biliary, bowel and urinary procedures), or deposition of airborne particles into the surgical bed. This is particularly true in an emergency setting, with a more frequent loss of asepsis. In an observational study from Shiraev and colleagues, emergency surgeries carried a significantly higher risk for further graft infection.^[10] The most common cause of graft infection is contamination from the skin of the groin, since wound healing complications in this area are common, and in obese patients the surgical wound lies within moist skin folds.^[3] Moreover, patients that need graft revision due to failed vascular reconstruction frequently harbor bacteria within scar tissue and lymphoceles and on the surfaces of previously implanted prosthetic vascular grafts and suture material.^[9]

Even though infection has no direct significant adverse effect upon the graft itself, the infection will inevitably spread to the host tissue, resulting in inflammation and disruption of the graft - artery anastomosis, leading to the development of a false aneurysm, graft - enteric fistula, hemorrhage, which can cause limb loss or death.^[9] Additionally, the resulting bloodstream infection, secondary to a graft source of infection can result in a metastatic spread to other organs, sepsis and multiorgan failure, while being a difficult to treat sanctuary, that often requires prolonged antimicrobial therapy.^[4]

In summary, risk factors for intracavitary graft infections may be categorized into patient-related comorbidities (such as diabetes, smoking, advanced age and chronic kidney disease), as well as procedure-related factors (location and type of graft, postoperative hyperglycemia, bacteremia, emergency setting).^[2,5] On this subject, Vogel and colleagues analyzed risk factors in over 10000 patients submitted to abdominal aortic aneurysm repair. In their cohort, bacteremia reported in the index admission for repair was significantly associated with aortic graft infection (odds ratio [OR], 4.2; 95% confidence interval [CI], 1.5–11.8).^[2] Local infection, such as surgical site infection or groin infections, as well as dehiscence, represent potential bacterial entry points.^[4,11] Regarding hyperglycemia, a retrospective cohort study performed by fellow surgeons in Amsterdam reported postoperative glycemia as an independent risk factor for post-operative infections.^[12] Furthermore, Wengrovitz et al reported a significant association between diabetes and the onset of vascular surgical infections, likely associated to local immune deficiency and altered inflammatory response.^[13]

Microbiology

Traditionally *Staphylococcus aureus* was described as the most frequent microorganism identified in VGI. However, coagulase-negative staphylococci have recently emerged as the main cause of VGI and account for over two thirds of all VGI. This is likely due to appropriate perioperative prophylaxis coupled with improved operative techniques and sterilization procedures.^[4,5,11,14,15] Other organisms that

are normal indigenous flora, such as *Corynebacterium* spp., and *Cutibacterium acnes*, account for an increasing proportion of graft infections. In these cases, and contrary to staphylococcal infections, the infection tends to be delayed in onset.^[4] Enterococcal species have also been identified, often as part of polymicrobial infection along with anaerobic bacteria.^[11]

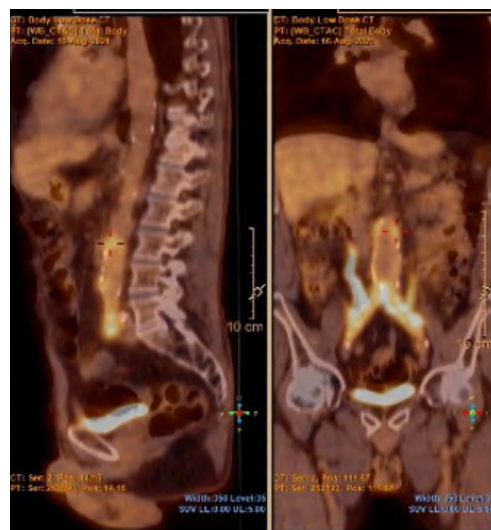
Other factors that have contributed for changes in the microbiology of graft infections are changes in hospital flora, risk factors for nosocomial infections, such as multiple revisions of previous vascular surgery, and the presence of aortoenteric fistula (increasing the risk for polymicrobial infection due to gastrointestinal microbiota). Indeed, a more diverse spectrum of microbiota is often found in patients with VGI, including multidrug resistant strains (especially gram-negatives and methicillin-resistant *Staphylococcus aureus* - MRSA), polymicrobial infection and *Candida* spp.^[11] Indeed, *Pseudomonas aeruginosa* is the most common gram-negative, accounting for 10% of VGI.^[4,5] In Portugal, Gouveia e Melo found that in the cohort of a large university hospital, most intracavitary VGI were late infections most often due to Gram-negative bacteria (58%). Of the Gram-positive bacteria, most were coagulase-negative staphylococci or enterococci.^[7]

In certain populations with specific risk factors, the suspicion for specific microorganisms such as *Pasteurella multocida* (in patients with animal scratches or bites), *Salmonella* spp. and *Coxiella burnetii* is relevant.^[5,16] Vascular Q fever, a well-recognized VGI in its own right, has been described as underlying some polymicrobial infections, perhaps increasing the risk for superinfection, and its recognition and treatment is paramount.^[16]

Clinical presentation and diagnosis

Especially in intracavitary infections, symptoms and clinical manifestations of graft infection may be subtle. Sepsis with no identified cause or prolonged ileus may be the only signs.^[9] All patients with a suspected intracavitary graft infection should be thoroughly tested with full blood counts, which may show leucocytosis and an increase in acute inflammation markers. Furthermore, blood cultures should be collected, as well as abdominal fluid and urine cultures, to assess any adjacent infectious sources for a potential aortic graft infection.^[4,9] Since graft contact to adjacent bowel is a potential source of erosion and infection, vascular surgeons should be aware if the patient develops symptoms suggestive of an aortoenteric fistula with upper gastrointestinal bleeding.^[4,17] In this latter case, the use of endoscopic method is of great importance to detect cases of intracavitary graft infection.^[17] Besides endoscopic techniques, other imaging techniques such as CT scans or abdominal ultrasound are invaluable tools to detect early signs of graft infection, such as periprosthetic fluid or gas collections, wall thickening or false aneurysms, as well as fistulous paths (Figure 1).^[4,18,19]

Figure 1. Typical finding of perigraft enhancement in a PET scan from a patient diagnosed with aortic graft infection (white arrows)



The role of PET scans is more relevant for late graft infections, as there are less obvious manifestations. Nevertheless, one must take into account some possible false-positives, such as other inflammatory states or surgery within the previous six months. In this case, it may help define and confirm the diagnosis of graft infection, as well as to assess the extent of the graft infection.^[18-20] A summary of the most frequent imaging exams used in aortic graft infection is provided in Table 1.

Table 1. Summary on the most frequent imaging exams on aortic graft infection

Complementary exam	Key findings	References
Laboratory workup	<ul style="list-style-type: none"> • Easily available • Basis for screening and initial evaluation • Rise in acute inflammatory markers (C-reactive protein, procalcitonin, leukocytosis) • Low specificity 	(9)
Cultural exams	<ul style="list-style-type: none"> • Essential for definitive diagnosis • Crucial for targeted antibiotic therapy • Indirect samples (blood cultures, adjacent foci such as urine culture): easier to collect, more useful when descaling antibiotic therapy • Main issue: • Direct samples → gold standard • Samples collected by ultrasound-guided drainage • Direct aneurysm sac guided aspiration: promising tool to determine the etiology; over 80% of collected with microbiological isolates 	(4,9)
CT angiography	<ul style="list-style-type: none"> • 1st line exam • High spatial resolution, aimed for a precise anatomical identification • May help to identify indirect findings in AGI: aortic thickening, perigraft collections, ectopic gas, fistulous tracts, false aneurysms • Moderate sensitivity/specificity 	(4,18,19)
PET scan	<ul style="list-style-type: none"> • Gold standard • Specificity and sensitivity close to 100% • More relevant for late-onset graft infections. • Assessment of the extent of the graft infection and metabolic activity. 	(18-22)

CT – Computed Tomography; PET – Positron Emission Tomography.

Treatment

Surgical management

As for any vascular graft infection, surgical strategies can be divided into graft-sparing techniques and graft explantation. The latter can be further distinguished into explantation with in situ reconstruction or extra-anatomical bypass.^(9,19) The choice of the appropriate approach depends on the surgeon's experience, the extent of disease and the patient's general status and comorbidities. A summary of the different surgical approaches on aortic graft infection is provided in Table 2.

Table 2. Summary on the different surgical approaches on aortic graft infection

	Technique	Key findings	References
Without graft excision	Periprosthetic drainage/irrigation	<ul style="list-style-type: none"> · Suitable to prevent graft infection extension · Suitable for patients with prohibitive surgical risk. · Minimally invasive procedures · Associated with high mortality rates. 	(17,21)
	Vein allograft	<ul style="list-style-type: none"> · Claggett procedure or neo aorto-iliac system bypass or NAIS Preferred strategy in patients with less comorbidities · Adequate for virulent or drug-resistant organisms. · Lowest infection (0-6%) and thrombosis rates · Low rate of complications · High one-year survival rates · Complex and demanding strategy, with a long learning curve 	(21,22)
With graft excision – in situ reconstruction	Cryopreserved vein allograft	<ul style="list-style-type: none"> · Very low infection rates (up to 7-8%) · Low thrombosis rates and higher risk of degradation · Low availability 	(21,22)
	Bovine pericardium graft	<ul style="list-style-type: none"> · Safe alternative to synthetic grafts with lower reinfection rates · Primary patency rates up to 95% and mortality rates of less than 20%, · Experience from small, single-center studies → need for larger cohorts 	(24,25)
	Antibiotic-coated graft	<ul style="list-style-type: none"> · Acceptable rates of reinfection · Particularly useful in cases of low virulence · Higher availability in an emergency / "off-the-shelf" setting 	(4, 21, 22)
With graft excision – extra-anatomical reconstruction	Extra-anatomical bypass (axillo-bifemoral, axillo-axillo bipopliteal)	<ul style="list-style-type: none"> · More relevant when considering limb revascularization · Better results when performed in a two-stage setting · Less used than in situ reconstruction · Janko et al → similar survival rates vs. in situ reconstruction · Limiting factor → morbidity and mortality rates associated to aortic stump-related complications (rupture, infection) 	(11,26,27)

Note: aorto-enteric fistulas were excluded from this table as they require a specific treatment. Because of a more severe and complex presentation, there may be a need for more extensive resection and drainage, along with bowel resection and secondary reconstructions.

In the case of aortic graft infections, further strategies may be considered. More conservative approaches such as fluid drainage and irrigation are suitable adjunctive methods to prevent graft infection extension. However, these strategies are not a definitive solution and are associated with high mortality rates.^(17,21) When considering in situ reconstruction, antibiotic-coated grafts, such as those embedded in rifampin, are associated with lower rates of reinfection and are particularly useful in cases of low virulence and may be used in an emergency setting (Figure 2).

Figure 2A. In situ reconstruction with antibiotic-coated Dacron graft after excision of an infected aortobifemoral bypass

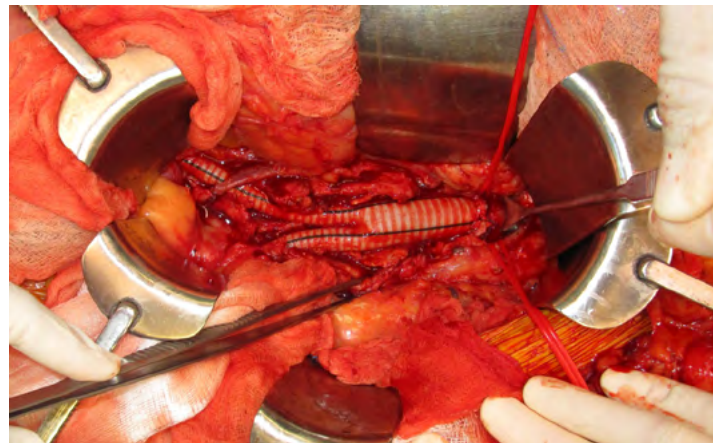
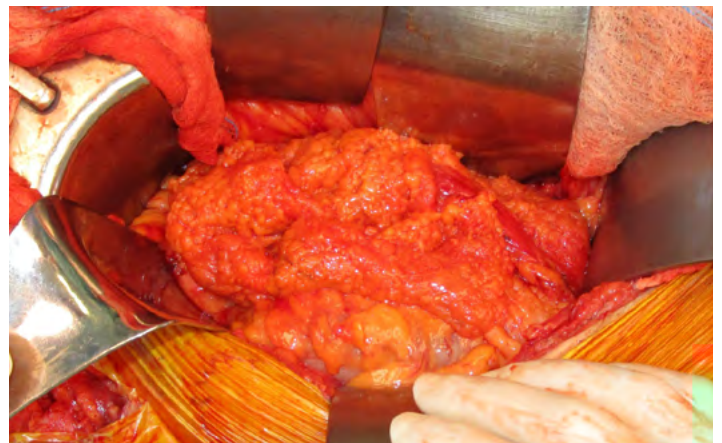

Figure 2B. Omentoplasty as an adjunctive method to prevent graft reinfection



This latter feature of rifampin-coated grafts is an advantage over cryopreserved allografts or the use of vein grafts, which may have the lowest rates of thrombosis and reinfection.^(4,9,21) This may be a preferred strategy in patients with less comorbidities or for AGI caused by more virulent or drug-resistant organisms.^(21,22) The use of deep femoral vein for abdominal aorta reconstructions (neo aorto-iliac system bypass or NAIS) was described by a group in Sweden as a surgical alternative after radical graft explantation or after removing aortic grafts in a bridge to surgery situation.⁽²³⁾ Despite its feasibility and acceptable one-year survival rates (ten out of 12 patients), the authors recognize it remains a

complex and demanding strategy. Furthermore, these imply an overall lower availability off-the-shelf. Lastly, bovine pericardium grafts represent a safe alternative to synthetic grafts with lower reinfection rates.^[24] Authors report primary patency rates up to 95% and mortality rates of less than 20%, close to the findings for other more widespread techniques.^[24,25] Although promising, these findings are derived from small, single-center studies, which urges the need for larger cohorts as well as longer follow-up periods.

In aortic graft infections, graft excision is crucial for an effective infection control. Regarding extra-anatomical bypasses (EAB), such as axillobifemoral bypasses, these are more relevant when considering limb revascularization after explanting the aortic graft.^[11,26,27] Although less used, a recent multi-center study from Janko and colleagues showed promising results. When comparing EAB with in situ repair, the latter does not seem to offer a significant survival benefit. Indeed, EAB patients did not have more complications or worse outcomes. The duration of antibiotic use was a significant factor for better surgical outcomes regardless of the surgical technique. Furthermore, Seeger et al showed satisfactory results in two-staged procedures.^[27] Patients with aorto-enteric fistula are particularly demanding to treat and intervene. In such cases, there may be a need for more extensive resection and drainage, along with bowel resection and secondary reconstructions. Because of a more dramatic and serious presentation, these patients are prone to higher rates of reintervention and postoperative complications, with mortality rates close to 100% in case of reinfection.^[19,21]

Antimicrobial treatment

The selection of the antimicrobial regimen should be personalized and made in a multidisciplinary team including the vascular surgery team, an infectious diseases specialist, the microbiology department and sometimes a clinical pharmacist.^[4] Still, empiric parenteral antibiotic therapy should usually be promptly started, with targeted activity against the expected microorganisms. As such, the knowledge of local microbiological epidemiology is paramount. Additionally, the antibiotic regimen should be chosen considering its antibiofilm activity (therefore enabling it to penetrate the biofilm), and accounting for its pharmacokinetic profile and nonvascular complications (such as sepsis or metastatic involvement of other organs). Once the antimicrobial susceptibilities become available, antimicrobial therapy should be adjusted and/or deescalated to cover the relevant microorganisms.^[5,7] Initial therapy usually includes broad Gram-positive coverage (including an anti-MRSA drug) and broad Gram-negative coverage (including *P. aeruginosa* coverage), for example with piperacillin/tazobactam (or fluoroquinolones in patients with penicillin allergy) plus vancomycin, daptomycin or linezolid for MRSA coverage. Double-coverage of Gram-negative should be considered in settings of high probability of multidrug resistant Gram-negative bacilli. If according the local epidemiology, an antibiotic in monotherapy isn't expected to be active against >90% of the expected pathogen, a double coverage regiment (such as an association of betalactamic with an aminoglycoside) should be considered to appropriate therapy (defined as "at least one of the antimicrobial agents included in the chosen regiment has in vitro activity against the etiologic pathogens").^[5,28-30] Likewise, Gouveia e Melo reported

that, in their Portuguese hospital, piperacillin/tazobactam with amikacin, plus an anti-MRSA drug is the better empiric therapy to chose especially if the patient presents severe disease or shock, due to the high prevalence of multidrug resistant gram-negatives in intracavitary VGI's (all extended-spectrum beta-lactamases producers Enterobacterials and multidrug-resistant non-fermenters).^[7]

Conservative treatment with antimicrobial therapy alone, without surgical source control, carries a high mortality.^[31] Whilst there are no clinical trials evaluating the optimal duration of antimicrobial therapy in VGI, there is consensus that at least 4 to 6 weeks of parenteral therapy is appropriate. Afterwards, an additional 3 to 6 months of oral therapy should be considered and individualized for each patient, considering the microorganism recovered and possibly the presence of elevated biochemical markers of inflammation.^[4]

An individualized approach in certain high-risk patients where surgery cannot be considered due to comorbidities, graft characteristics or extensive peri-graft infection, is possible. In these cases, lifelong suppressive antimicrobial therapy can be considered.^[4] In such cases, assessment through PET scans has been proposed as a potential means to guide the duration of antimicrobial therapy. Despite its more limited availability, this imaging modality might soon become a valuable tool in the diagnosis and management of patients with VGI. In some patients where lifelong therapy would be considered, the identification of a primary source of infection and only secondary infection of the vascular graft might be important, since in these cases antimicrobial therapy alone may be enough to eliminate the pathogen.^[18,32]

Prognosis

Despite all efforts in developing adequate surgical approaches and life-long antibiotics, aortic graft infections still carry a significant burden in patients subjected to open aortic repair. Indeed, Vascular graft infections carry a high morbidity and mortality rate (24% - 80%) that can reach 100% within the first 2 years if the graft is left in situ, or there is a lack in prompt diagnosis and treatment of a primary or secondary aortoenteric or aortobronchial fistula.^[4,5,33-35] Nevertheless, Seeger et al, reported an early mortality rate of 19%, an amputation rate of less than 5%, early graft failure in 20% and a 58% survival rate without amputation. The mortality rate was highest among patients presenting with sepsis, aortoenteric fistula and those treated with simultaneous graft excision and extra-anatomic bypass.

Focus should therefore be shifted towards preventive measures. Firstly, preoperative antibiotic schemes may contribute to a lower rate of surgical revisions due to graft infection. In a retrospective study from Salmoukas and colleagues, preoperative antibiotic schemes with daptomycin contributed to lower rates of in vivo bacterial infection and abscess formation.^[36] As previously stated, the use of autologous tissue or antibiotic-bonded grafts may also mitigate the rate of this complication.

CONCLUSIONS

Vascular graft infections are a rare and severe complication of vascular surgery, particularly in its intracavitary form such as

in patients submitted to open aortic repair. They can be severe and difficult to identify and recognize. A swift diagnosis and management with prompt source control and antimicrobial therapy is paramount. As such, this narrative review sought to thoroughly provide the most recent evidence on aortic graft infection, as there is a surge in simple and complex aortic interventions. Despite significant efforts on how to treat the infection with more adequate antibiotic and surgical therapies, effective preventive measures and identifying more susceptible populations remain the main areas for further developments. Indeed, there is a need for multi-center prospective studies to provide robust conclusions on who is truly at risk for this rare but dreadful complication.

Acknowledgements None

Conflicts of interest None

Funding None

REFERENCES

- Young MH, Upchurch GR, Malani PN. Vascular Graft Infections. *Device Assoc Infect*. 2012;26:41–56
- Vogel TR, Symons R, Flum DR. The incidence and factors associated with graft infection after aortic aneurysm repair. *J Vasc Surg* 2008;47:264–9
- Chiesa R, Astore D, Frigerio S, Garriboli L, Piccolo G, Castellano R, et al. Vascular prosthetic Graft Infection: Epidemiology, Bacteriology, Pathogenesis and Treatment. *Acta Chir Belg* 2002;102:238–47
- Wilson WR, Bower TC, Creager MA, Amin-Hanjani S, O’Gara PT, Lockhart PB, et al. Vascular Graft Infections, Mycotic Aneurysms, and Endovascular Infections: A Scientific Statement From the American Heart Association. *Circulation* 2016;134:e412–60
- Gharamti A, Kanafani ZA. Vascular Graft Infections. *Infect Dis Clin North Am* 2018;32:789–809
- Berger P, Vaartjes I, Moll FL, De Borst GJ, Blankensteijn JD, Bots ML. Cumulative Incidence of Graft Infection after Primary Prosthetic Aortic Reconstruction in the Endovascular Era. *Eur J Vasc Endovasc Surg* 2015;49:581–5
- Gouveia e Melo R, Martins B, Pedro DM, Santos CM, Duarte A, Fernandes e Fernandes R, et al. Microbial evolution of vascular graft infections in a tertiary hospital based on positive graft cultures. *J Vasc Surg* 2021;74:276–84
- Baethge C, Goldbeck-Wood S, Mertens S. SANRA—a scale for the quality assessment of narrative review articles. *Res Integr Peer Rev* 2019;4:5
- Sidawy AN, Perler BA. Rutherford’s vascular surgery and endovascular therapy [Internet]. 2019. Available from: <https://www.clinicalkey.com/#/browse/book/3-s2.0-C20151017562>
- Shiraev T, Barrett S, Heywood S, Mirza W, Hunter-Dickson M, Bradshaw C, et al. Incidence, Management, and Outcomes of Aortic Graft Infection. *Ann Vasc Surg* 2019;59:73–83
- Antonios VS, Noel AA, Steckelberg JM, Wilson WR, Mandrekar JN, Harmsen WS, et al. Prosthetic vascular graft infection: A risk factor analysis using a case-control study. *J Infect* 2006;53:49–55
- Vriesendorp TM, Moréls QJ, DeVries JH, Legemate DA, Hoekstra JBL. Early Post-operative Glucose Levels are an Independent Risk Factor for Infection after Peripheral Vascular Surgery. A Retrospective Study. *Eur J Vasc Endovasc Surg* 2004;28:520–5
- Wengrovitz M, Atnip RG, Gifford RRM, Neumyer MM, Heitjan DF, Thiele BL. Wound complications of autogenous subcutaneous infrainguinal arterial bypass surgery: Predisposing factors and management. *J Vasc Surg* 1990;11:156–61
- Vallejo N, Picardo NE, Bourke P, Bicknell C, Cheshire NJW, Jenkins MP, et al. The changing management of primary mycotic aortic aneurysms. *J Vasc Surg* 2011;54:334–40
- Hicks RCJ, Greenhalgh RM. The pathogenesis of vascular graft infection. *Eur J Vasc Endovasc Surg* 1997;14:5–9
- Puges M, Bérard X, Caradu C, Ducours M, Eldin C, Carrer M, et al. Polymicrobial Infections Among Patients with Vascular Q Fever, France, 2004–2020. *Emerg Infect Dis* 2021;27:1961–3
- Tagowski M, Vieweg H, Wissgott C, Andresen R. Aortoenteric fistula as a complication of open reconstruction and endovascular repair of abdominal aorta. *Radiol Res Pract* 2014/09/14 ed. 2014;2014:383159
- Pijl JP, Kwee TC, Slart RHJA, Glaudemans AWJM. PET/CT Imaging for Personalized Management of Infectious Diseases. *J Pers Med* 2021;11:133
- Chakfé N, Diener H, Lejay A, Assadian O, Berard X, Caillon J, et al. Editor’s Choice – European Society for Vascular Surgery (ESVS) 2020 Clinical Practice Guidelines on the Management of Vascular Graft and Endograft Infections. *Eur J Vasc Endovasc Surg* 2020;59:339–84
- Shim H, Sung K, Kim WS, Lee YT, Park PW, Jeong DS. Diagnosis of Graft Infection Using FDG PET-CT. *Korean J Thorac Cardiovasc Surg*. 2012;45:189–91
- Batt M, Jean-Baptiste E, O’Connor S, Feugier P, Haulon S. Contemporary management of infrarenal aortic graft infection: early and late results in 82 patients. *Vascular*. 2012;20:129–37
- O’Connor S, Andrew P, Batt M, Becquemin JP. A systematic review and meta-analysis of treatments for aortic graft infection. *J Vasc Surg* 2006;44:38–45.
- Nordanstig J, Törngren K, Smidfelt K, Roos H, Langenskiöld M. Deep Femoral Vein Reconstruction of the Abdominal Aorta and Adaptation of the Neo-Aortoiliac System Bypass Technique in an Endovascular Era. *Vasc Endovascular Surg* 2019;53:28–34
- Almási-Sperling V, Heger D, Meyer A, Lang W, Rother U. Treatment of aortic and peripheral prosthetic graft infections with bovine pericardium. *J Vasc Surg* 2020;71:592–8
- Alonso W, Ozdemir B, Chassin-Trubert L, Ziza V, Alric P, Canaud L. Early outcomes of native and graft-related abdominal aortic infection managed with orthotopic xenopericardial grafts. *J Vasc Surg* 2021;73:222–31
- Seeger JM, Back MR, Albright JL, Carlton LM, Harward TRS, Kubulis PS, et al. Influence of Patient Characteristics and Treatment Options on Outcome of Patients with Prosthetic Aortic Graft Infection. *Ann Vasc Surg* 1999;13:413–20.
- Seeger JM, Pretus HA, Welborn MB, Ozaki CK, Flynn TC, Huber TS. Long-term outcome after treatment of aortic graft infection with staged extra-anatomic bypass grafting and aortic graft removal. *J Vasc Surg* 2000;32:451–61
- Revest M, Camou F, Senneville E, Caillon J, Laurent F, Calvet B, et al. Medical treatment of prosthetic vascular graft infections: Review of the literature and proposals of a Working Group. *Int J Antimicrob Agents* 2015;46:254–65
- Kolasiński W. Surgical site infections – review of current knowledge, methods of prevention. *Pol Przegl Chir* 2018;91:41–7
- Elens M, Dusoruth M, Astarci P, Mastrobuoni S, Bosiers MJ, Nardella J, et al. Management and Outcome of Prosthetic Vascular Graft Infections: A Single Center Experience. *Vasc Endovascular Surg* 2018;52:181–7
- Saleem BR, Meerwaldt R, Tielliu IFJ, Verhoeven ELC, van den Dungen JJAM, Zeebregts CJ. Conservative treatment of vascular prosthetic graft infection is associated with high mortality. *Am J Surg* 2010;200:47–52
- Mahmoodi Z, Salarzaei M, Sheikh M. Prosthetic vascular graft infection: A systematic review and meta-analysis on diagnostic accuracy of 18FDG PET/CT. *Gen Thorac Cardiovasc Surg* 2022;70:219–29
- Lyons OTA, Baguneid M, Barwick TD, Bell RE, Foster N, Homer-Vanniasinkam S, et al. Diagnosis of Aortic Graft Infection: A Case Definition by the Management of Aortic Graft Infection Collaboration (MAGIC). *Eur J Vasc Endovasc Surg* 2016;52:758–63
- Davila VJ, Stone W, Duncan AA, Wood E, Jordan WD Jr, Zea N, et al. A multicenter experience with the surgical treatment of infected abdominal aortic endografts. *J Vasc Surg* 2015;62:877–83
- Erb S, Sidler JA, Elzi L, Gurke L, Battegay M, Widmer AF, et al. Surgical and Antimicrobial Treatment of Prosthetic Vascular Graft Infections at Different Surgical Sites: A Retrospective Study of Treatment Outcomes. *PLoS One*. 2014;9:e12947.
- Salmoukas C, Ruemke S, Rubalskii E, Burgwitz K, Haverich A, Kuehn C. Vascular Graft Pre-Treatment with Daptomycin Prior to Implantation Prevents Graft Infection with *Staphylococcus aureus* in an In Vivo Model. *Surg Infect* 2020;21:161–8
- Ljungquist O, Dias N, Haidl S, Sonesson B, Söreljus K, Ahl J. Guided Aspiration for Determining the Microbiological Aetiology of Aortic Vascular Graft and Endograft Infections. *Eur J Vasc Endovasc Surg* 2021;62:935–43