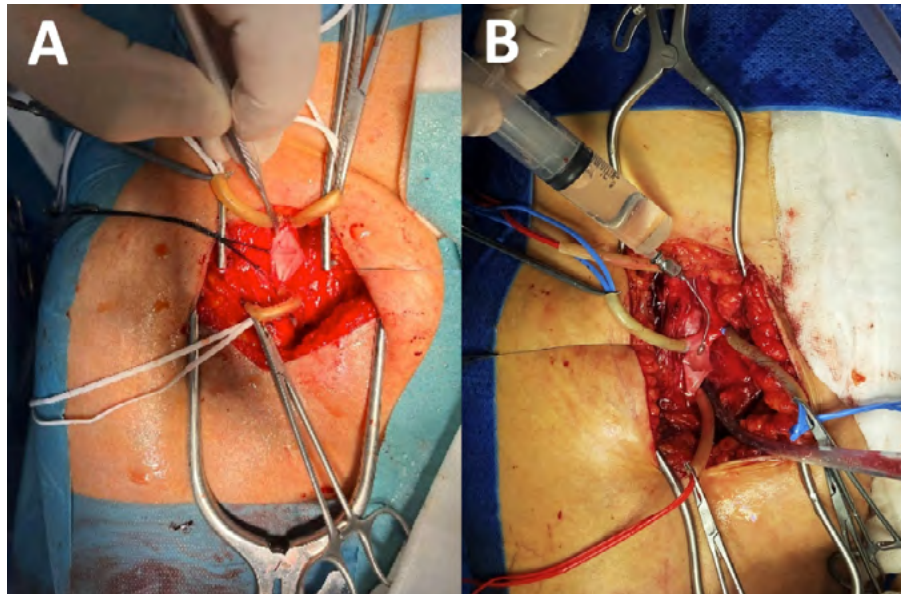


Monocuspid neovalve for deep venous reflux treatment

Sergio Silva, Nelson Camacho

Department of Vascular Surgery, Hospital da Luz, Lisbon, Portugal

Submitted: February 6, 2024; Accepted: February 6, 2024.



Deep venous reflux, associated with severe clinical manifestations and imaging demonstration of reflux from the groin to the calf, may benefit from surgical management. Monocuspid neovalve is a reconstructive alternative to vein segment transplant or venous transposition for cases of deep venous reflux associated with primary or secondary deep valve incompetence.

A 61-year-old female patient with severe post-thrombotic disease underwent ilio-femoral venous stenting 2 years prior. However, symptoms persisted with progressive worsening. Diagnostic phlebography showed reflux in the femoral and popliteal veins. A monocuspid neovalve was constructed in the femoral vein (Panel A – venotomy and

subintimal dissection to create a flap, Panel B – testing for competence of the neovalve pouch with saline infusion). After operation and after 18 months of follow-up, symptoms improved significantly and the neovalve remained patent and functional.

In well selected patients, the monocuspid neovalve allows for a rapid and significant improvement in symptoms, and prevents clinical progression of deep venous disease.

Keywords: Neovalve; deep venous insufficiency; chronic venous disease

Conflicts of interest: None

Funding: None

