

# Mosaic partial tetrasomy 10: a rare prenatal diagnosis

## Tetrassomia parcial 10 em mosaico: um diagnóstico pré-natal raro

Rita Sarabando<sup>1</sup>, Diogo Cunha<sup>1</sup>, Miguel Gonçalves-Rocha<sup>2</sup>, Alexandra Cadilhe<sup>1</sup>  
Hospital de Braga

### Abstract

Mosaic partial tetrasomy 10 is a rare chromosomal disorder. It has been associated with several fetal malformations and poor outcome. We report a case with prenatal diagnosis at 22 weeks of gestational age, whose second-trimester ultrasound scan showed several malformations. Fetal karyotype revealed a partial mosaic tetrasomy of chromosome 10 ([47,XY,+idic(10)(q11.2)[11]/46,XY[27]) classified as pathogenic. Medical termination of pregnancy was performed and fetal autopsy confirmed the ultrasound findings. There is only one case of tetrasomy 10p reported in the literature, with similar features and fetal malformations, and by sharing this rare case we hope to help in similar clinical scenarios.

**Keywords:** Abnormalities; Prenatal diagnosis; Genetic Counselling.

### Resumo

A tetrassomia parcial em mosaico do cromossoma 10 é um diagnóstico raro e tem sido associada a várias malformações fetais e a maus desfechos. Neste artigo é relatado um caso clínico com diagnóstico pré-natal às 22 semanas de idade gestacional, cuja ecografia do segundo trimestre revelou várias malformações. O cariótipo fetal revelou uma tetrassomia parcial em mosaico do cromossoma 10 ([47,XY,+idic(10)(q11.2)[11]/46,XY[27]) classificada como patogénica. Foi realizada uma interrupção médica da gravidez e a autópsia do feto confirmou os achados ecográficos. Na literatura há apenas um caso de tetrassomia 10p relatado, com malformações fetais semelhantes. Ao divulgar este caso raro pretende-se contribuir para o diagnóstico e aconselhamento pré-natal de situações semelhantes.

**Palavras-chave:** Malformações; Diagnóstico pré-natal; Aconselhamento genético.

### INTRODUCTION

Partial tetrasomy 10 has only been reported twice in the literature<sup>1,2</sup>, one of them also a mosaic<sup>1</sup>, as in the case described here. Since this condition is an extremely rare chromosomal anomaly, classified as pathogenic, it is very important to report all the diagnosed cases.

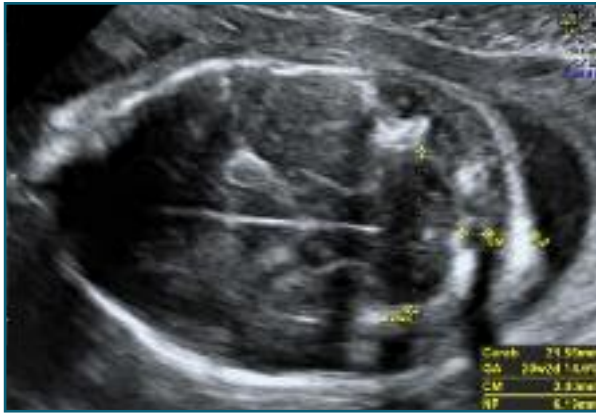### CASE REPORT

This case describes a healthy primigravida without any maternal-fetal risk factors at baseline. The first-trimester combined screening for fetal aneuploidies (maternal serum biochemical screening at 10 weeks and ultrasound scan at 12 weeks) was categorized as low risk. Furthermore, at the first-trimester ultrasound scan no fetal anomalies were detected.

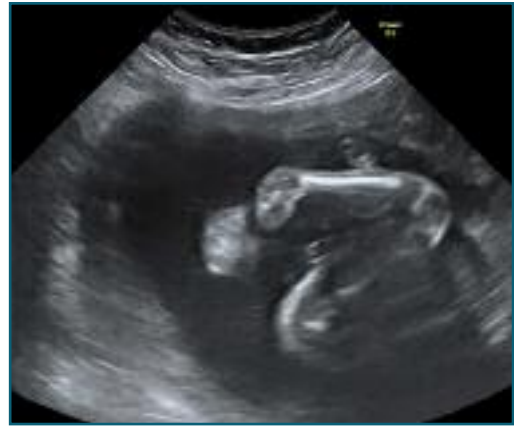Up to the second trimester of pregnancy there had been no medical or obstetric complications. At the second-trimester ultrasound scan, performed at 22 weeks of gestation, several anomalies and malformations were

1. Gynecology and Obstetrics Department, Braga's Hospital, Braga, Portugal.

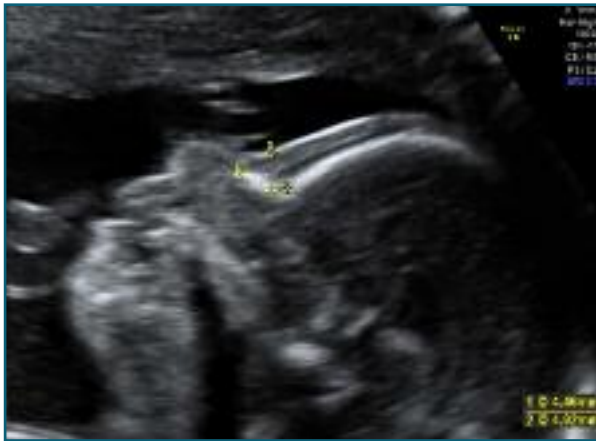2. Genetics Department, Braga's Hospital, Braga, Portugal.



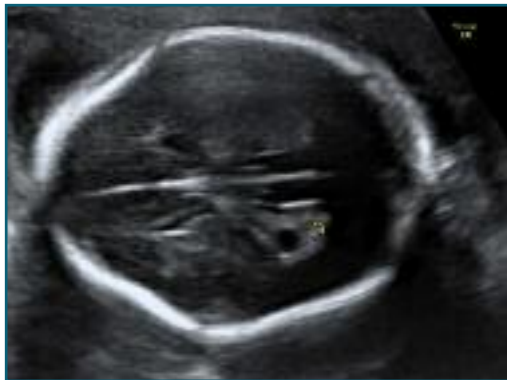
**FIGURE 1.** Fetal face profile.



**FIGURE 4.** Bilateral clubfoot.



**FIGURE 2.** Transcerebellar plane.

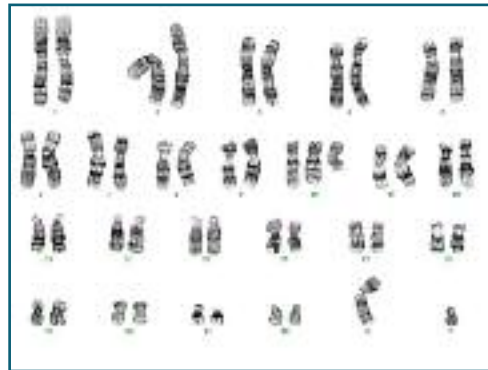

**FIGURE 3.** Choroid plexus cyst.

detected on a male fetus: hypoplastic nasal bone, nuchal edema, lemon-shaped skull, small cerebellum, bilateral choroid plexus cysts, left hydronephrosis and bilateral clubfoot (shown in Figure 1-4).

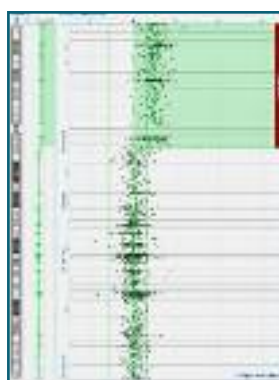


**FIGURE 5.** Isodicentric chromosome 10p.



**FIGURE 6.** Fetal karyotype.

Parental information on the dismal fetal prognosis was given and amniocentesis was performed for cytogenetic study. Fetal karyotype revealed the existence of two distinct cell lines: a line with a supernumerary isodicentric chromosome composed of two short arms of chromosome 10 (29% of cells) (shown in Figure 5); and another line with a normal chromosomal constitution.



**FIGURE 7.** Fetal microarray-CGH.

This meant a mosaic partial tetrasomy of chromosome 10 (47,XY,+idic(10)(q11.2)[11]/46,XY[27]) (shown in Figure 6). The concomitant microarray-CGH detected the existence of a 47Mb duplication of the entire short arm and part of the long arm of chromosome 10, including the centromere (region 10p15.3q11.22) spanning several genes (shown in Figure 7). This copy number variation is considered clinically pathogenic.

After the acknowledgement of fetal chromosomal disorder, parents requested termination of pregnancy, which was accepted by the hospital's technical committee. Medical termination of pregnancy was performed at 22 weeks + 6 days with expulsion of a fetus weighing 526 g. Fetal autopsy and pathology study of the placenta were performed. Autopsy revealed a male fetus with growth and development consistent with 22-23 weeks of gestational age and dysmorphic features such as: flat nasal base, bilateral clubfoot, subcapsular hepatic hematoma on the right lobe and microvesicular steatosis, and transverse cerebellar diameter less than percentile 10. Macroscopic and pathology examination of the placenta were normal.

Parental genetic counselling was undertaken, and karyotype study of the parents was performed. It demonstrated a normal chromosomal constitution on both parents, without mosaicisms, thus indicating that the reported fetal chromosomal abnormality had a *de novo* origin.

## DISCUSSION

Only one case of mosaic tetrasomy 10p similar to the case described here was found in the literature<sup>1</sup>. There

is another report about a prenatal diagnosis of a partial tetrasomy of 10p, but it is considerably smaller in dimensions because it is a supernumerary analphoid chromosome<sup>2</sup>. Our clinical case closely resembles the case report from 2003 in which the second-trimester ultrasound scan also revealed multiple fetal anomalies, including an enlarged posterior fossa, partial/complete agenesis of the cerebellar vermis, cardiac echogenic foci, two umbilical cord cysts and bilateral contractures of the lower limbs. The outcome was also termination of pregnancy<sup>1</sup>. Fetal autopsy confirmed the anomalies detected on the ultrasound scan and the cytogenetic study revealed a partial tetrasomy 10p due to the presence of an isochromosome in mosaicism [47,XX,+i(10p)/46,XX].

Supernumerary marker chromosomes are structurally abnormal chromosomes in addition of the 46 normal chromosomes. In prenatally ascertained cases, 13-30% are associated with abnormal phenotype<sup>3</sup>. Regarding chromosomal abnormalities involving the addition of genetic material to the short arm of chromosome 10, these are rare situations, with less than one hundred cases described<sup>4-7</sup>. There is conflicting data about the existence of a 10p duplication syndrome, given the phenotypic differences found among these individuals, probably related to the amount of duplicated genetic material. The most frequently encountered features are delayed psycho-motor development, hypotonia, abnormal limb position, including clubfoot and arthrogryposis, cleft palate and/or cleft lip and facial dysmorphism such as a protruding forehead, hypertelorism, low-set ears and wide nasal bridge<sup>1,4-8</sup>. In complete trisomy 10p a more severe phenotype is present, associated with severe intellectual and motor disability. The majority of cases are a result of the malsegregation of a familial balanced translocation and the most frequent break point is located at the level of p11 band<sup>9</sup>.

In this case we describe a mosaic tetrasomy of the short arm and part of the long arm of chromosome 10, which includes the centromere and makes it different from the case described previously. The disclosure of these extremely rare diagnosis is important to fetal medicine and counselling.

## ACKNOWLEDGEMENTS

The authors would like to acknowledge Dr. Cláudia Alves and

Dr. Joana Trindade from SynlabHealth Genética Médica, Porto, Portugal, for the for the invaluable help in diagnosis and images contribution.

## REFERENCES

1. Wu YC, Yu MT, Chen LC, Chen CL, Yang ML. Prenatal Diagnosis of Mosaic Tetrasomy 10p Associated With Megacisterna Magna, Echogenic Focus of Left Ventricle, Umbilical Cord Cysts and Distal Arthrogryposis. *Am J Med Genet.* 2003 Mar;117A(3):278-81.
2. Levy B, Papenhausen P, Tepperberg J, Dunn T, Fallet S, Magid M, Kardon N, Hirschhorn K, Warburton P. Prenatal molecular cytogenetic diagnosis of partial tetrasomy 10p due to neocentromere formation in an inversion duplication anaphoid marker chromosome. *Cytogenet Cell Genet* 2000; 91(1-4) :165-70.
3. Liehr T. 2021. Small supernumerary marker chromosomes. [cited 2021 October 6]. Available from: <http://cs-tl.de/DB/CA/sMC/0-Start.html>.
4. Clement SJ, Leppig KA, Jarvik GP, Kapur RP, Norwood TH. Trisomy 10p: Report of an unusual mechanism of formation and critical evaluation of the clinical phenotype. *Am J Med Genet.* 1996 Oct;65(3):197-204.
5. Benzacken B, Lapierre JM, Siffroi JP, Chalvon A, Tachdjian G. Identification and characterization of a de novo partial trisomy 10p by comparative genomic hybridization (CGH). *Clin Genet.* 1998 Oct;54(4):334-40.
6. Berend SA, Shaffer LG, Bejjani BA. Pure trisomy 10p involving an isochromosome 10p. *Clin Genet.* 1999 May;55(5):367-71.
7. Chen Z, Meloni-Ehrig A, Palumbos JC, Guan XY, Carroll KL, Dent KM, et al. Pure trisomy 10p resulting from an extra ring chromosome: Characterization by methods of advanced molecular cytogenetics. *Am J Med Genet.* 2001 Sep;102(4):379-82.
8. Rarechromo.org [Internet]. Unique – Duplications of 10p. [cited 2021 October 6]. Available from: <https://www.rarechromo.org/media/information/Chromosome%2010/10p%20duplications%20FTNW.pdf>.
9. Orpha.net [Internet]. Rare diseases – Trisomy 10p. [cited 2021

October 6]. Available from: [https://www.orpha.net/consor/cgi-bin/OC\\_Exp.php?lng=en&Expert=171929](https://www.orpha.net/consor/cgi-bin/OC_Exp.php?lng=en&Expert=171929).

## AUTHOR CONTRIBUTIONS

Rita Sarabando has contributed with research and interpretation of data, as well as drafting the work, Diogo Cunha contributed with finding and diagnosing the clinical case, interpretation of data and revising the manuscript, Miguel Gonçalves-Rocha has contributed with analyses, counselling, and interpretation of data, as well as drafting the work and revising it, and Alexandra Cadilhe has coordinated the work by guiding the team during the all process, the conception of the study and revising it. All the authors approved the final version and agreed with all parts of it.

## STATEMENT OF ETHICS

Study approval statement: This study was approved by the Ethic Committee for Health from Braga's Hospital (Comissão de Ética para a Saúde do Hospital de Braga – CESHB), approval reference number 141\_2019.

Consent to publish statement: Written informed consent was obtained from the patient for publication of this case report and any accompanying images.

## CONFLICT OF INTEREST STATEMENT

The authors have no conflicts of interest to declare.

## FUNDING SOURCES

This research did not receive any specific grant from funding agencies in the public, commercial, or not-for-profit sectors.

## ENDEREÇO PARA CORRESPONDÊNCIA

Rita Sarabando

E-mail: [ana.ritavidalsarabando@hb.min-saude.pt](mailto:ana.ritavidalsarabando@hb.min-saude.pt)

**RECEBIDO EM:** 03/11/2021

**ACEITE PARA PUBLICAÇÃO:** 13/01/2022