

Post-partum osteomyelitis pubis

Osteomielite púbica puerperal

Mariana Gouvêa d'Almeida¹, Helena Cunha e Carmo¹, João Pedro Pereira¹, Inês Neves Gomes², Cristina Leite²
Hospital Garcia de Orta; Almada; Portugal

Abstract

Osteomyelitis pubis is a rare condition that can occur after vaginal delivery. There are few cases reported, mostly associated with normal vaginal deliveries¹⁻¹¹. Most common pathogen is *Staphylococcus Aureus*, but *P. aeruginosa* and polymicrobial infections evolving faecal flora are also common^{3,12}. Although pelvic trauma has been associated with this rare condition, we present a case of osteomyelitis pubis related to uncomplicated vaginal delivery.

Keywords: Post-partum; Osteomyelitis; pubic symphysis; arthritis, infectious.

Resumo

A osteomielite da sínfise púbica é uma condição rara que pode ocorrer após partos vaginais. Existem alguns casos descritos, maioritariamente associados a partos eutócicos¹⁻¹¹. O microrganismo mais frequentemente associado a esta patologia é o *Staphylococcus Aureus*, mas *P. aeruginosa* e infeções polimicrobianas que incluem flora fecal também são causas comuns^{3,12}. Apesar de o trauma pélvico ser um fator de risco importante, neste trabalho apresentamos um caso de osteomielite puerperal após um parto eutócico sem complicações.

Palavras-chave: Osteomielite; Puerpério; Sínfise púbica; Infecção; Artrite.

INTRODUCTION

Osteomyelitis pubis is a rare condition that can occur after vaginal delivery and is associated with destruction of the bone and, frequently, the joint¹. Obstetric injuries and abortion are known risk factors for this condition, as they can predispose to bacteremia and hematogenous infection of the pubic symphysis². The most common pathogens involved are *Staphylococcus Aureus* and *Pseudomonas Aeruginosa*³.

The most common symptoms are pubic pain, painful gait and hip movements and fever that usually be-

gin in the early post-partum period. Those, associated with inflammatory changes in laboratory and imaging exams plus positive blood cultures support the diagnosis⁴.

On this report we present a rare case of osteomyelitis pubis following an uncomplicated vaginal delivery. The authors required prior approval by the Ethics Committee of Hospital Garcia de Orta and requested informed consent from the respective patient.

CASE PRESENTATION

A 24-year-old primipara was admitted to the hospital at 40 weeks of gestation with active labor. She had no pathological personal history and had an uncomplicated

1. Resident in Gynecology and Obstetrics, H. Garcia de Orta, Almada, Portugal.

2. Attending in Gynecology and Obstetrics, H. Garcia de Orta, Almada, Portugal.

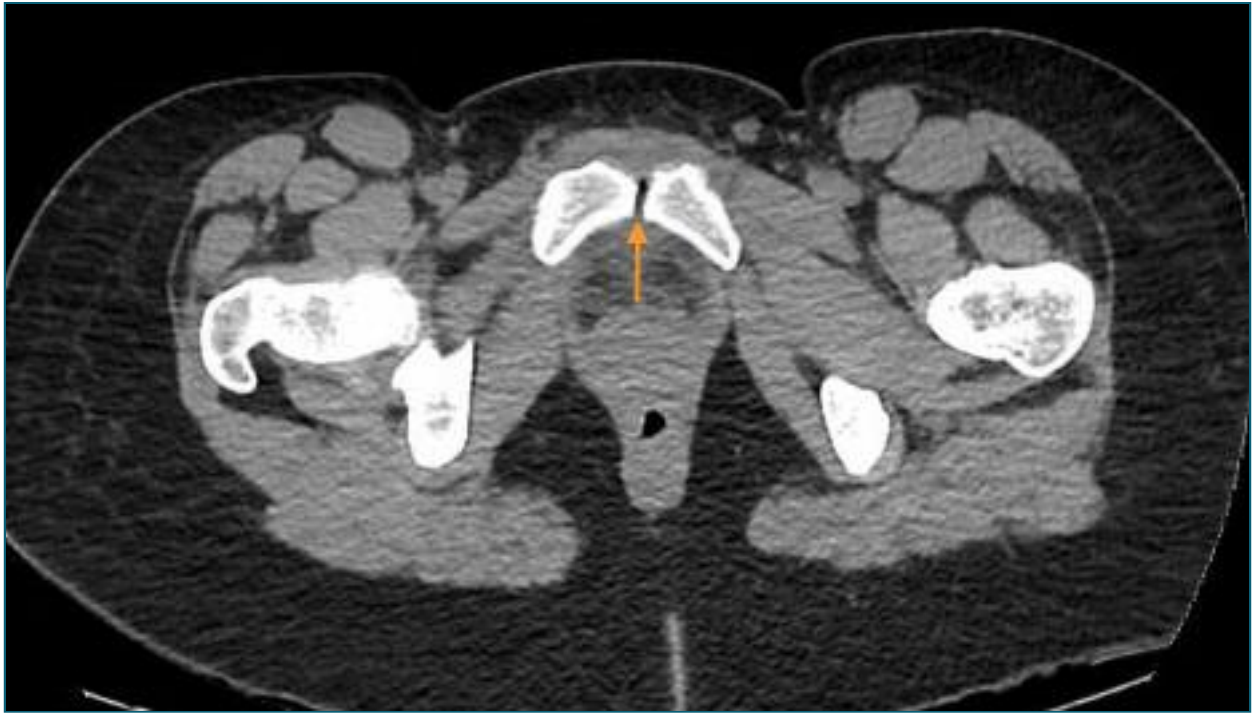

FIGURE 1. Pelvic CT scan. CT scan demonstrating intra-articular air and high density of soft tissues.

pregnancy with a negative swab for Group B Streptococcus at 36 weeks. After six hours of labor without complications, she had a normal delivery of a healthy newborn male with 2500 g, without perineal tears. Two days after the delivery she was discharged denying any symptoms.

However, on the day after, she presented to the emergency room with acute pain in pubic symphysis with irradiation to the groin and hip, which prevented her to stand or walk. On physical exam, she had low grade fever (38,4°C), tenderness on lower abdomen and unremarkable gynecological observation. Blood tests revealed elevated C-reactive protein (CRP) (15 mg/dL) and sedimentation rate (102 sec), even though normal white blood cells count. Pelvic ultrasound was normal, as well as the pelvic x-ray that didn't show any abnormal widening of the pubic symphysis.

At this time, a puerperal endometritis was suspected so blood cultures were performed, and intravenous Clindamycin (900 mg every 8 hours) plus Gentamicin (5 mg/kg/day) were started. Although fever remission, high CRP and pain persisted, and it was now more located to the pubic bone with irradiation to the right

hip and any active or passive movement of the right hip evoked intense pain (specially with flexion and abduction).

For this reason, a computed tomography (CT) was performed and showed pre-pubic soft tissues higher density and intra-articular air in the symphysis pubis (Figure 1), which led to suspicion of an osteitis. A magnetic resonance imaging (MRI) confirmed the diagnosis by showing hyperintense T2 signal and cortical irregularities on the articular surface associated with few intra-articular fluid and densifications of the soft tissues (Figures 2 and 3). At the same time, blood cultures were positive for *Streptococcus Anginosus* and a puerperal osteomyelitis pubis was assumed. Antibiotic therapy was changed to intravenous benzylpenicillin (24 million Units per day), according to the antibiogram. Considering the high diagnostic certainty, based on clinical and imagological features, and technical difficulties, an aspirative biopsy was not performed. In consideration to *Streptococcus Anginosus* found on blood cultures, the patient was submitted to an echocardiogram that excluded any sign of endocarditis.

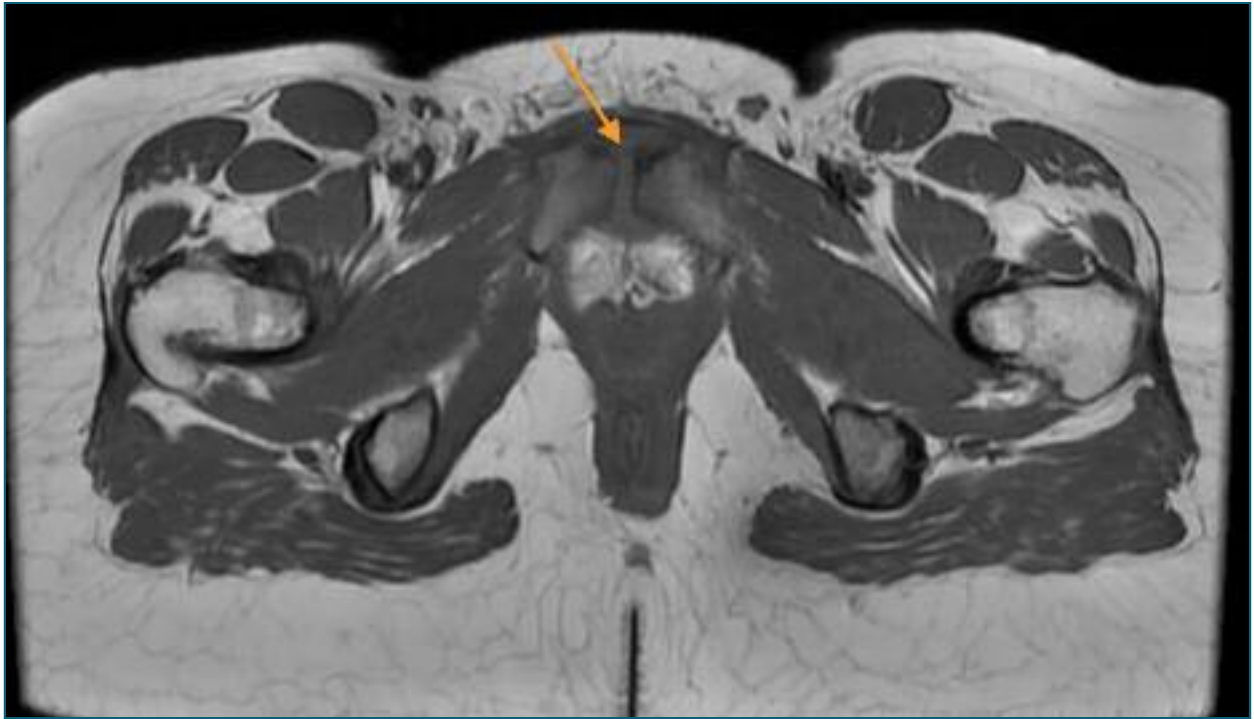


FIGURE 2. Pelvic MRI (axial plane) – MRI showing hyperintense T2 signal and cortical irregularities on the articular surface and densifications of the soft tissues.

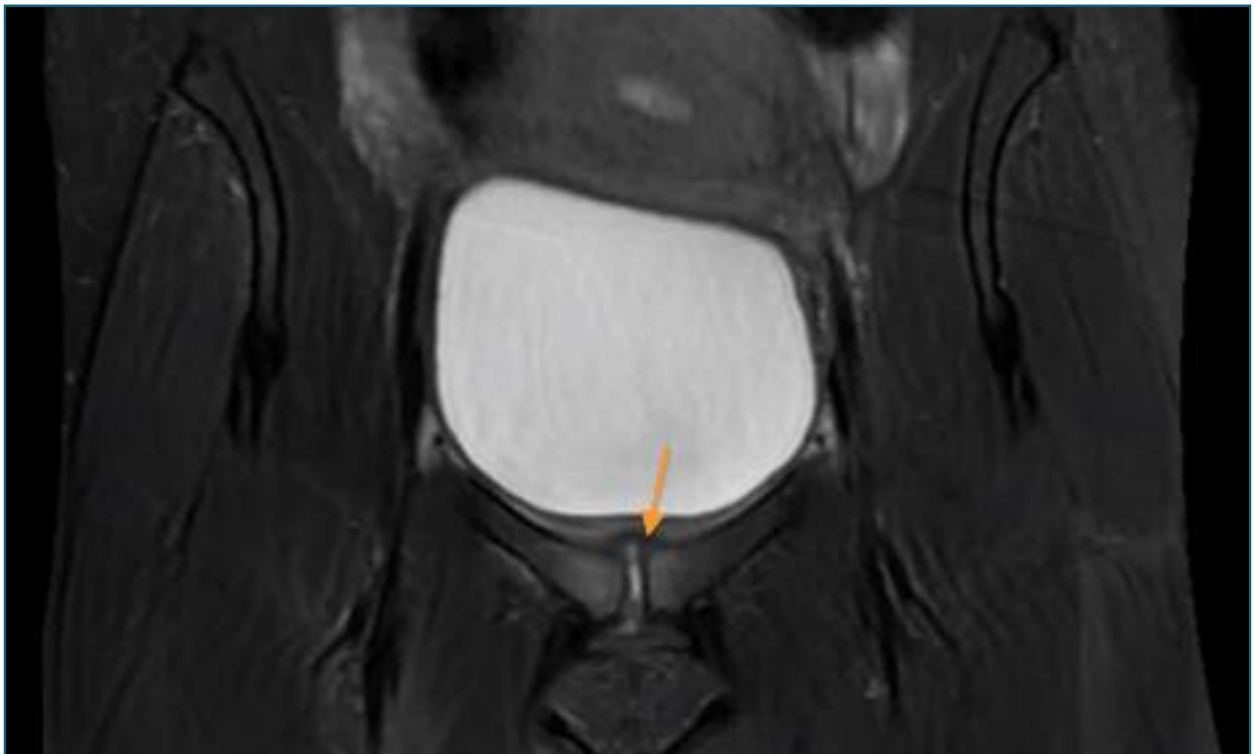


FIGURE 3. Pelvic MRI (coronal plane) – MRI showing hyperintense T2 signal and cortical irregularities on the articular surface and densifications of the soft tissues.

The patient improved few days after the new treatment and was discharged 1 week later. She continued intravenous treatment in a home hospitalization regimen for 4 weeks and for more 2 weeks with oral amoxicillin (1 g every 8 hours). In total, she completed 6 weeks of treatment until normal sedimentation rate was verified. Clinical evolution was good with remission of pain and one month after the end of treatment she had no recurrences or sequelae.

DISCUSSION

Osteomyelitis pubis is a rare condition with a post-partum incidence of 0,01%¹. There are few cases reported, mostly associated with normal vaginal deliveries¹⁻¹¹. Bacteremia was reported in 73% of cases of osteomyelitis pubis and most common pathogen is *Staphylococcus Aureus*, but *P. aeruginosa* and polymicrobial infections evolving fecal flora are also common^{3,12}.

Urologic surgery, intra venous drug use, abortions and obstetric injuries are known risk factors². In the largest cohort study of puerperal septic symphysitis, done in a tertiary hospital in Sweden, primiparity and vaginal instrumental delivery were recognized as risk factors for this condition, as those are associated to more frequent and serious perineal tears¹.

The diagnosis is difficult as it can be confounded with pubic osteitis, a sterile inflammatory and self-limiting condition, or with other more frequent post-partum complications associated with pelvic pain, such as endometritis. A normal gynecological examination and ultrasound, associated with pelvic pain that worsens with movement plus high inflammatory markers and positive blood cultures should raise the suspicion of pubic osteomyelitis⁴. In some cases, fever may not be present and there may be a long period between the precipitating event and the onset of symptoms. A normal pelvic radiograph does not exclude the diagnosis, as the most sensitive imaging exam is MRI showing mostly bony destructions and fluid within the symphysis².

Prompt initiation of antibiotic treatment is crucial for favorable clinical evolution. The choice of antibiotics should be preferably guided by culture of bone biopsy or pus obtained by percutaneous aspiration. When

microbiology exams are not available, empiric antibiotics should cover *Staphylococcus*, gram-negative bacilli, and anaerobes. A rational initial regimen must include vancomycin and a third-generation cephalosporin plus metronidazole. Antibiotic therapy must be continued for at least 4 to 6 weeks and until erythrocyte sedimentation rate is normalized^{13,14}. Surgical debridement or curettage is indicated in severe complications, such as bone necrosis, or symptoms not responding to antibiotic therapy^{5-8,14}. In all cases reported the outcome was excellent after antibiotherapy was started, with no reports of long-term complications.

In conclusion, although pelvic trauma has been associated with osteomyelitis pubis, we present a case of osteomyelitis pubis related to uncomplicated vaginal delivery following a labor with normal progression. This condition is easily mistaken with more common puerperal complications, such as pubic osteitis or other pelvic inflammatory diseases. Fever, normal gynecologic examination, and location of pain should raise clinical suspicion. Clinicians must be aware of this diagnosis since pelvic surgery and labor are important risk factors. Prompt initiation of treatment is crucial for favorable clinical evolution.

REFERENCES

1. Elden H, Olsen MF, Hussein NF, Axelsson LW, Sengpiel V, Ullman M. Postpartum septic symphysitis, a rare condition with possible long-term consequences: a cohort study with long-term follow-up. *BMC Pregnancy Childbirth*. 2021; 16:776. doi: 10.1186/s12884-021-04023-w.
2. Ross JJ, Hu LT. Septic arthritis of the pubic symphysis: review of 100 cases. *Medicine Baltimore*. 2003; 82:340-5. doi: 10.1097/01.md.0000091180.93122.1c.
3. Cosma S, Borella F, Carosso A, Ingala A, Fassio F, Robba T. Osteomyelitis of the pubic symphysis caused by methicillin-resistant *Staphylococcus aureus* after vaginal delivery: a case report and literature review. *BMC Infect Dis*. 2019;19:952. doi: 10.1186/s12879-019-4595-x
4. Lawford AM, Scott K, Lust K. A case of massive vulvar oedema due to septic pubic symphysitis complicating pregnancy. *Australian and New Zealand Journal of Obstetrics and Gynaecology*. 2020;50:576-577. doi:10.1111/j.1479-828X.2010.01227.x
5. Eskridge C, Longo S, Kwark J, Robichaux A, Begneaud W. Osteomyelitis pubis occurring after spontaneous vaginal delivery: a case presentation. *J Perinatol*. 1997;17:321-4.
6. Lovisetti G, Sala F, Battaini A, Lovisetti L, Guicciardi E. Osteomyelitis of the pubic symphysis, abscess and late disjunction after delivery. A case report. *Chir Organi Mov*. 2000;85:85-8.

7. Gamble K, Dardarian TS, Finstein J, Fox E, Sehdev H, Randall TC. Osteomyelitis of the pubic symphysis in pregnancy. *Obstet Gynecol.* 2006; 107:477-81. doi: 10.1097/01.AOG.0000199146.42113.0b

8. Dunk RA, Langhoff-Roos J. Osteomyelitis of the pubic symphysis after spontaneous vaginal delivery. *BMJ Case Rep.* 2010; 12:0120102610. doi: 10.1136/bcr.01.2010.2610.R1

9. Kehila M, Majdoub M, Zegha D, Khedher SB, Cheour E, Mahjoub S. La symphysite pubienne du post-partum: un diagnostic difficile. *Pan Afr Med J.* 2013;16:14. doi: 10.11604/pamj.2013.16.14.3242

10. Hocedez C, Pelissier A, Mosbah R, Raimond E, Gabriel R, Graesslin O. Arthrite septique de la symphyse pubienne au cours de la grossesse. *Gynecol Obstet Fertil.* 2015;43:472-3. doi: 10.1016/j.gyobfe.2015.03.014

11. Froberg L, Eckardt H. Osteomyelitis of the pubic symphysis-a case report. *J Obstet Gynaecol.* 2015;35:862-3. doi: 10.3109/01443615.2015.1017561

12. Yax J, Cheng D. Osteomyelitis pubis: a rare and elusive diagnosis. *West J Emerg Med.* 2014;15:880-2. doi: 10.5811/westjem.2014.8.13401

13. Choi H, McCartney M, Best TM. Treatment of osteitis pubis and osteomyelitis of the pubic symphysis in athletes: a systematic review. *Br J Sports Med.* 2011; 45:57-64. doi: 10.1136/bjsm.2008.050989

14. Pauli S, Willemsen P, Declercq K, Chappel R, Vanderveken M. Osteomyelitis pubis versus osteitis pubis: a case presentation and review of the literature. *Br J Sports Med.* 2002;36:71-3. doi: 10.1136/bjsm.36.1.71

AUTHORS' CONTRIBUTIONS

Mariana G. d'Almeida; Helena Cunha e Carmo and Cristina Leite: Contributed to the diagnosis of the clinical case, interpretation of data, critical review and final approval of the submitted version. Inês Neves Gomes; João Pedro Pereira: Contributed to the revision of literature and critical review of the article.

CONFLICT OF INTEREST

The authors declare that there is no conflict of interest.

CORRESPONDENCE TO:

Mariana Gouvêa d'Almeida

E-mail: mariana.almeida@hgo.min-saude.pt

<https://orcid.org/0009-0009-1381-887>

RECEIVED: 25/02/2024

ACCEPTED: 07/06/2024