

Images of Interest / Imagens de Interesse

## Ectopic Intrathyroidal Thymus Mimicking a Thyroid Nodule

### *Timo Intratiroideu Ectópico que Mimetiza um Nódulo da Tiroide*

Daniela Barros, Ana Catarina Costa, Fernanda Marta Gomes, Catarina Costa, Vasco Mendes

Department of Radiology, Hospital de Braga,  
Braga, Portugal

#### Address

Daniela Barros  
Serviço de Radiologia  
Hospital de Braga  
Lugar das Sete Fontes  
4710-243 Braga, Portugal  
email: danielabarros93@gmail.com

#### Abstract

Ectopic thymus is a well-known embryological abnormality in children, despite being considered rare. To avoid unnecessary examination or biopsy, radiologists must be aware of this condition, especially in pediatric population. This report describes a pediatric patient with history of recurrent episodes of tonsillitis since 2 years of age. In the context of infectious mononucleosis, a cervical ultrasound was performed, which revealed a relatively hypoechoic lesion in the right lobe of the thyroid gland, similar to normal thymus echogenicity. Thyroid function tests were normal. After 3 years of follow-up, the intrathyroidal nodule maintained the same characteristics, having decreased in size from 12 mm to 8 mm.

#### Keywords

Ectopic thymus; Thymus; Thyroid; Ultrasound.

#### Resumo

O timo ectópico é uma anormalidade embriológica bem conhecida em crianças, apesar de ser considerado raro. Para evitar biópsias desnecessárias, os radiologistas devem estar cientes dessa condição, principalmente na população pediátrica. Este artigo descreve um paciente pediátrico com história de episódios recorrentes de amigdalite desde os 2 anos de idade. No contexto de uma mononucleose infecciosa foi realizada uma ecografia cervical, que revelou uma lesão relativamente hipoeecóica no lobo direito da glândula tireóidea, semelhante à ecogenicidade normal do timo. Os testes de função tireóidea foram normais. Após 3 anos de acompanhamento, o nódulo intratiroideu mantém as características iniciais e diminuiu de tamanho de 12 mm para 8 mm.

#### Palavras-chave

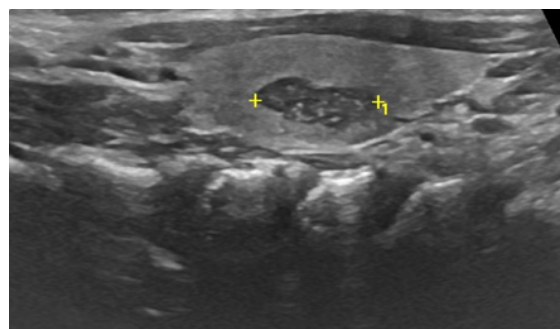
Ecografia; Timo ectópico; Timo; Tiroide.

## Introduction

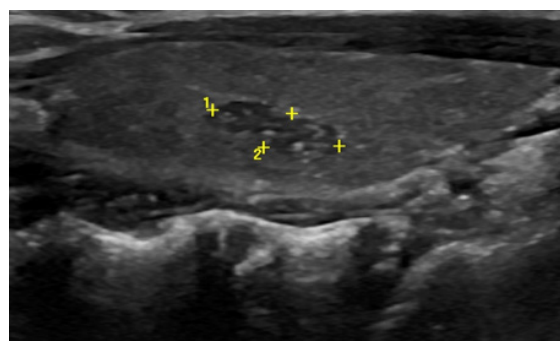
We present a case of a pediatric patient with history of recurrent episodes of tonsillitis since 2 years of age. In the context of infectious mononucleosis, a cervical ultrasound was performed, which revealed a relatively hypoechoic lesion in the right lobe of the thyroid gland, similar to normal thymus echogenicity (Fig. I). Thyroid function tests: TT3 (total triiodothyronine), TT4 (total tetraiodothyronine), FT3 (free triiodothyronine), FT4 (free tetraiodothyronine) and TSH (thyroid-stimulating hormone) were normal. After 3 years of follow-up, the intrathyroidal nodule maintained the same characteristics, having decreased in size from 12 mm to 8 mm (Fig. II). Decision of conservative management with strict monitoring until involution was taken, along with parents' consent.

## Role of ultrasound in diagnosis and follow up of the ectopic thymus

As ultrasound is of common use nowadays, the number of incidental lesions found is increasingly high, including simple cysts or hypoechoic nodules, such as ectopic thymus. Ectopic thymus is a well-known embryological abnormality in children, despite being considered rare. It is most frequently found in the cervical area or mediastinum, yet rarely in the pericardium, hilar area, chest wall or axilla. Ectopic intrathyroidal thymic tissue is also rare.<sup>1</sup>



**Figure I** – Ultrasound showing a relatively hypoechoic 12mm lesion in the right lobe of the thyroid gland, with sharp margins and multiple echogenic foci, similar to thymus tissue.



**Figure II** – Ultrasound after 3 year follow up, showing the intra-thyroidal nodule with the same characteristics, having decreased in size, from 12 mm to 8 mm.

Normal thymus tissue, located in the superior and anterior compartments of the mediastinum, develops from the endoderm of the third and fourth pharyngeal pouches. Thymic parenchyma in children has a characteristic ultrasound appearance, with fusiform shape, well-defined margins and echogenicity between the thyroid gland and the surrounding muscle. Furthermore, it has multiple echogenic foci, portraying a “starry sky” appearance. This distinctive feature is created by overlapped fat and lymphoid tissue.<sup>2</sup> So, if an intrathyroidal lesion has sharp margins and echotexture similar to the thymus, with no abnormal echogenicities in the surrounding thyroid area,

as well as no abnormal lymph nodes, it requires no further action. Only sonographic follow-up is advised, since thymic tissue may automatically degrade and contract. However, if the diagnosis is uncertain, based on sonographic features, or if the mass has suspicious characteristics, further investigation, including ultrasound-guided fine-needle aspiration or additional imaging should be performed.<sup>3</sup> In conclusion, it is important to identify and to be aware of thymic rests and their normal sonographic appearance, so that they won't be confused with other neoplastic thyroid masses, therefore avoiding unnecessary anxiety and intervention, especially in the pediatric population.

**Received / Recebido** 31/12/2019

**Acceptance / Aceite** 10/01/2020

#### **Ethical disclosures / Divulgações Éticas**

*Conflicts of interest:* The authors have no conflicts of interest to declare.

*Conflitos de interesse:* Os autores declaram não possuir conflitos de interesse.

*Financing Support:* This work has not received any contribution, grant or scholarship.

*Suporte financeiro:* O presente trabalho não foi suportado por nenhum subsídio ou bolsa.

*Confidentiality of data:* The authors declare that they have followed the protocols of their work center on the publication of data from patients.

*Confidencialidade dos dados:* Os autores declaram ter seguido os protocolos do seu centro de trabalho acerca da publicação dos dados de doentes.

*Protection of human and animal subjects:* The authors declare that the procedures followed were in accordance with the regulations of the relevant clinical research ethics committee and with those of the Code of Ethics of the World Medical Association (Declaration of Helsinki).

*Proteção de pessoas e animais:* Os autores declaram que os procedimentos seguidos estavam de acordo com os regulamentos estabelecidos pelos responsáveis da Comissão de Investigação Clínica e Ética e de acordo com a Declaração de Helsínquia da Associação Médica Mundial.

#### **References**

1. Huang Y, Zheng S, Xiao X. Ectopic intrathyroidal thymus in children: two case reports and review of the literature. *J Ped Surg Case Reports*. 2013;1:386-90.
2. Kim HG, Kim MJ, Lee MJ. Sonographic appearance of intrathyroid ectopic thymus in children. *J Clin Ultrasound*. 2012;40:266-71.
3. Megremis S, Stiakaki E, Tritou I, et al. Ectopic intrathyroidal thymus misdiagnosed as a thyroid nodule: sonographic appearance. *J Clin Ultrasound*. 2008;36:443-7.