

## ARP Case Report n° 22: What is your diagnosis?

### *Caso Clínico ARP n° 22: Qual o seu diagnóstico?*

Daniela Condesso, Henrique Rodrigues, João Abrantes, João C. Costa

JCC Diagnóstico por Imagem, Hospital Particular Viana do Castelo, Portugal

### Case Presentation

A 78 years old male patient with progressive PSA elevation (currently 14.2 ng/ml). Previous ultrasound guided biopsy with negative results. Referred to JCC - Hospital Particular

de Viana do Castelo to perform a prostate MRI scan and subsequent MRI guided biopsy (in bore system). We present T2 weighted image, Diffusion weighted image—b-value 1600, ADC map and MRI guided biopsy (in bore system).

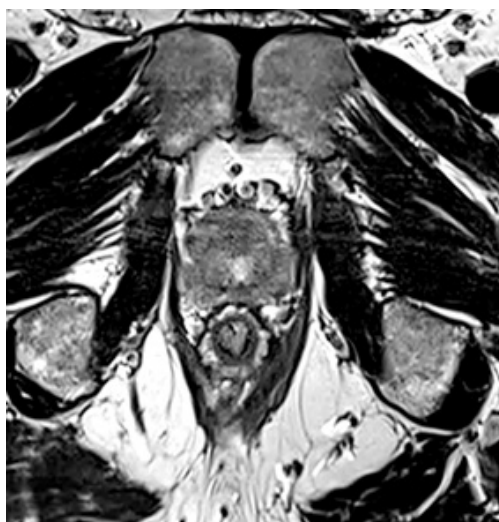

Figure 1

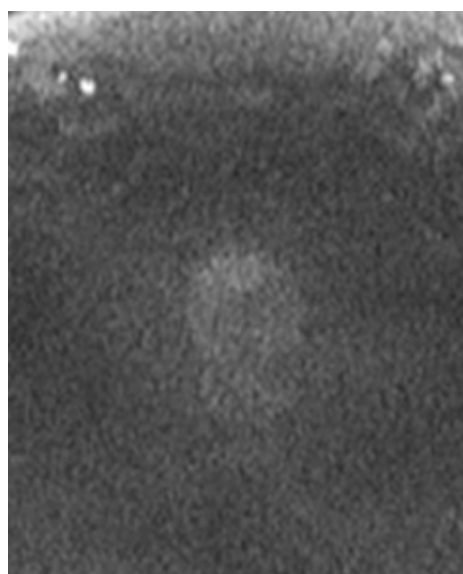


Figure 2

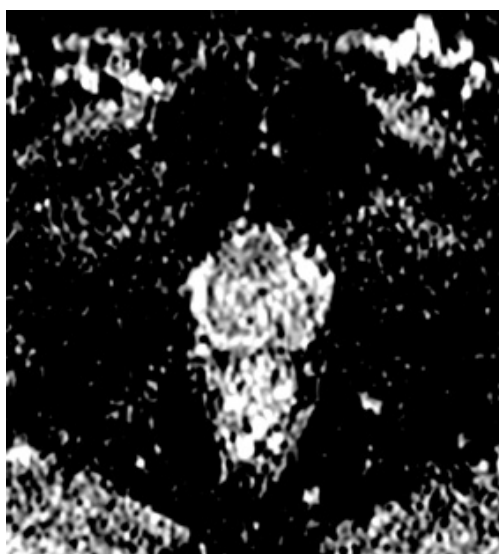

Figure 3

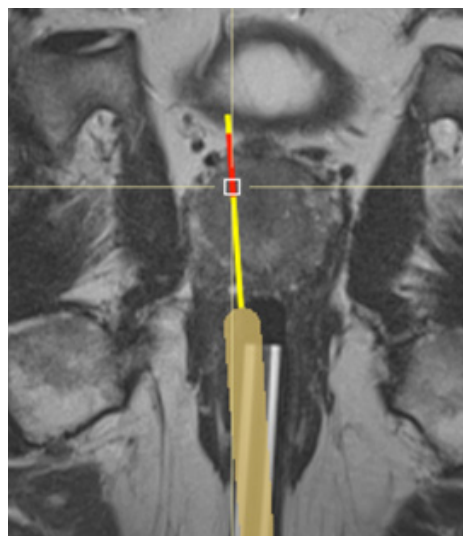


Figure 4

Send your answer containing the diagnosis (s) to the email address [actarp.on@gmail.com](mailto:actarp.on@gmail.com).  
The names of the authors of the correct answers will be published in the next issue of the ARP in the case solution.