

ARP Case Report n° 27: What is your diagnosis?

Caso Clínico ARP n° 27: Qual o seu diagnóstico?

Sara Peixoto¹, Maria Luísa Lobo¹, João Leitão^{1,2}

¹Serviço de Imagiologia Geral, Hospital de Santa Maria, Centro Hospitalar Universitário Lisboa Norte, EPE. Lisboa, Portugal

²Director de Serviço

Case Presentation

A 12 month-old male infant was referred to the paediatric pulmonary unit of our tertiary hospital for further investigation.

At the age of 4 months, he had been referred by his family doctor to a secondary hospital because of respiratory distress since the first month of life and failure to thrive. At that time, clinical observation revealed an increase in the anteroposterior diameter of the chest, elevated respiratory rate, and subcostal and supraclavicular retractions. On auscultation, crackles

were heard in both lung bases without wheezing. Peripheral blood oxygen saturation was 92% in room air. Laboratory investigations, which included alpha-1 antitrypsin levels and sweat test, were within in the normal range. Chest x-ray (not shown) revealed bilateral lung hyperinflation and no further remarks. He was treated with supplemental oxygen and inhaled corticoids with mild clinical improvement.

A high-resolution chest computed tomography (CT) was performed at our department (figure 1). What is your diagnosis?

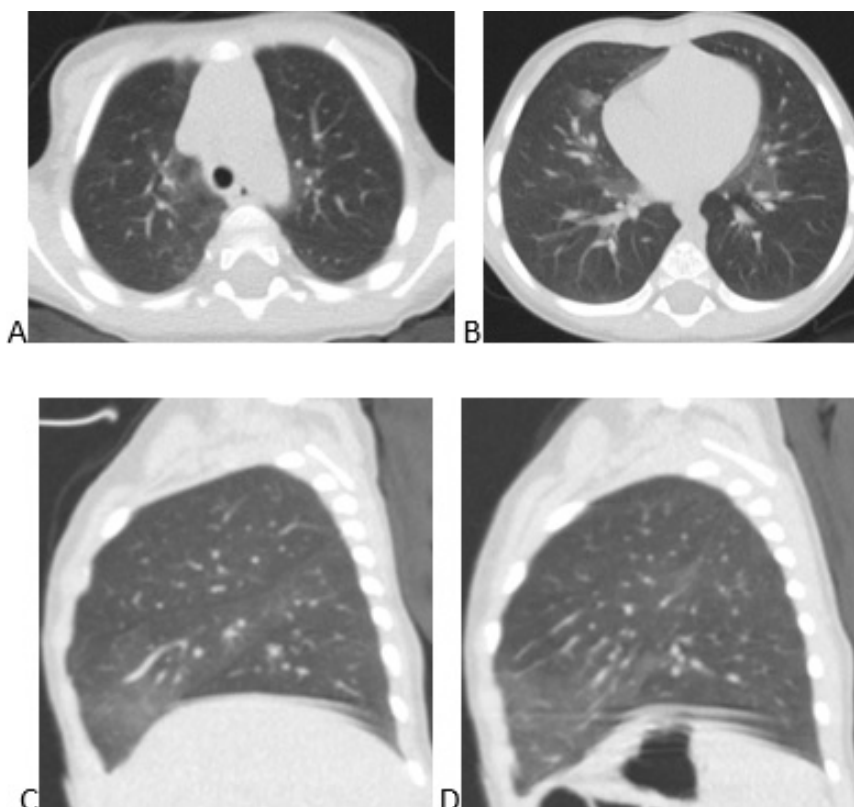


Figure 1 – Chest CT axial images, at the level of aortic arch (A) and at the level of the heart (B), and sagittal reformations, of the right lung (C) and of the left lung (D)

Send your answer containing the diagnosis (s) to the email address actarp.on@gmail.com.
The names of the authors of the correct answers will be published in the next issue of the ARP in the case solution.