

ENDOSCOPIC SPOT

Whipple's disease and giardiasis: An uncommon association

Doença de whipple e giardíase: uma associação incomum

Frederico Ferreira*, Helder Cardoso, Andreia Albuquerque, Fernando Magro, Guilherme Macedo

Gastroenterology Department, Hospital S. João and Faculty of Medicine, Porto, Portugal

Received 8 July 2011; accepted 10 January 2012

Available online 29 June 2012

Whipple's disease is a rare systemic disorder with unspecific signs and symptoms, that remains a diagnostic challenge.¹

A 61-year-old female was referred to the gastroenterology department due to abdominal pain, diarrhea and arthralgias. The investigation revealed anemia, hypoalbuminemia and inflammatory markers' elevation, with normal immunological investigation. Fecal smears were positive for *Giardia lamblia*, but after effective treatment she remained symptomatic. Colonoscopy was normal and the upper endoscopy revealed edematous mucosa on the second duodenal portion. Histopathology of the duodenal biopsy revealed macrophages infiltration, inconclusive for periodic acid-schiff and negative for Ziehl–Nielsen stains. However, polymerase chain reaction (PCR) for *Tropheryma whipplei* was positive. A capsule endoscopy revealed areas of whitish reticular pattern and dilated villi with lymphangiectasias in the jejunum and ileum (Figs. 1 and 2), changes suggestive of Whipple's disease. Antibiotherapy with ceftriaxone followed by trimethoprim-sulfamethoxazole was done. After eight months of treatment, the patient was asymptomatic; anterograde and retrograde single-balloon enteroscopy were performed revealing resolution of the lesions, and the biopsies had negative histological findings and PCR for *Tropheryma whipplei*.

There are few reports regarding the appearance of the small bowel in Whipple's disease as viewed by capsule endoscopy, but a pattern of mucosal involvement with patchy white-yellowish punctate miliaria is considered

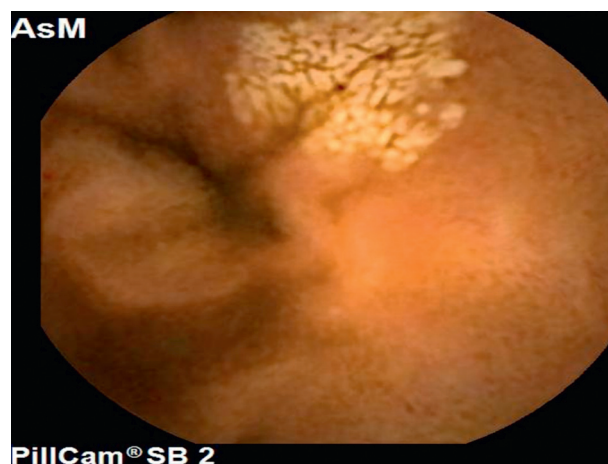


Figure 1 Jejunal mucosa showing a whitish reticular pattern, suggestive of dilated lymphatic vessels.

suggestive.^{2,3} However, in the present case these changes occurred throughout the jejunum and ileum and were absent in the duodenum. The areas readily accessible for biopsy were therefore scarcely affected, which explains the absence of typical histological changes and reinforces the importance PCR and capsule endoscopy for diagnosis.

In conclusion, this case is original for the presence of lesions in the jejunum and ileum with sparing of the duodenum, rendering diagnosis even more challenging. This patient had also simultaneous infection with *Giardia lamblia* which is an uncommon association, whose etiology is still a matter of debate.^{4,5}

* Corresponding author.

E-mail address: fredericoferreira2@hotmail.com (F. Ferreira).

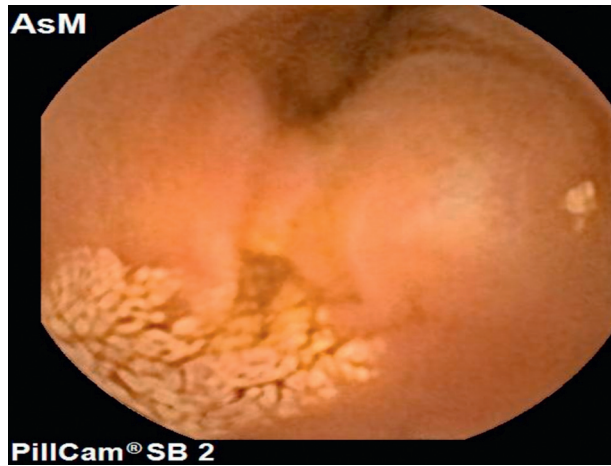


Figure 2 Patchy white reticular pattern in the mucosa of the ileum.

Conflicts of interest

The authors have no conflicts of interest to declare.

References

1. Fenollar F, Puechal X, Raoult D. Whipple's disease. *New England Journal of Medicine*. 2007;356:55–66.
2. Fritscher-Ravens A, Swain CP, Von Herbay A. Refractory Whipple's disease with anaemia: first lessons from capsule endoscopy. *Endoscopy*. 2004;36:659–62.
3. Gay G, Roche JF, Delvaux M. Capsule endoscopy, transit time, and Whipple's disease. *Endoscopy*. 2005;37:272–3.
4. Fenollar F, Lepidi H, Gerolami R, et al. Whipple disease associated with giardiasis. *Journal of Infectious Diseases*. 2003;188: 828–34.
5. Fernandez-Urien I, Carretero C, Sola JJ, et al. Refractory Whipple's disease. *Gastrointestinal Endoscopy*. 2007;65: 521–2.