



ENDOSCOPIC SNAPSHOT

A New Method for Distal Repositioning of a Misplaced Esophageal Stent



Rui Silva

Gastroenterology Department, Instituto Português de Oncologia do Porto Francisco Gentil, Porto, Portugal

Received 24 September 2014; accepted 20 October 2014

Several techniques for managing migrated and misplaced self-expanding esophageal metal stents have been described.^{1–5} However, most of these techniques apply only when there is distal stent dislodgment. When there is proximal stent migration or misplacement, and unless there is a lasso at the distal flange, trying to reposition the stent distally through the stenotic tumor can be challenging. Although it may be tried by grasping distal tines with forceps or inflating a dilating balloon within the stent and applying gentle pressure, it seldom results. We herein report an endoscopic approach for an easy and safe reposition of proximal dislodged esophageal metal stents that, as far as we are aware, was never described before.

The stent is removed by grasping the lasso on the proximal end of the stent with an alligator jaw grasping forceps. Outside the patient, the lasso is released and the stent is turned upside down. The endoscope is then introduced through the distal end of the stent until the proximal end, where the lasso is re-grasped by the forceps and pulled back, allowing the upper flange of the stent to collapse over the tip of the endoscope (Fig. 1). The body of the stent is generously lubricated with aqueous jelly and stretched along the endoscope. The patient is reintubated with gently passage of the endoscope and the stent through the pharynx




Figure 1 The endoscope is inserted through the distal end of the stent to the proximal end, with re-grasping of the lasso by the forceps. Pulling the grasping forceps, the upper flange of the stent collapses over the tip of the endoscope.

E-mail address: rsgastro@sapo.pt

<http://dx.doi.org/10.1016/j.jpge.2014.10.004>

2341-4545/© 2014 Sociedade Portuguesa de Gastrenterologia. Published by Elsevier España, S.L.U. This is an open access article under the CC BY-NC-ND license (<http://creativecommons.org/licenses/by-nc-nd/4.0/>).

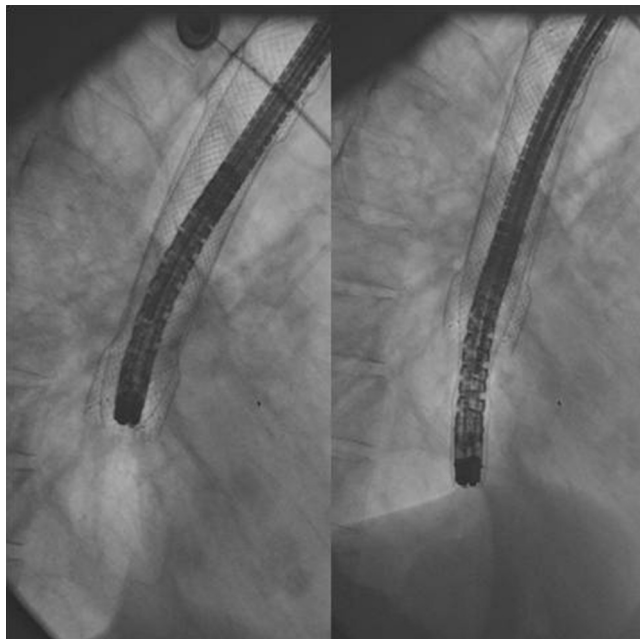


Figure 2 Passage of the endoscope along with the stent through the tumor overgrowth at the distal flange of the previous stent.

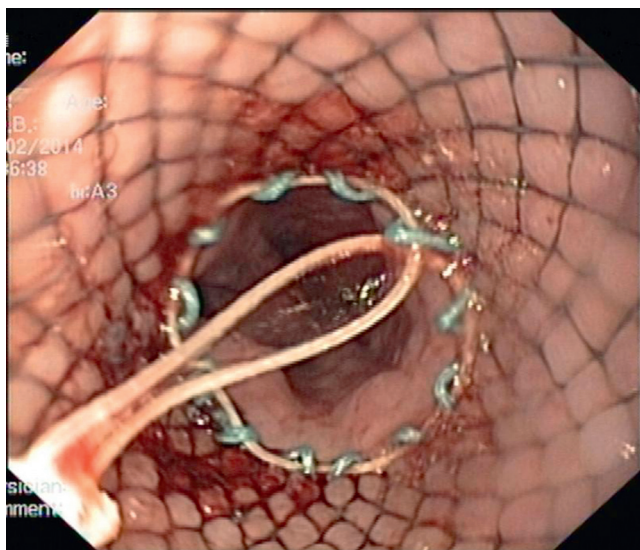


Figure 3 Endoscopic view of the collapsed distal flange of the stent.

and cricopharyngeus into the upper esophagus. Under fluoroscopic guidance and direct visualization, the endoscope is then advanced through the tumor (Figs. 2 and 3). If significant narrowing prevents the safe passage of the endoscope along with the stent, gentle esophageal dilation to 11–13 mm is performed. The lasso is then released and the stent deployed according with the marks previously placed.

We have performed this technique in 3 patients during the last four years, with successful stent repositioning and no complications.

Ethical disclosures

Protection of human and animal subjects. The authors declare that no experiments were performed on humans or animals for this study.

Confidentiality of data. The authors declare that no patient data appear in this article.

Right to privacy and informed consent. The authors declare that no patient data appear in this article.

Conflicts of interest

Consultant for Cook Medical and Boston Scientific Corporation.

References

1. Seitz U, Thonke F, Bohnacker S, Brand B, Jaeckle S, Soehendra N. Endoscopic extraction of a covered esophageal Z-stent with the aid of Endoloops. *Endoscopy*. 1998;30:S91–2.
2. Rajjman I, Marcon NE, Kandel G, Haber GB, Kortan P. Repositioning of an esophageal stent after migration using a snare. *Gastrointest Endosc*. 1994;40:652.
3. Farkas PS, Farkas JD, Koenigs KP. An easier method to remove migrated esophageal Z-stents. *Gastrointest Endosc*. 1999;50:277–9.
4. May A, Gossner L, Feess G, Bauer R, Ell C. Extraction of migrated self-expanding esophageal metal stents. *Gastrointest Endosc*. 1999;49:524–6.
5. Martins B, Sorbello MP, Retes F, Kawaguti FS, Lima MS, Hondo FY, et al. Endoscopic removal of migrated esophageal stent – the “grasper and pusher” method. *Endoscopy*. 2012;44 Suppl. 2. UCTN:E10.