



IMAGES IN GASTROENTEROLOGY AND HEPATOLOGY

Colonic Intussusception Caused by Colonic Lipoma

Invaginação Cólica Causada por Lipoma do Cólon

Filipa Ávila*, José Renato Pereira, Maria Antónia Duarte



Gastroenterology Department, Hospital do Divino Espírito Santo de Ponta Delgada, Ponta Delgada, Portugal

Received 10 January 2016; accepted 3 April 2016

Available online 21 June 2016

KEYWORDS

Colonic Diseases;
Colonic Neoplasms;
Intussusception/etiology;
Lipoma/complications

PALAVRAS-CHAVE

Doenças do Cólon;
Neoplasias do Colón;
Invaginação/etiologia;
Lipoma/complicações

A 41-year-old man, was admitted in the emergency department due to repeated lower abdominal pain, constipation and hematochezia with one month of evolution. His past medical history was irrelevant. The physical examination and laboratory data were normal. The patient denied anorexia, weight loss and fever. A colonoscopy revealed an extensive mass with a regular mucosal surface with ischemia and ulceration at the distal top (Figs. 1 and 2), in the descending colon. This lesion occupied more than 2/3 of the circumference and conditioned lumen stenosis. Biopsies

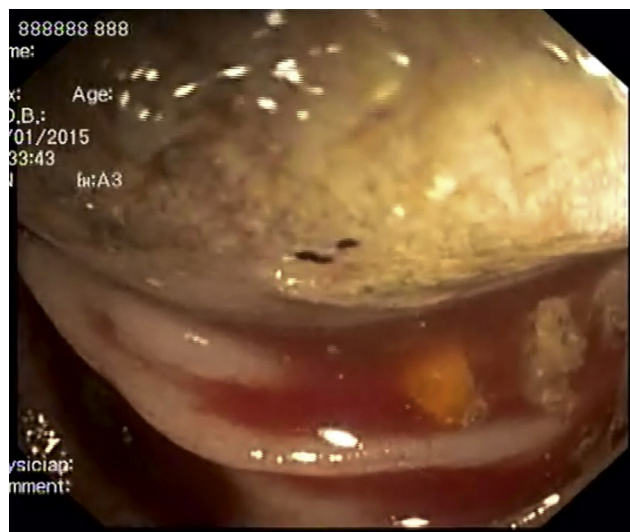

Figure 1 Endoscopic image of an extensive mass with a regular mucosal surface, occupied more than 2/3 of the circumference and conditioned lumen stenosis, in the descending colon.

revealed inflammatory changes. An abdominal and pelvic computed tomography (CT) showed colocolic intussusception (Fig. 3), in the terminal portion of the descending colon, caused by a lipomatous mass with 7 cm × 4 cm larger diameter (Fig. 4). The patient underwent a segmental colon resection by laparoscopy. The histological examination of

* Corresponding author.

E-mail address: filipaavila@gmail.com (F. Ávila).

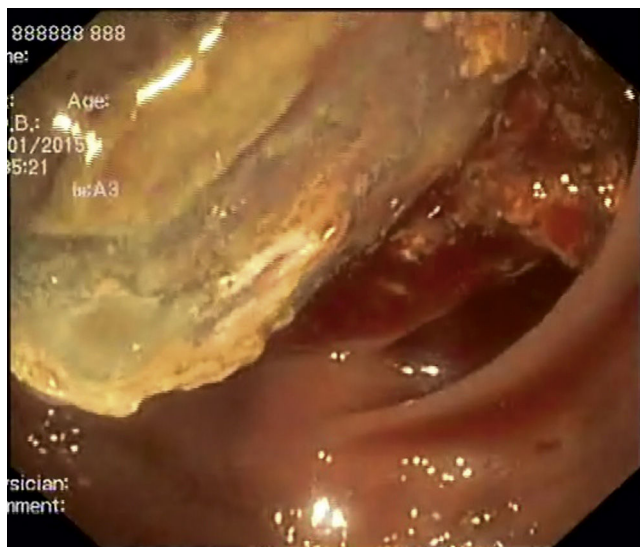


Figure 2 Endoscopic image of a mass with ischemia and ulceration at the distal top, in the descending colon.

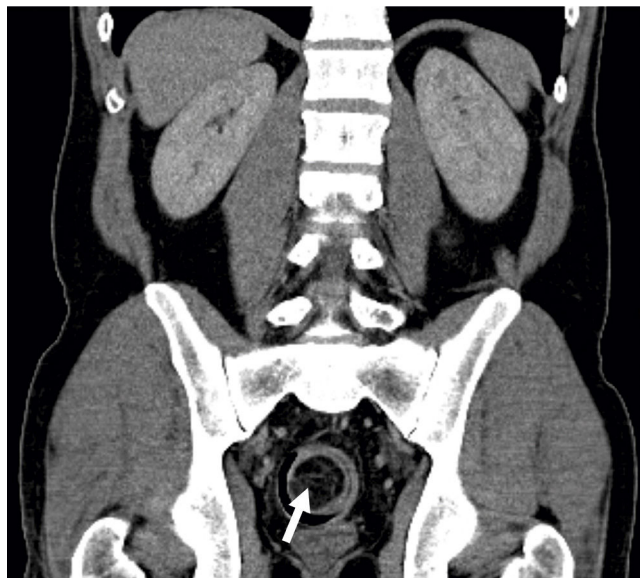


Figure 3 Abdominal CT (coronal view): colocolic intussusception in the terminal portion of the descending colon.

the surgical specimen revealed a partially necrotic submucosal lipoma.

The authors describe this case due to its rarity. Colonic lipoma is a very rare benign tumor, however it is the second most common benign tumor of the colon with an incidence between 0.2 and 4%.¹ In 90% of these cases the origin of the lipoma is confined to the submucosal layer.² It is more frequently found in the right colon by colonoscopy. These lesions are usually asymptomatic and do not require specific treatment. Lipomas larger than 4 cm, are considered giant and are symptomatic in 75% of cases.³ Symptoms are usually abdominal pain, bleeding, colonic obstruction and intussusception. The intussusception is a rare complication that requires a differential diagnosis with a malignant lesion. Literature describes that lipomas larger than 2 cm should be removed due to colonic intussusception risk.⁴

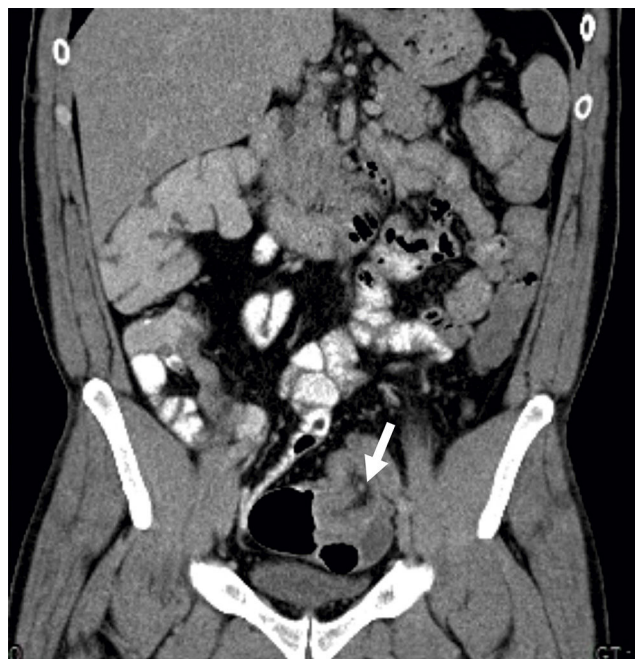

Figure 4 Abdominal CT (coronal view): lipomatous mass with 7 cm x 4 cm larger diameter in the.

The treatment for symptomatic lipomas has typically included surgical resection, but the use of minimally invasive techniques such as endoscopic therapy is increasing.⁴ Thus, various endoscopic procedures, including snare resection, endoscopic submucosal dissection, unroofing, endoloop technique and a combination of the last two, the “grasp-to-retract, ligate, unroof, and let-go” technique have been introduced recently for safe resection.^{4,5} In this case, the patient underwent a surgical resection because he presented with an acute colonic obstruction from intussusception.

Ethical disclosures

Protection of human and animal subjects. The authors declare that no experiments were performed on humans or animals for this study.

Confidentiality of data. The authors declare that no patient data appear in this article.

Right to privacy and informed consent. The authors declare that no patient data appear in this article.

Authorship

Filipa Ávila did the writing of the manuscript. All authors were responsible for the revision of its contents.

Conflicts of interest

The authors have no conflicts of interest to declare.

References

1. Vecchio R, Ferrara M, Mosca F, Ignoto A, Latteri F. Lipomas of the large bowel. *Eur J Surg.* 1996;162:915–9.
2. Michowitz M, Lazebnik N, Noy S, Lazebnik R. Lipoma of the colon. A report of 22 cases. *Am Surg.* 1985;51:449–54.
3. Huh KC, Lee TH, Kim SM, Im EH, Choi YW, Kim BK, et al. Intussuscepted sigmoid colonic lipoma mimicking carcinoma. *Dig Dis Sci.* 2006;51:791–5.
4. Lee JM, Kim JH, Kim M, Kim JH, Lee JB, Lee JH, et al. Endoscopic submucosal dissection of a large colonic lipoma: report of two cases. *World J Gastroenterol.* 2015;21:3127–31.
5. Ponte A, Pinho R, Vale S, Fernandes C, Ribeiro I, Silva J, et al. Resection of a large ileal lipoma exhibiting ball-valve prolapse into the cecum with a grasp-to-retract, ligate, unroof, and let-go technique. *Endoscopy.* 2015;47:E215–6.