

## Colonic Gallstone Ileus: A Rare Case

Cristina Teixeira Ana Luisa Alves Isabelle Cremers

Gastroenterology Department, Centro Hospitalar de Setúbal, Setúbal, Portugal

### Keywords

Cholelithiasis · Colonic gallstone ileus

### Ileus biliar cólico: um caso raro

### Palavras Chave

Colelitíase · Íleus biliar cólico

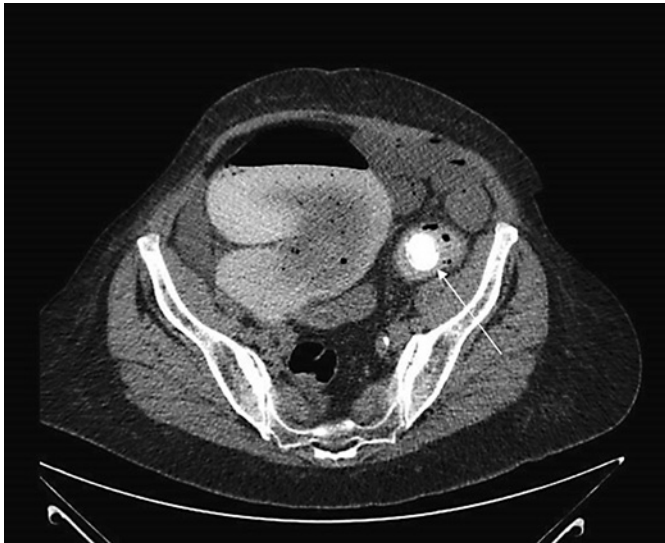
### Case Report

A 72-year-old woman with a history of atrial fibrillation, arterial hypertension, thyroidectomy, and mitral insufficiency presented to the emergency department with nausea, vomiting, and abdominal pain for the last 24 h. At physical examination, the patient had right upper abdominal pain and Murphy's sign. Abdominal ultrasound revealed gallstones, thickened gallbladder wall, and sonographic Murphy's sign. Blood tests showed normal liver tests and inflammatory parameters (INR 2.1). She was admitted for acute cholecystitis. Due to comorbidities, intravenous antibiotherapy was started and cholecystectomy was delayed until cardiac evaluation and anticoagulation correction. On the 6th day of hospitalization, the patient presented abdominal distension, hyperactive bowel sounds, and mild diffuse tenderness. CT scan demon-

strated a thickened gallbladder wall with fistula to the colonic hepatic flexure, and a gallstone of 2.2 cm in the sigmoid colon causing proximal gas distension of the bowel (Fig. 1). Colonoscopy revealed an impacted gallstone at 30 cm from the anal verge and adjacent mucosal ulceration (2 ulcers of 5 mm). Attempted endoscopic removal with snare and basket was unsuccessful (Fig. 2). Due to colonic distension and higher surgical risk associated with the one-stage procedure, the patient underwent enterolithotomy and cholecystectomy was delayed and performed 2 months later, without complications.

### Discussion

Gallstone ileus is responsible for 1–4% of cases of intestinal obstruction and occurs predominantly in females [1]. Biliary-enteric fistulas occur in the setting of inflammation, as acute cholecystitis and gallstones must be at least 2–2.5 cm in diameter to cause obstruction. The most common site of impaction is the terminal ileum and the ileocecal valve. Colonic gallstone ileus occurs in 4% of the cases, mostly at the level of the sigmoid colon [2]. Clinical presentation of gallstone ileus depends on the site of impaction and may include abdominal pain and distension, nausea, vomiting, and constipation. Diagnosis is difficult and in many cases, it is intraoperative. CT of the abdomen

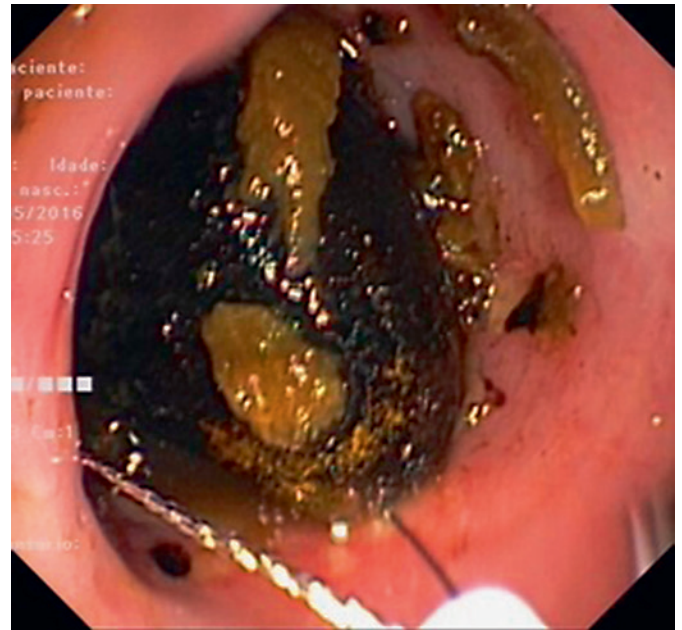


**Fig. 1.** CT scan: gallstone (arrow) in the sigmoid colon causing proximal gas distension of the bowel.

and pelvis remains the gold standard with sensitivity and specificity rates of 3 and 100%, respectively [1]. The classical radiological triad as described by Rigler et al. [3] includes pneumobilia, dilated small bowel, and aberrant gallstone location. Surgery is the mainstay of treatment. Methods of approach include: enterolithotomy alone (with or without a sequential cholecystectomy) or enterolithotomy, cholecystectomy, and fistula repair as a one-stage procedure. The one-stage procedure is related to higher perioperative morbidities and mortality [4]. Endoscopic retrieval of the stone may be attempted but is rarely successful. Other approaches include extracorporeal or electrohydraulic lithotripsy [4].

### Statement of Ethics

This study did not require informed consent nor review/approval by the appropriate ethics committee.



**Fig. 2.** Impacted gallstone in the sigmoid colon: endoscopic removal attempt.

### Disclosure Statement

All authors have read and approved the manuscript and deny conflicts of interest.

### Author Contributions

C.T., A.L.A., and I.C. were involved in the management of the case. The manuscript was prepared by C.T. and was vetted by all.

### References

- 1 Clavien P, Richon J, Burgan S, et al: Gallstone ileus. *Br J Surg* 1990;77:737–742.
- 2 Reisner R, Cohen J: Gallstone ileus: a review of 1,001 reported cases. *Am Surg* 1994;63:441–446.
- 3 Rigler L, Borman C, Noble J: Gallstone obstruction: pathogenesis and roentgen manifestations. *JAMA* 1941;117:1753–1759.
- 4 Nuño-Guzmán CM, Marín-Contreras M, Figueroa-Sánchez M, et al: Gallstone ileus, clinical presentation, diagnostic and treatment approach. *World J Gastrointest Surg* 2016;8:65–67.