

In the article by Canakis and Baron entitled “Therapeutic Endoscopic Ultrasound: Current Indications and Future Perspectives” [GE Port J Gastroenterol. 2023, DOI: 10.1159/000529089], Figure 3 was missing from the original publication. Figure 3 is shown here.

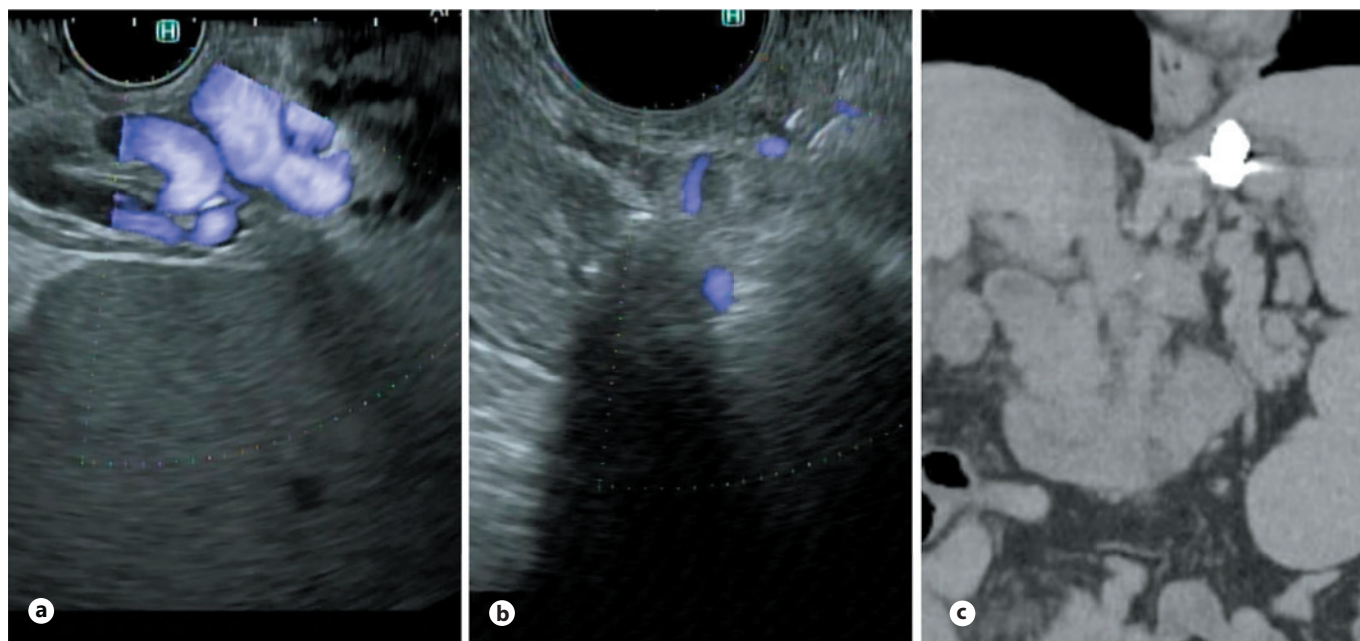


Fig. 3. EUS-guided variceal embolization. **a** Gastric varices as seen by linear echoendoscope. **b** Echo image after placement of coils and glue into gastric varix via a 19G needle. Lack of flow as seen by Doppler. **c** Follow-up coronal CT scan obtained for routine management showing coils in place within the gastric varices.