

Eosinophilic Esophagitis on and off Proton Pump Inhibitor

Vincent Zimmer^{a, b} Kai Emrich^c

^aDepartment of Medicine, Marienhausklinik St. Josef Kohlhof, Neunkirchen, Germany; ^bDepartment of Medicine II, Saarland University Medical Center, Saarland University, Homburg, Germany; ^cInstitute of Pathology Saarbrücken-Rastpfuhl, Saarbrücken, Germany

Keywords

Esophageal stricture · Dysphagia · Diagnostic esophago-gastro-duodenoscopy · Proton pump inhibitor · Eosinophilic esophagitis

Esofagite eosinofílica com e sem inibidor da bomba de prótons

Palavras Chave

Estenose esofágica · Disfagia · Endoscopia diagnóstica · Inibidor da bomba de prótons · Esofagite eosinofílica

Pre-endoscopy empirical PPI usage has become standard in many countries, albeit there are significant concerns in terms of masking relevant endoscopy findings, which may, among others, include eosinophilic esophagitis (EoE), thus clearly calling for a change in practice pattern [1, 2]. A 28-year-old male patient with birch pollen allergy and dysphagia for solids and reflux-like symptoms for several months with incomplete response to proton pump inhibitors (PPIs) was referred for endoscopic stricture treatment due to a presumed

reflux-related stricture. Outside office-based index esophago-gastro-duodenoscopy (EGD), while on empiric standard-dose PPI treatment, indicated a small hiatal hernia along with a discrete short stricture. At the time, biopsies from the distal esophagus remained non-contributory.

The recent EGD indicated questionable linear furrows with minor reduction in submucosal vessel visibility in the proximal esophagus (Fig. 1a). The short distal stricture was well reproduced (Fig. 1b), and a bougienage up to 20 mm using Savary-Gilliard bougies was performed (Fig. 1c; note fully preserved vascular markings in the distal esophagus). Given the lack of relevant mucosal tears after maximal bougienage (Fig. 1d), an additional radial electroincision using an IT knife was conducted (not shown). Esophageal biopsies with an adequate biopsy protocol (> two heights, >6 biopsies) yielded no evidence for potentially underlying EoE. Since the patient only benefitted transiently from the procedure and presented again after only 2 weeks with reflux-like symptoms and dysphagia, ancillary esophageal manometry did not demonstrate dysmotility. The patient consented to withdraw PPI treatment for 2 weeks with alginate bridging, causing

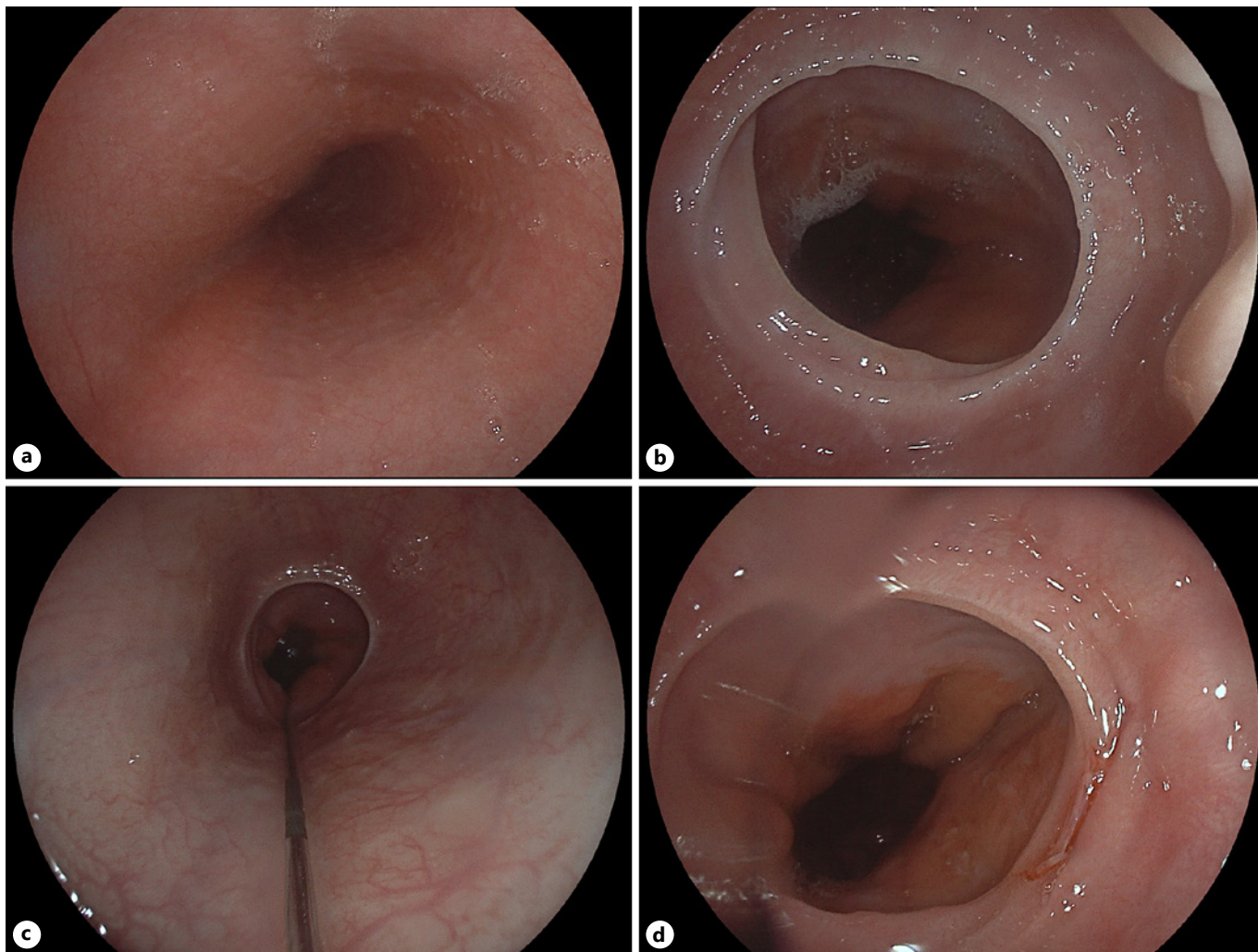


Fig. 1. **a** Discrete linear furrows with moderately reduced vascular markings restricted to the upper third of the esophagus. **b** Short distal esophageal stricture and small hiatal hernia. **c** Guidewire in situ prior to maximum bougienage to 20 mm; note fully preserved submucosal vessels in the distal esophagus. **d** Endoscopy after bougienage to 20 mm with only a minor tear at 4 o'clock.

significant clinical deterioration, i.e. worsening reflux and dysphagia. Repeat EGD provided clear-cut endoscopic EoE evidence with diffuse furrowing, diffuse lack of submucosal vessels reflecting significant edema (Fig. 2a) as well as recurrence of the distal stricture (Fig. 2b). In addition, coarse exudates were noted at the level of linear furrows, which were specifically targeted for histopathology [3, 4] (Fig. 2c – EREFS score 5). Repeat biopsies off PPI confirmed presence of EoE in this patient with a maximum infiltration of >32 /HPF in the proximal esophagus. The patient was successfully treated by 2×1 mg orodispersible budesonide.

Empiric PPI treatment is oftentimes implemented prior to diagnostic EGD in clinical practice [5]. Unlike PPI-responsive EoE, this case of a patient falling behind endoscopic and/or pathology appreciation of EoE, while remaining highly symptomatic, should remind us to critically reconsider such practice, given that not only EoE may become masked. Beyond the need to strictly adhere to biopsy protocol recommendations even in patients without clear endoscopic EoE stigmata, this unique clinical report illustrates the potential divergence between clinical and endoscopic response in EoE.

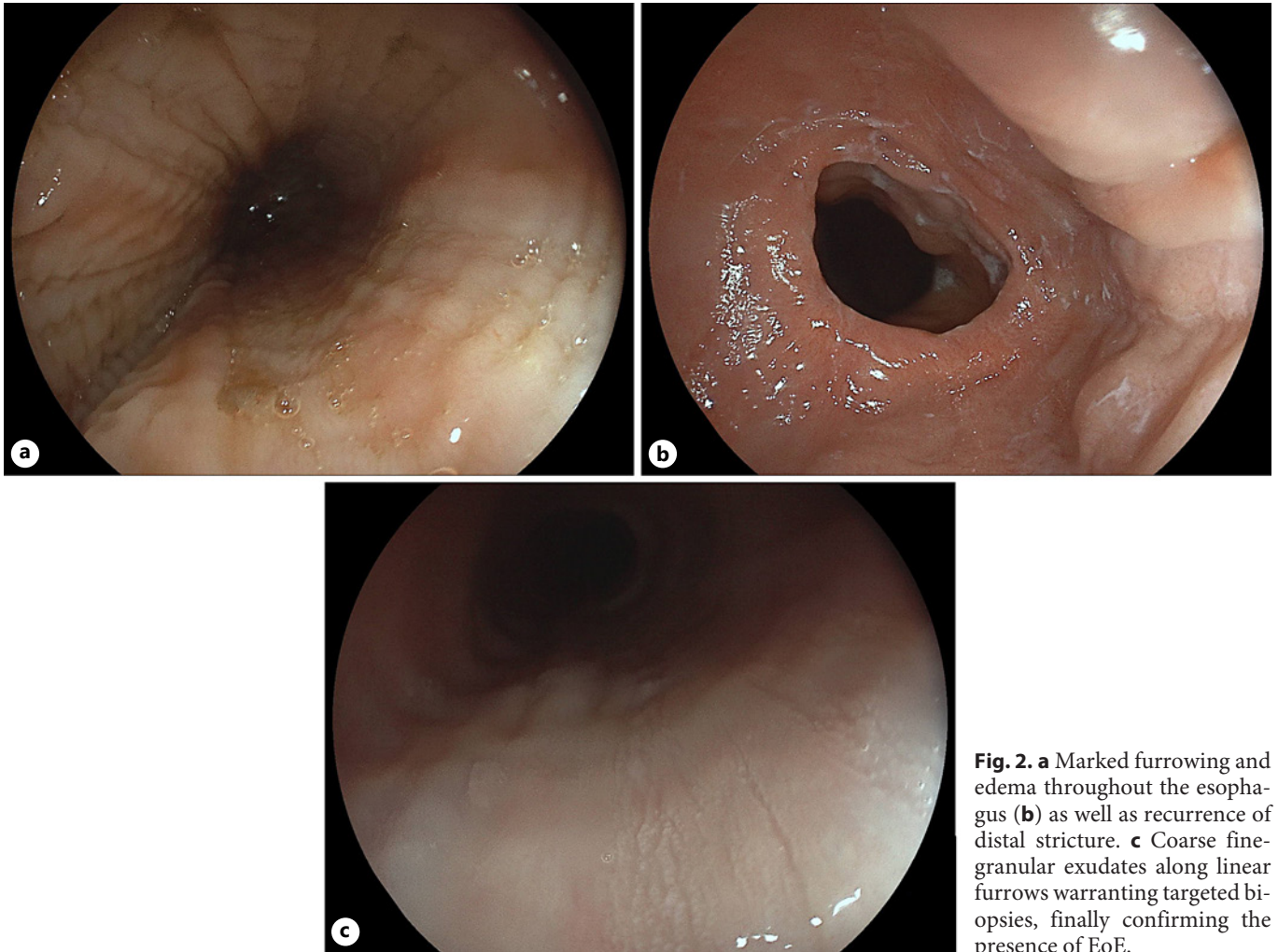


Fig. 2. **a** Marked furrowing and edema throughout the esophagus (**b**) as well as recurrence of distal stricture. **c** Coarse fine-granular exudates along linear furrows warranting targeted biopsies, finally confirming the presence of EoE.

Statement of Ethics

Ethical approval was not required for this study due to the retrospective design of the study, in accordance with local/national guidelines. The patient has given written informed consent for publication (including publication of images). The authors have no conflicts of interest to declare.

Funding Sources

No funding.

Author Contributions

Vincent Zimmer – clinical care and drafting and finalization of manuscript. Kai Emrich – pathology care and revision and finalization of manuscript.

Data Availability Statement

The data included in this study are not publicly accessible.

References

- 1 Attwood S, Epstein J. Eosinophilic oesophagitis: recent advances and practical management. *Frontline Gastroenterol*. 2021;12(7): 644–9.
- 2 Hillman L, Donohue S, Broman AT, Hoversten P, Gaumnitz E, Lomeli L. Empiric proton pump inhibitor therapy after esophageal food impaction may mask eosinophilic esophagitis diagnosis at follow-up. *Dis Esophagus*. 2021; 34(11):doab030.
- 3 Dellon ES, Liacouras CA, Molina-Infante J, Furuta GT, Spergel JM, Zevit N, et al. Updated international consensus diagnostic criteria for eosinophilic esophagitis: proceedings of the AGREE conference. *Gastroenterology*. 2018;155(4):1022–33. e10.
- 4 Hirano I, Chan ES, Rank MA, Sharaf RN, Stollman NH, Stukus DR, et al. AGA institute and the joint task force on allergy-immunology practice parameters clinical guidelines for the management of eosinophilic esophagitis. *Ann Allergy Asthma Immunol*. 2020;124(5): 416–23.
- 5 Odiase E, Schwartz A, Souza RF, Martin J, Konda V, Spechler SJ. New eosinophilic esophagitis concepts call for change in proton pump inhibitor management before diagnostic endoscopy. *Gastroenterology*. 2018; 154(5):1217–21.e3.