GE – Portuguese Journal of Gastroenterology

Endoscopic Snapshot

GE Port J Gastroenterol 2024;31:419–421
DOI: 10.1159/000536673

Received: October 21, 2023
Accepted: January 29, 2024
Published online: March 12, 2024

Tulip-Bundle Technique for Endoscopic Closure of 2 Chronic Gastrocutaneous Fistulas

Mara Sarmento Costa[a] Raquel Pimentel[a] Andrea Silva[a]
Margarida Ferreira[a] Nuno Almeida[a, b] Pedro Narra Figueiredo[a, b]

[a]Gastroenterology Department, Centro Hospitalar e Universitário de Coimbra, Coimbra, Portugal; [b]Faculty of Medicine, University of Coimbra, Coimbra, Portugal

Keywords
Gastrostomy · Enteral nutrition · Gastrointestinal endoscopy · Digestive system fistula

Técnica de "Tulip-Bundle" no encerramento endoscópico de 2 fístulas gastrocutâneas crónicas

Palavras Chave
Gastrostomia · Nutrição entérica · Endoscopia gastrointestinal · Fístula do trato digestivo

Introduction

Percutaneous endoscopic gastrostomy (PEG) should be considered a first-line technique for long-term enteral feeding. This option is not definitive, and if the tube is removed the gastrocutaneous tract is expected to start healing within 24 h. Nonetheless, in some patients the tract fails to heal and the gastrocutaneous fistula persists. Endoscopic management is nowadays considered the first-line step in these cases. Through-the-scope (TTSC) or over-the-scope clips, argon plasma coagulation (APC) or even endoscopy-assisted suturing are options in avoiding surgical intervention in these fragile patients [1, 2]. The authors present 2 cases with chronic and refractory gastrocutaneous fistulas, after removal of PEG tubes, in which a different endoscopic approach was attempted.

Case 1

An 82-year-old woman, with enteral tube feeding due to amyotrophic lateral sclerosis since October 2020, was hospitalized for peristomal leakage 1 year later. Analytically, there were no relevant abnormalities. Her 24-Fr PEG tube was removed, the fistula borders were endoscopically cauterized by APC and the fistula partially closed with 3 TTSC. A 20-Fr PEG tube was placed but, 1 month later, we opted for permanent removal due to maintained peristomal drainage. Two weeks later the fistula persisted, so we proceeded with closure with an adapted tulip-bundle technique. The fistula edges were cauterized by APC, at 1.5L/min 50W, and an Endoloop® was positioned, anchored to the bordering normal mucosa, with five 11 mm TTSC, as seen in Figure 1a and b. The Endoloop® was tightened, with

Mara Sarmento Costa and Raquel Pimentel contributed equally to this work.

karger@karger.com
www.karger.com/pjg

© 2024 The Author(s).
Published by S. Karger AG, Basel

Karger
OPEN ACCESS

This article is licensed under the Creative Commons Attribution-NonCommercial 4.0 International License (CC BY-NC) (http://www.karger.com/Services/OpenAccessLicense). Usage and distribution for commercial purposes requires written permission.

Correspondence to:
Mara Sarmento Costa, 11654@chuc.min-saude.pt

Downloaded from http://karger.com/pjg/article-pdf/31/6/419/4308642/000536673.pdf by guest on 07 December 2024

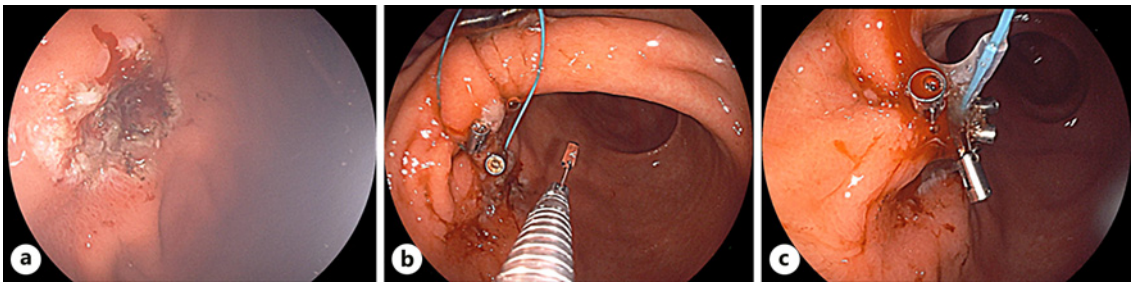

Fig. 1. Endoscopic closure of a chronic and refractory gastrocutaneous fistula in an 82-year-old woman. **a** Cauterization by APC of the defect borders. **b** After Endoloop® introduction and positioning, 5 TTSC were required and anchored in the adjacent normal mucosa. **c** Endoscopic closure of the defect after Endoloop® tightening.

adequate endoscopic closure (shown in Fig. 1c). No procedure-related complications were reported. The patient passed away in April 2022 without fistula recurrence.

Case 2

A 42-year-old quadriplegic man, under PEG tube feeding since June 2015, was first admitted for abdominal wall cellulitis in September 2021, as seen in Figure 2. At admission, hemoglobin, albumin, and natremia were low (10.3 g/dL, 2.8 g/dL, and 135 mmol/L, respectively). His 24-Fr feeding tube was removed, a guidewire was positioned in its place, and antibiotics were started. As drainage persisted, we opted for endoscopic treatment. The fistula edges were cauterized by APC, at 1.5L/min 50W, before an over-the-score clips was positioned. Although with initial success, 2 months later the fistula reoccurred and a new endoscopy attempt was performed with 8 TTSC. An unsuccessful attempt to use the tulip-bundle technique was made, with Endoloop® failure. Five months later drainage persisted, and endoscopic treatment with tulip-bundle technique was proposed. Following cauterization of the edges, an Endoloop® was anchored to the mucosa bordering the defect using six 11 mm TTSC. The Endoloop® was tightened and closed the fistula edges, as illustrated in Figure 3a–c. This procedure was uneventful, and the patient was discharged with successful fistula closure. Unfortunately, 1 year later, probably due to patient's intrinsic frailty, the fistula recurred, and surgical repair was deemed necessary.

Only a handful of cases using the endoscopic tulip-bundle technique for closure of chronic gastrocutaneous fistulas have been described so far [3, 4]. Even so, it is an efficient and safe nonsurgical option, particularly helpful in high-risk patients. One could argue its role as an early approach for gastrocutaneous fistulas in the hope of reducing recurrence.

Fig. 2. Abdominal wall cellulitis in a 42-year-old quadriplegic man with enteral tube feeding.

Downloaded from http://karger.com/pjg/article-pdf/31/6/419/4308642/000536673.pdf by guest on 07 December 2024

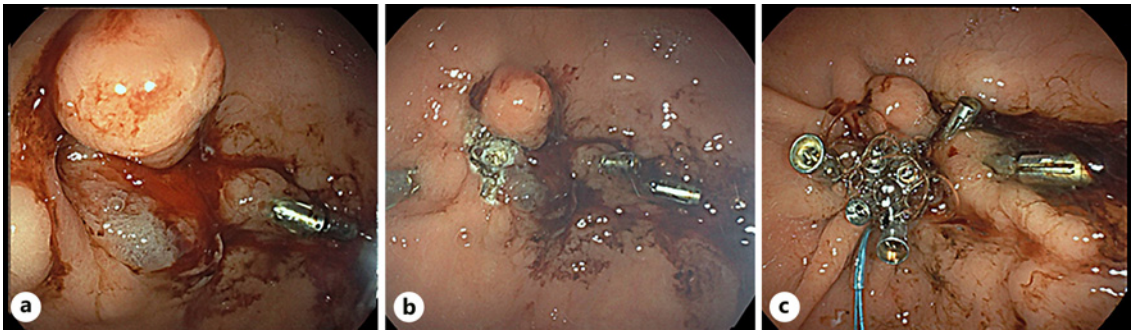

Fig. 3. Endoscopic closure of the second chronic and refractory gastrocutaneous fistula described. **a** and **b**: Cauterization by APC of the defect borders. **c** The Endoloop® was positioned using 6 TTSC and tightened, successfully closing the fistula.

Statement of Ethics

Informed consent was obtained from participants' next-of-kin for publication of the details of their medical case and accompanying images. This type of manuscript (case report) did not require ethical approval due to local laws.

Conflict of Interest Statement

The authors have no conflicts of interest to declare.

Funding Sources

This study was not supported by any sponsor or funder.

Author Contributions

Mara Sarmento Costa and Raquel Pimentel were responsible for the report's conception and design, acquisition of data, analysis and interpretation of data and drafting the manuscript and thus should be considered co-first authors. Andrea Silva, Margarida Ferreira, Nuno Almeida, and Pedro Figueiredo were responsible for critical revision of the article. All authors agreed with the final revision of the manuscript.

Data Availability Statement

All data generated or analyzed during this study is included in this article. Further inquiries can be directed to the corresponding author.

References

1 Gkolfakis P, Arvanitakis M, Despott EJ, Ballarin A, Beyna T, Boeykens K, et al. Endoscopic management of enteral tubes in adult patients: Part 2: peri- and post-procedural management. European Society of Gastrointestinal Endoscopy (ESGE) Guideline. Endoscopy. 2021; 53(2):178–95.

2 Macedo C, Almeida N, Alves AR, Ferreira AM, Figueiredo P. Persistent peristomal leakage from percutaneous endoscopic gastrostomy successfully treated with argon plasma coagulation. GE Port J Gastroenterol. 2021;28(3):210–4.

3 Ponte A, Pinho R, Pinto-Pais T, Rodrigues A, Ribeiro I, Proença L, et al. External digital pressure to enable a deeper tulip-bundle technique for endoscopic closure of a refractory chronic gastrocutaneous fistula. Gastroenterol Hepatol. 2017;40(4):290–1.

4 Perri F, Gentile M, Scimeca D, Terracciano F, Merla A, Spirito F, et al. Closure of a gastrocutaneous fistula by a tulip-bundle technique. Endoscopy. 2011;43(Suppl 2 UCTN): E419.

Downloaded from http://karger.com/pjg/article-pdf/31/6/419/4308642/000536673.pdf by guest on 07 December 2024