

Caso Clínico

Clinical Case

C Damas¹
A Morais²
C S Moura³
J A Marques⁴

Pneumonia aguda fibrinosa e organizante

Acute fibrinous and organizing pneumonia

Recebido para publicação/received for publication: 06.03.28

Aceite para publicação/accepted for publication: 06.05.26

Resumo

A designação *acute fibrinous and organizing pneumonia* (AFOP) foi proposta por Beasley *et al* para os casos em que as características histopatológicas das lesões não se enquadravam em outras situações clínicas (agudas ou subagudas) conhecidas. A presença de fibrina intra alveolar e de pneumonia organizativa, com distribuição difusa, é a principal alteração histológica associada a esta entidade.

Os autores descrevem o caso de um doente do sexo masculino, com o diagnóstico de AFOP, por biópsia pulmonar cirúrgica. O doente teve uma apresentação subaguda, apresentando por queixas principais tosse, dor torácica e febre. TAC torácica mostrou infiltrados bilaterais, difusos. Após início

Abstract

The term Acute Fibrinous and Organizing Pneumonia (AFOP) has been proposed by Beasley *et al* for cases that not fit into the histopathologic criteria of the recognized entities described as acute or subacute clinical presentations. The presence of intra-alveolar fibrin in the form of fibrin 'balls' and organizing pneumonia with patchy distribution are the main histological features of this entity. We describe the case of a male patient with the diagnostic of AFOP made by surgical lung biopsy. He had a subacute presentation of symptoms consisting of productive cough, chest pain and fever. Bilateral infiltrates with patchy and diffuse distribution were the predominant features in his chest HRCT scan. The patient had a good

¹ Interna Complementar de Pneumologia

² Assistente Hospitalar de Pneumologia

³ Assistente Hospitalar de Anatomia Patológica

⁴ Chefe de Serviço de Pneumologia, Professor Catedrático de Pneumologia da FMUP, Director do Serviço de Pneumologia

Serviço de Pneumologia, Hospital de São João, EPE, Porto
Faculdade de Medicina da Universidade do Porto (FMUP)

Correspondência/Correspondence to: Carla Damas
Travessa Fernando Namora, 48 5.º Esq.
4425 Pedrouços – Maia
Portugal

de corticoterapia sistémica e ciclofosfamida, o doente apresentou melhoria clínica significativa. Ao elaborar este caso, os autores esperam acrescentar mais alguns dados sobre esta nova entidade.

clinical course after a treatment with prednisone and cyclophosphamide. Our hope in reporting this case study is to add some more data to the discussion of this new entity.

Rev Port Pneumol 2006; XII (5): 615-620

Rev Port Pneumol 2006; XII (5): 615-620

Palavras-chave: AFOP, pneumonia organizativa.

Key-words: AFOP, organizing pneumonia.

Case report

In September of 2003 a 66 year old Caucasian man, with abnormal lung radiological findings and two month history of productive cough and diffuse thoracic pain was admitted to our hospital. He was a retired judge, smoker (20 packs a year) and had no relevant clinical history previous to the present episode. One month earlier he had visited his primary care physician who requested a chest radiograph which showed bilateral reticulonodular opacifications with basal predominance (Fig. 1). The CT scan confirmed bilateral lung consolidations with basal and peripheral prevalence (Fig. 2). Treatment with antibiotic was prescribed and his clinical condition improved. However radiological worsening with enlargement and spread of lung opacifications (Fig. 3) was seen in re-evaluation after antibiotic treatment. After this he was admitted to our ward where he did not present any other symptoms besides those initially described. On admission he was alert, temperature was 36.4°, pulse 92 beats per minute, respiratory rate 19 breaths per minute and blood pressure 133/73 mmHg. No signs of respiratory discomfort were seen. Heart sounds and ab-

domen were normal and there were no peripheral edemas. Reduced respiratory sounds and diffuse crackles were heard in lung lower zones and heart sounds were normal. The WBC count, sedimentation rate, serum electrolytes, liver tests, creatinine level and urinalyses were in the normal range. Sputum specimens contained few neutrophils, with no microorganisms. A serious restrictive ventilatory pattern and lung diffusion impairment were observed in lung function testing (Table I). Arterial blood gas measurements indicated a partial pressure of oxygen of 68 mmHg, a partial pressure of carbon dioxide of 39 mmHg and the ph 7.37. Cardiac doppler ultrasonography revealed no marked changes.

Table I

FVC	1.81 (42%)
FEV1	1.59 (48%)
FEV1/FVC	88%
VC	1.81 (40%)
TLC	3.85 (53%)
RV	2.04 (79%)
RV/TLC	40 (53%)
DLCO/VA (ml/mmHg/min/L)	2.25 (44%)

PNEUMONIA AGUDA FIBRINOSA E ORGANIZANTE

C Damas, A Morais, C S Moura, J A Marques

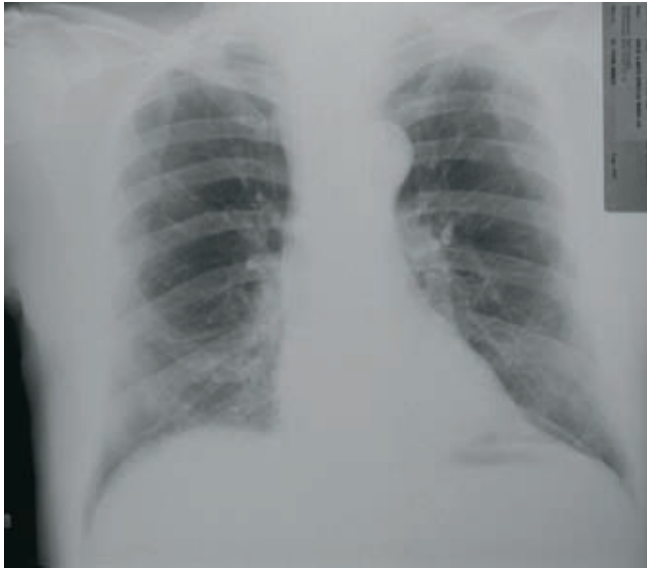

Fig. 1

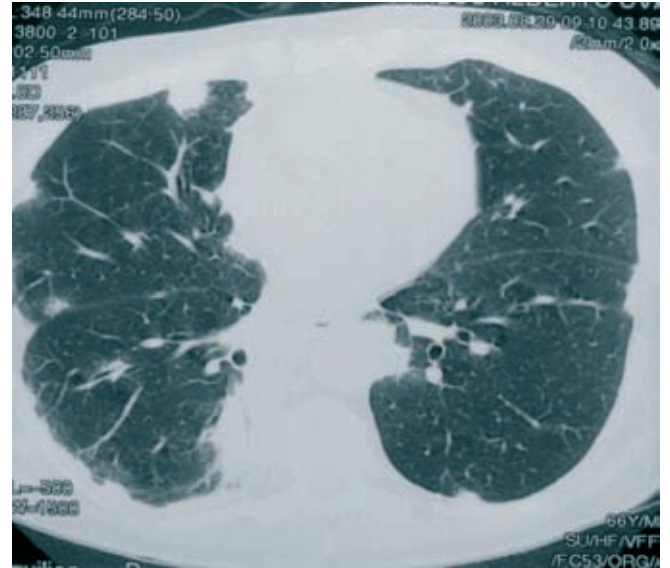


Fig. 2

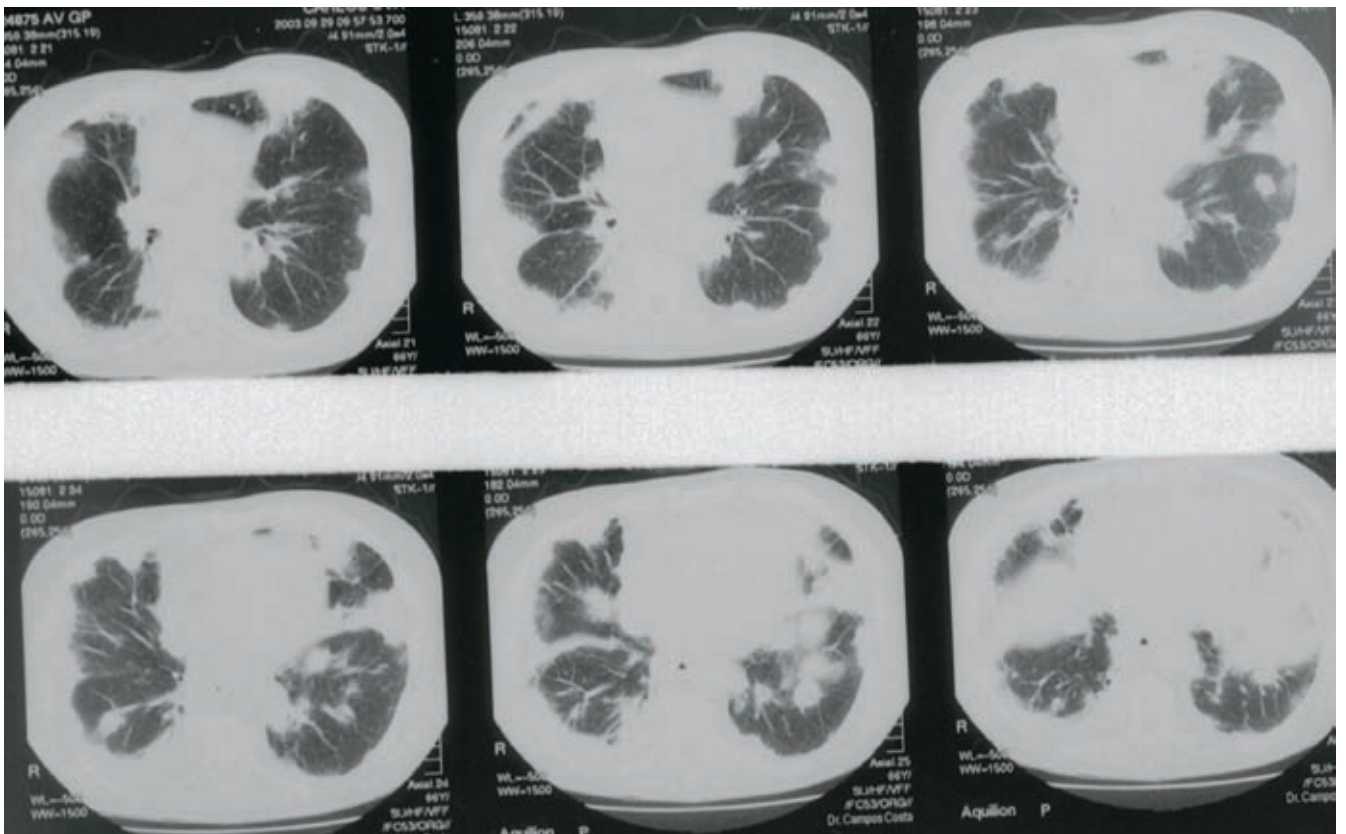


Fig. 3

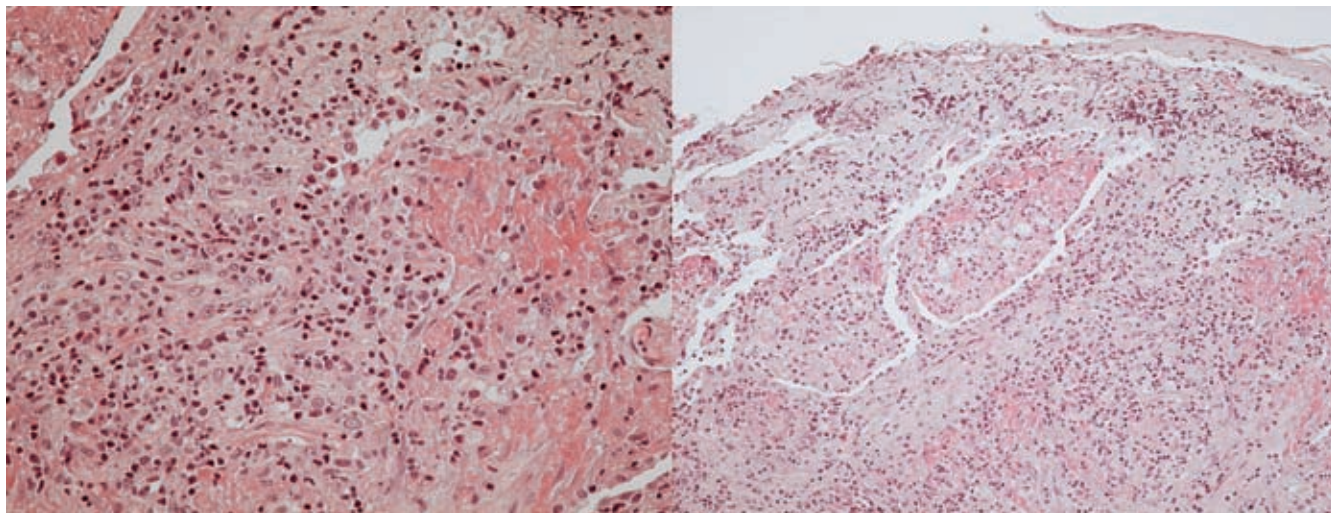


Fig. 4

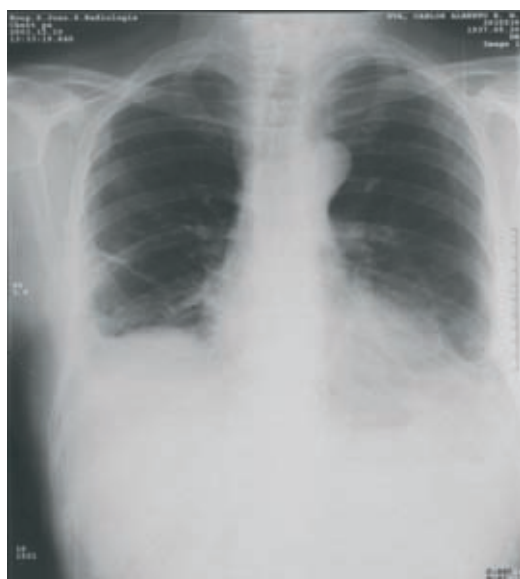


Fig. 5

No visible endobronchial secretions were seen in bronchoscopy examination. Examination of bronchoalveolar lavage (BAL) specimen did not show any microorganisms. There were no malignant cells either. The bronchoalveolar fluid contained high levels of neutrophils (16.6%), lymphocytes (16%) and eosinophils

(2.8%). The lymphocytes were predominantly CD8+ (CD4-18.8%, CD8-71.1%).

During the clinical investigation the patient had a clinical deterioration, namely with dyspnoea and fever. Since we could not reach a definitive diagnosis an open lung biopsy were performed. Lung tissue without preservation of alveolar architecture was obtained caused by destruction due to an inflammatory process. There were some granulomas, with areas of necrosis and other with fibrin and connective tissue in organization in the alveolar spaces, assuming characteristics of acute fibrinous pneumonia in resolution.

The treatment consisted initially of prednisone (1 mg/Kg/day) with clinical, functional and radiological improvement. Some weeks later, because of some lateral effects related to prednisone, cyclophosphamide (150 mg/day, po) was added to prednisone and a good clinical course was observed.

Currently, nearly eighteen months after the first symptoms the patient is asymptomatic but still under treatment (prednisone and cyclophosphamide in tapering doses).

Discussion

In 2002 Beasley MB *et al.* described a new histological pattern named Acute Fibrinous Organizing Pneumonia (AFOP)¹ after a re-evaluation of lung specimens obtained in patients with acute or subacute clinical presentations. This histologic pattern is mainly composed of the presence of intra-alveolar fibrin in the form of fibrin 'balls' and organizing pneumonia with a patchy distribution². These histological characteristics are separate from those associated with the well recognized entities described in patients with acute or subacute clinical presentations such as Diffuse Alveolar Damage (DAD), Bronchiolitis Obliterans with Organizing Pneumonia (BOOP) and Eosinophilic Pneumonia (EP). No hyaline membranes were seen as in DAD and despite the presence of eosinophils in some specimens, they were never predominant as in EP. Instead of organized fibrin balls, Organizing Pneumonia (OP) has fibroblastic Masson bodies within alveolar spaces, ducts and bronchioles as dominant feature. The authors also hypothesized that this histological pattern might be a fibrinous variant of DAD¹ since the mortality rates are similar and the AFOP pattern was observed focally in DAD specimens, suggesting inadequate samples in some of the related cases. However, the lack of hyaline membranes, the presence of intra-alveolar fibrin in the form of fibrin 'balls' and the patchy distribution adding to a better clinical course than seen in DAD suggests that the AFOP findings probably represent a singular histologic pattern that was never previously identified³.

The first aim of describing this case study was to contribute with more data to discussing the consistency of this new his-

tological pattern. All 17 patients classified as having AFOP by Beasley *et al.* presented constitutional and/or respiratory symptoms no more than two months before biopsy. Gradually increasing dyspnea and dry cough were the most common presenting symptoms. Our patient's clinical features had similarities with most of those patients. He had a subacute presentation consisting of productive cough, chest pain and fever, 2 months prior to the admission in our hospital. Chest HRCT scan demonstrated bilateral infiltrates, initially with basal and peripheral predominance progressing to other areas and becoming patchy and diffuse. These radiological features agree with Beasley *et al.* who observed diffuse parenchymal abnormalities mostly with patchy areas of infiltrates predominantly in the lower lung zones. Pulmonary function testing showed a moderate to severe restrictive impairment (TLC-53%) in our patient. He had also a severe decrease in the diffusion capacity of the lung for carbon monoxide and hypoxia at rest (paO₂- 68 mmHg). As there is no data about lung function in Beasley's study these results cannot be compared. However they are similar to those described in a case study by Bawa AS. *et al.*, except for the lower restrictive impairment observed in this case. In bronchoalveolar lavage fluid (BALF) a high neutrophil count (16%) was the predominant finding. There also a lack of data about this procedure in other publications. Several medications were used in Beasley's series, namely steroids and antibiotics. However no treatment was identified as the most advantageous. The good clinical course observed in our patient

demonstrates that the addition of cyclophosphamide to corticosteroids might be a useful treatment for patients with AFOP.

Two different outcomes have been observed by Beasley with nine patients having a rapid progression to death (average of 29 days). On the contrary, the rest recovered and are alive and healthy. As in other histological patterns of acute and subacute lung injury, AFOP can occur as an idiopathic form or be associated with known causes or underlying diseases (infectious causes, connective tissue disorders, occupational and drug exposures). There were no significant occupational and drug exposures or evidence of an underlying disease so far. Additionally the examination of sputum and BAL did not reveal any microorganisms besides normal respiratory flora specimens. These features suggest an idiopathic nature to this clinical case.

In conclusion AFOP seems to define a distinct histological pattern associated with a diffuse lung disease with a better outcome than others with an acute or subacute presentation. However further presentation of new clinical cases and patient series are necessary to support the validity of this new histological pattern and understand its clinical picture.

Bibliography

1. Beasley, MB, Franks, TJ, Galvin, JR, Gochuico, B, Travis, WD. Acute Fibrinous and Organizing Pneumonia: a histologic pattern of lung injury and possible variant of diffuse alveolar damage. *Archives of Pathology and Laboratory Medicine* 2002; 126 (9):1064-70.
2. Cordier, JF. Organizing Pneumonia. *Thorax* 2002; 55:318-28.
3. Ryu, JH, Myers, JL, Swensen, SJ. Bronchiolar Disorders. *Am J Resp and Crit Care Med* 2003; 168:1277-129.