

Case Report

Unilateral bifid condyle: a case report



Caroline Caldeira Tomagnini^{a,*}, Júllia Martins Viana Pinto^a, Tatielly Karine Costa Alves^a,
Idalísio Soares Aranha Neto^a, Amaro Ilídio Vespasiano^b, Flávio Ricardo Manzi^b

^a Department of Dentistry, Pontifícia Universidade Católica de Minas Gerais – PUC Minas, Minas Gerais, Brazil.

^b Department of Radiology, School of Dentistry, Pontifícia Universidade Católica de Minas Gerais – PUC Minas, Minas Gerais, Brazil.

ARTICLE INFO

Article history:

Received 4 February 2020

Accepted 29 November 2020

Available online 27 December 2020

Keywords:

Anatomical variation

Bifid condyle

Temporomandibular dysfunction

ABSTRACT

In the present case report, a patient attended the Surgical Clinic of PUC-MG for extraction of third molars. When performing the panoramic radiography, an atypical shaping of the mandibular condyle was detected. For the correct diagnosis, a cone-beam computed tomography was requested. The axial, sagittal, and coronal tomographic sections clearly showed the structure and its position in relation to the skull. The exam showed unilateral hyperdense masses on the left, in the form of mediolaterally oriented secondary condylar heads. Although they were adjacent to the condylar head, a constriction between them was observed in the superior condylar pole region. This image analysis, associated with the absence of functional changes and symptomatology, was decisive for the diagnosis of a bifid condyle, as it allowed to exclude any pathological alteration. As its etiology is diverse, this type of anatomical variation is usually found in routine imaging exams, as in the present study. The bifid condyle can be considered a differential diagnosis of condylar hyperplasia, osteochondromas, or alterations related to temporomandibular dysfunction in two-dimensional radiographic exams. (Rev Port Estomatol Med Dent Cir Maxilofac. 2020;61(4):192-196)

© 2020 Sociedade Portuguesa de Estomatologia e Medicina Dentária.

Publicado por SPEMD. Este é um artigo Open Access sob uma licença CC BY-NC-ND (<http://creativecommons.org/licenses/by-nc-nd/4.0/>).

* Corresponding author.

E-mail address: caroltomagnini@gmail.com (Caroline Caldeira Tomagnini).

<http://doi.org/10.24873/j.rpemd.2020.12.814>

1646-2890/© 2020 Sociedade Portuguesa de Estomatologia e Medicina Dentária. Published by SPEMD.

This is an open access article under the CC BY-NC-ND license (<http://creativecommons.org/licenses/by-nc-nd/4.0/>).

Côndilo bífido unilateral: caso clínico

R E S U M O

Palavras-chave:

Variação anatômica
Côndilo bífido
Disfunção temporomandibular

No presente relato de caso, o paciente compareceu à Clínica Cirúrgica da PUC-MG para extração de terceiros molares. Ao realizar radiografia panorâmica, foi detectada uma formação atípica do côndilo mandibular. Para o diagnóstico correto, foi solicitada uma tomografia computadorizada de feixe cônico e, nas seções axial, sagital e coronal, foi possível visualizar claramente a estrutura e sua posição em relação ao crânio. O exame mostrou massas hiperdensas unilaterais à esquerda, na forma de cabeças condilares secundárias orientadas mediolateralmente. Embora estivessem adjacentes à cabeça condilar, uma constrição entre eles foi observada na região do pólo condilar superior. Essa análise de imagem, associada à ausência de alterações funcionais e sintomatologia, foi decisiva para a conclusão do diagnóstico de côndilo bífido, pois permitiu excluir qualquer alteração patológica. Como sua etiologia é diversa, geralmente esse tipo de variação anatômica é encontrado nos exames de imagem de rotina, como no presente estudo. Essa variação anatômica pode ser considerada um diagnóstico diferencial de hiperplasia condilar, osteocondromas ou alterações relacionadas à disfunção temporomandibular em exames radiográficos bidimensionais. (Rev Port Estomatol Med Dent Cir Maxilofac. 2020;61(4):192-196)

© 2020 Sociedade Portuguesa de Estomatologia e Medicina Dentária.

Published by SPEMD. This is an open access article under the CC BY-NC-ND license (<http://creativecommons.org/licenses/by-nc-nd/4.0/>).

Introduction

The bifid condyle is a rare anatomic condition that was reported for the first time by Hrdlička in 1941 in a specimen skull. This condition is manifested by a depression or deep cleft in the center of the condylar head with an anteroposterior or mediolateral orientation. Its etiology is not well known and may be somewhat diversified, as it may be associated with a congenital malformation, trauma, or even tumoral lesions.^{1,2}

The bifid condyle is generally an accidental finding in routine radiographic exams. It may be detected first in a panoramic radiograph, and then, a computed tomographic exam may be performed as an alternative method of diagnosis.³ For the correct diagnosis of the bifid condyle, the two-dimensional panoramic radiographic image alone would not be sufficient because it could lead the examiner to considering other anomalies such as condylar hyperplasia or osteochondroma. On the other hand, in 3D images obtained using cone-beam computed tomography, these three conditions are shown differently.⁴

The association between the condylar heads' orientation and the bifid condyle is controversial between authors. According to Dennison *et al.*,⁵ only an anteroposterior orientation of the condyle represents a "true" bifid condyle, while the mediolateral orientation would be a "condylar nothing." On the other hand, López-López⁶ defends that the condylar heads' orientation is not an indicator of the bifid condyle and both condylar heads have to emerge from the condylar neck in order to be considered true bifid condyles.

After the diagnosis has been defined, the appropriate treatment for the case can be determined. In the absence of symptoms, adequate follow-up must be maintained to improve the patient's quality of life.⁷ In symptomatic cases, depending on their severity, different treatments must be performed accord-

ing to the symptoms. Non-steroid anti-inflammatory drugs, analgesics, physical therapy, and occlusal plates are recommended as a conservative approach. Surgical treatment has been described only for restoring the function of a bifid condyle with ankylosis or symptomatic cases that have been resistant to conservative treatment.⁸

The present study aimed to report a case of a unilateral bifid condyle of unknown etiology in a patient who presented to the surgery clinic of the Department of Dentistry of the Pontifical Catholic University of Minas Gerais (PUC-Minas) for third-molar extraction. When imaging exams were requested, an uncommon anatomic shape was observed in the mandibular condyle on the left side.

Case report

A 27-year-old male patient presented to the Department of Dentistry of PUC-Minas to evaluate the possibility of extracting his third molars. During anamnesis, the patient reported no systemic changes. Intraoral and extraoral examinations revealed no changes in the following aspects: facial symmetry without functional changes, lateral and protrusion movements without pain complaints, no deviations, and no compromising mouth opening and closing. Following the University's protocol for third-molar and supernumerary-teeth evaluation in the region, a panoramic radiograph was requested. It revealed radiopaque images added to the condylar head on the left side, causing morphological changes. These findings suggested the diagnostic hypothesis of a unilateral bifid condyle (Figure 1).

A cone-beam computed tomography scan was requested to obtain sufficient sagittal, axial, and coronal tomographic

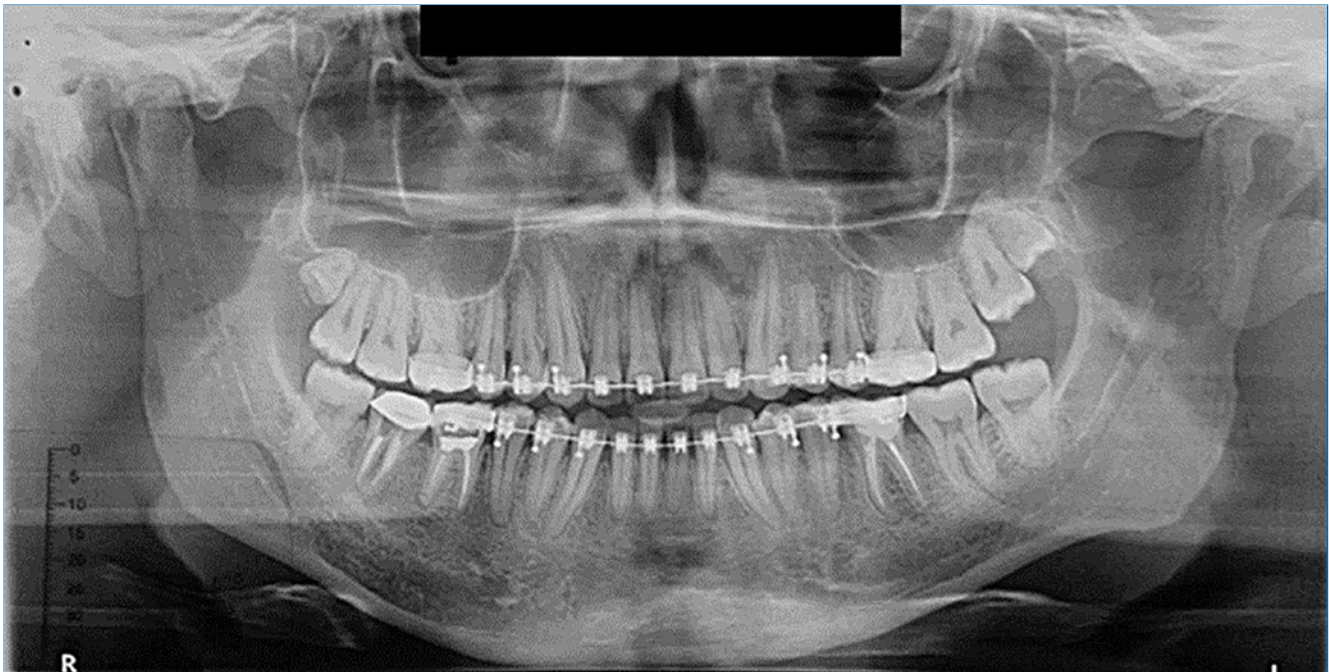


Figura 1. Panoramic radiograph showing an uncommon shape of the left mandibular condyle with radiopaque masses added to its superior portion.

images for a 3D reconstruction. This reconstruction allowed better visualization of the condyle in the three spatial planes and its position in relation to the mandibular fossa (Figures 2, 3, and 4). The exam showed evidence of unilateral hyperdense masses on the left, in the shape of secondary medio-laterally oriented condylar heads. Although these were contiguous to the condylar head, a constriction between them was noted in the superior condylar pole region, as demonstrated by the 3D reconstruction and sagittal sections (Figure 3). Despite the morphological change noted in the left condyle, the anatomic structure was uniform, and the patient reported no functional change (Figure 4). Therefore, the diagnostic hypothesis of a left unilateral bifid condyle was confirmed.

On the right side, coronal reconstructions of the condylar process showed flattening on the superior pole. On the left side, the condylar process showed beveling of the superior pole, with a bifurcation and formation of two articular surfaces, thus exhibiting evidence of bifid condyle. In addition, a morphological adaptation of the mandibular fossa on both sides was noted, with flattening on the right side and sinuous ridges on the left side, accompanying the shape of the condylar processes (Figure 4).

As the condition was asymptomatic in this patient, no interventional treatment was performed at this time. However,

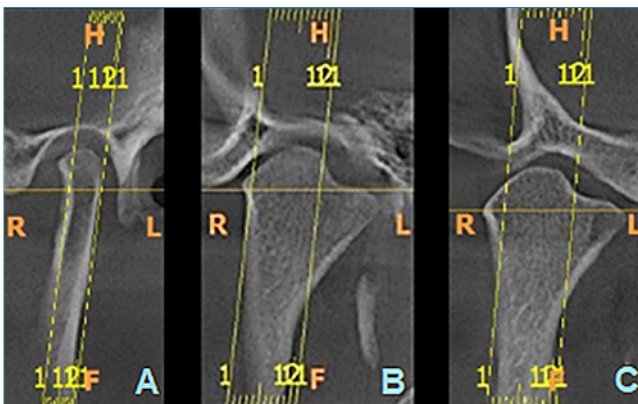


Figura 2. Tomographic sections of the left condylar process. A. Coronal Section - Closed Mouth; B. Sagittal Section - Closed Mouth; and C. Sagittal Section - Open Mouth.

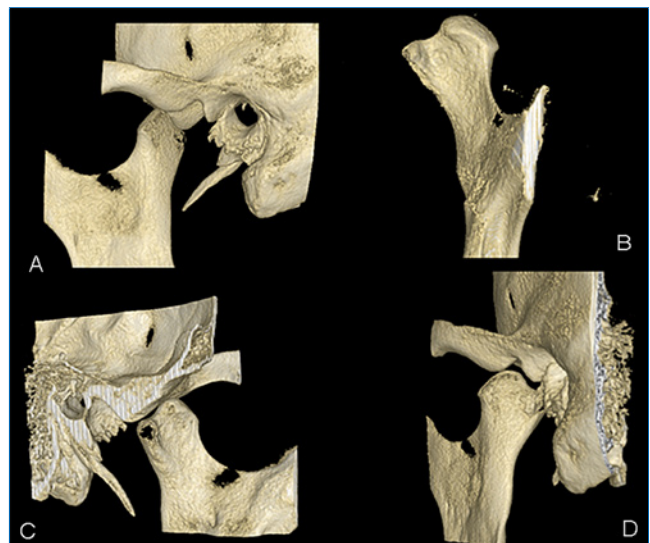


Figura 3. Three-dimensional reconstruction of the condylar process. A - side view; B - anterior view; C - medial view; D - posterior view.

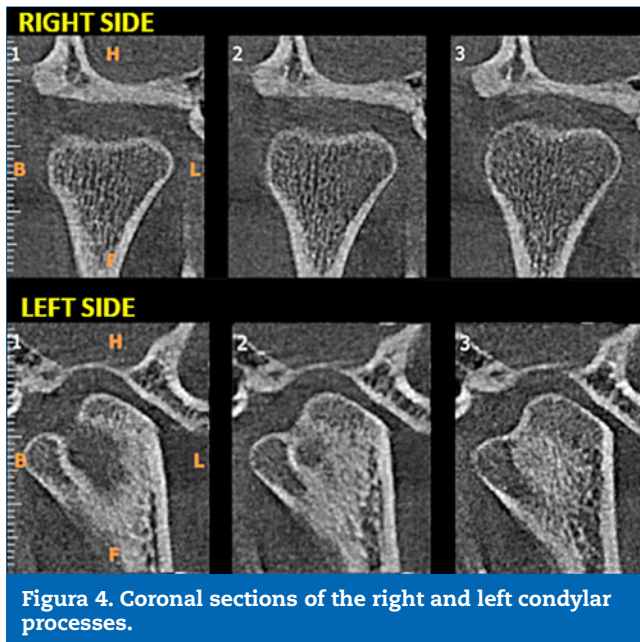


Figura 4. Coronal sections of the right and left condylar processes.

active monitoring through imaging exams was recommended. Moreover, the patient was recommended to seek professional care at the University clinic if any change occurred in his clinical condition. At present, the patient is being followed with clinical and radiographic exams, and annual follow-ups are foreseen.

Discussion and conclusions

The condition of unilateral bifid condyle manifested by a secondary condylar head is a most uncommon finding. In the case presented, the clinical findings were in agreement with those reported in a retrospective study,⁹ in which 40% of the cases observed were asymptomatic and generally associated with a non-traumatic etiology, frequently detected during a routine exam for the removal of third molars.

Concerning the prevalence between sex and age, according to a systematic review,⁸ patients with bifid condyle had an average age of 30.6 years, with women being more frequently affected than men in a ratio of 4:1. Unilateral impairment was the most prevalent condition, although there was a notable proportion of bilateral bifid condyle.⁸ In the present case, the 27-year-old patient was affected by a unilateral condition.

Bifid condyle's etiology is not well known. It can be considerably diversified and may be associated with a congenital malformation, trauma, infection, nutritional disorders, radiation exposure, developmental abnormalities, teratogenic embryopathy, tumors, or condylectomy.¹⁰ In this case report, the patient did not report any trauma or surgery and did not present with symptoms and clinical signs that could indicate the causal factor.

Shriki *et al.*¹¹ hypothesized that the bifid condyle with a mediolateral orientation of the head was a developmental phenomenon and not the result of trauma. Accordingly, many studies have reported that most patients who had mediolat-

eral bifid condyles had no history of trauma.¹² In the present case, this possibility was not considered, as the patient did not report any previous trauma.

The condyle's morphology is a controversial topic regarding the factors that characterize a "true" and a "false" bifid condyle. According to López-López,⁶ the orientation of these condylar heads is independent of the condition and a "true" bifid condyle depends only on both heads emerging from the condylar neck.⁶ In the present case, the condyle was located in the mediolateral direction, in agreement with the situation proposed by these authors. Therefore, the bifid condyle was in the axial and coronal projections of the mandible as bilateral hyperdense bony masses in the shape of secondary mediolaterally oriented condylar heads. Although they were apparently contiguous with the condylar head, a constriction was observed between the two parts.

Because the panoramic radiograph was not specific, for a complete visualization of the bifid condyle, a 3D tomographic reconstruction was produced in this study. The same was described by Tanner *et al.*³ On the other hand, Dennisson *et al.*¹⁵ considered that the mandibular condyles were oriented obliquely, and therefore, the condylar heads could not be visualized in a single projection.³

The appropriate treatment for the bifid condyle depends on the symptoms presented. Some authors¹³ believe that this condition plays a role in some cases of temporomandibular disorder (TMD) and may be confused with an early diagnosis of condylar fracture; this shows the importance of a correct diagnosis. After careful clinical examination combined with complementary imaging exams, patients diagnosed with internal articular derangement should be treated according to the severity of the condition, which may include using occlusal splints and arthroscopic surgery.⁷ In asymptomatic cases, such as the one described in this case report, patients must be followed up and require no intervention if functional changes are not observed.

The bifid condyle can also be a differential diagnosis of pathologies such as condylar hyperplasia and osteochondroma. However, knowledge of its clinical and imaging presentation is necessary. Moreover, before performing other complementary exams, differentiation between the above-mentioned conditions is recommended through methods such as scintigraphy and histopathology. It is worth emphasizing that, for a correct diagnosis, an ideally clear differentiation should be observed between the two pathological changes cited. Therefore, scintigraphy or even a histopathological exam must be performed to detect bone development at the site.⁴

Osteochondroma is pointed out as being one of the most common benign bone tumors that mainly affect the long bones. Intraorally, its highest prevalence is in the condyle and mandibular coronoid processes. It is frequently discovered through routine imaging exams, as the bifid condyle. The osteochondroma is usually treated with surgical excision in a procedure denominated low condylectomy.⁴ Conversely, in asymptomatic cases of bifid condyles, such as the one here reported, there is no need for intervention.

In turn, in condylar hyperplasia, a more regular contour is observed, showing an inverted pyramid with an increased volume of the mandibular head and a longer neck.¹⁴ The bifid

condyle here presented was visualized as unilateral hyperdense masses in the shape of secondary mediolaterally oriented condylar heads. Although they were contiguous to the condylar head, a constriction between them was noted in the mandibular notch region (mandibular incisure).

The individual evaluation of panoramic radiographs leads to an incorrect diagnosis of bifid condyle cases because of this technique's technical limitations, such as superimpositions and loss of some details, like any other bidimensional visualization.¹⁵ Therefore, tomographic images are pointed out as decisive for the final diagnosis of this condition. Furthermore, there is an increasing incidence of bifid condyle as more high-quality exams become available, proving the need for studies on this condition.¹⁵ In the case described, a panoramic radiograph was initially requested, and then a cone-beam computed tomography was performed as a complementary imaging exam to determine the diagnosis.

In conclusion, the dentists' clinical experience must include knowledge of rare conditions such as the bifid condyle because this variation from normality is the differential diagnosis of pathological conditions such as condylar hyperplasia and osteochondroma. These three conditions have similar radiographic aspects and can lead the clinician to suspect a previous fracture of the condylar process, suggesting a potential change in the mandibular shape since this concerns an area related to growth. The possibility of causing functional changes in the patient, such as TMD, leads to the need for a more meticulous assessment of changes that may be associated with the case, such as limited or altered mandibular movements. Therefore, the professional must know how to distinguish these lesions and promote a correct diagnosis. For this to occur, the dentist must be aware of the indications when requesting complimentary exams to reach a diagnosis and elaborate a feasible treatment plan.

Ethical disclosures

Protection of human and animal subjects. The authors declare that no experiments were performed on humans or animals for this study.

Confidentiality of data. The authors declare that no patient data appear in this article.

Right to privacy and informed consent. The authors have obtained the written informed consent of the patients or subjects mentioned in the article. The corresponding author is in possession of this document.

Conflict of interest

The authors have no conflicts of interest to declare.

REFERENCES

- Hrdlicka A. Lower jaw: double condyles. *Am J Phys Anthropol.* 1941;28:75-89.
- Ulutürk H, Yücel E, Okur B, Akinci O, Atac MS. Surgical management of a bilateral bifid condyle. *Niger J Clin Pract.* 2018;21:251-5.
- Tanner JM, Friedlander AH, Chang TI. Bilateral bifid mandibular condyles diagnosed with three-dimensional reconstruction. *Dentomaxillofac Radiol.* 2012;41:691-5.
- Venturin, JS et al.: Temporomandibular Joint Condylar Abnormality: Evaluation, Treatment Planning, and Surgical Approach. *J Oral Maxillofac Surg.* v;2010;68:1189-96.
- Dennison J, Mahoney P, Herbison P, Dias G. The false and the true bifid condyles. *Homo.* 2008;59:149-59.
- López-López J, Ayuso-Montero R, Salas EJ, Roselló-Llabrés X. Bifid Condyle: Review of the Literature of the Last 10 Years and Report of Two Cases. *Cranio.* 2010;28:136-40.
- Garcia-Gonzales D, Martin-Granizo R, Lopez P. Imaging quiz case 4. Bifid mandibular condyle. *Arch Otolaryngol Head Neck Surg.* 2000;126:795-9.
- Borrás-Ferreres J, Sánchez-Torres A, Gay-Escoda C. Bifid mandibular condyles: A systematic review. *Med Oral Patol Oral Cir Bucal.* 2018;23:e672-80.
- Cho BH, Jung YH. Nontraumatic bifid mandibular condyles in asymptomatic and symptomatic temporomandibular joint subjects. *Imaging Sci Dent.* 2013;43:25-30.
- Neves FS, Ramírez-Sotelo LR, Roque-Torres G, Barbosa GLR, Haiter-Neto F, de Freitas DQ. Detection of bifid mandibular condyle by panoramic radiography and cone beam computed tomography. *Braz J Oral Sci.* 2013;12:16-9.
- Shriki J, Lev R, Wong BF, Sundine MJ, Hasso AN. Bifid mandibular condyle: CT and MR imaging appearance in two patients: case report and review of the literature. *AJNR. Am J Neuroradiol.* 2005;26:1865-8.
- Plevnia JR, Smith JA, Stone CG. Bifid mandibular condyle without history of trauma or pain: report of a case. *J Oral Maxillofac Surg.* 2009;67:1555-61.
- Khojastepour L, Kolahi S, Panahi N, Haghnegahdar A. Cone Beam Computed Tomographic Assessment of Bifid Mandibular Condyle. *J Dent (Tehran).* 2015;12:868-73.
- Kaneda T, Torii S, Yamashita T, Inoue N, Shimizu K. Giant osteochondroma of the mandibular condyle. *J Oral Maxillofac Surg.* 1982;40:818-21.
- Neves SF, Ramirez-Sotelo LR, de Freitas DQ, Haiter-Neto F, Bóscolo FN. Cóndilo Mandibular Bífido: Un Desafío Diagnóstico. *Int J Odontostomat.* 2012;6:327-30.