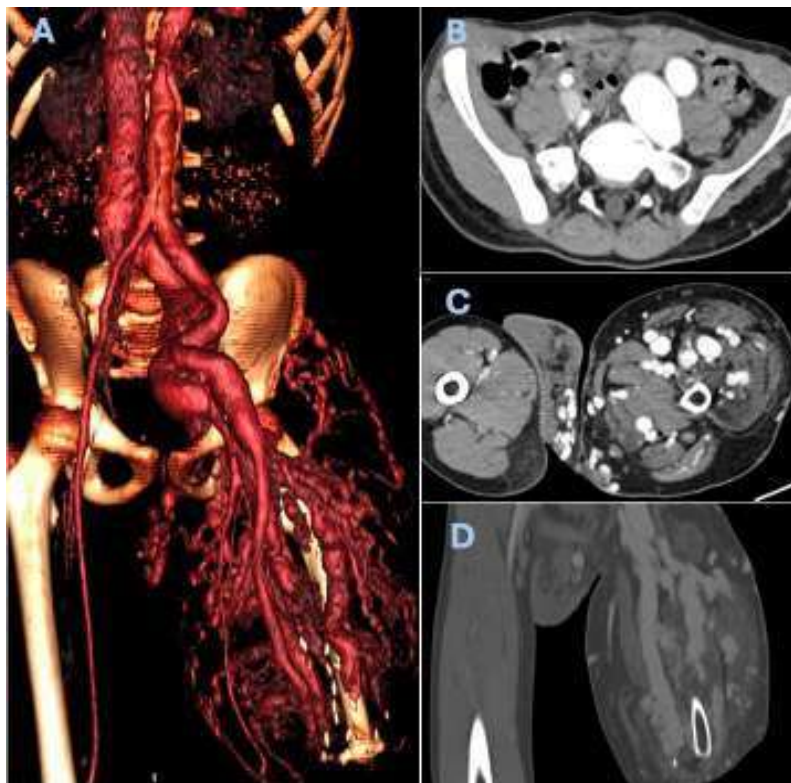


Life and limb-threatening PTEN-related arteriovenous malformation

Carolina Tavares , Rita Ferreira , Carlos Amaral 

Unidade Local de Saúde de São José – Hospital de Santa Marta, Serviço de Angiologia e Cirurgia Vascular, Lisboa, Portugal.

Submitted: November 7, 2025; Accepted: November 9, 2025



A 15-year-old male with a history of arteriovenous malformation (AVM) involving the left lower limb and pelvis, associated with a pathogenic PTEN gene mutation. A computed tomography angiography revealed hemihypertrophy of the left lower limb (A), significant dilation of the left iliac venous axis and inferior vena cava (B), with early opacification, and multiple venous dilations in the thigh and hemiscrotum (C, D). Additional findings included ectasia of the femoral and iliac arteries. Despite pharmacologic therapy, multiple embolisation procedures and transfemoral amputation, conducted in more than one centre (national and abroad), he developed a highly painful ulcer at the stump and high-output cardiac failure, so he was again referred to an international reference centre, where further lifesaving embolisation to achieve hip disarticulation

level was successfully performed. The postoperative course was favourable, with slow healing but reversal of cardiac insufficiency symptoms.

Acknowledgements: None

Conflicts of interest: None

Funding: None

Data availability: By request to authors

Ethics Approval: Not applicable

Informed Consent: No written informed consent was required due to the study design

Declaration of Generative AI and AI-Assisted Technologies in the Writing

Process: No generative AI or AI-assisted technologies were used in the writing process.

