

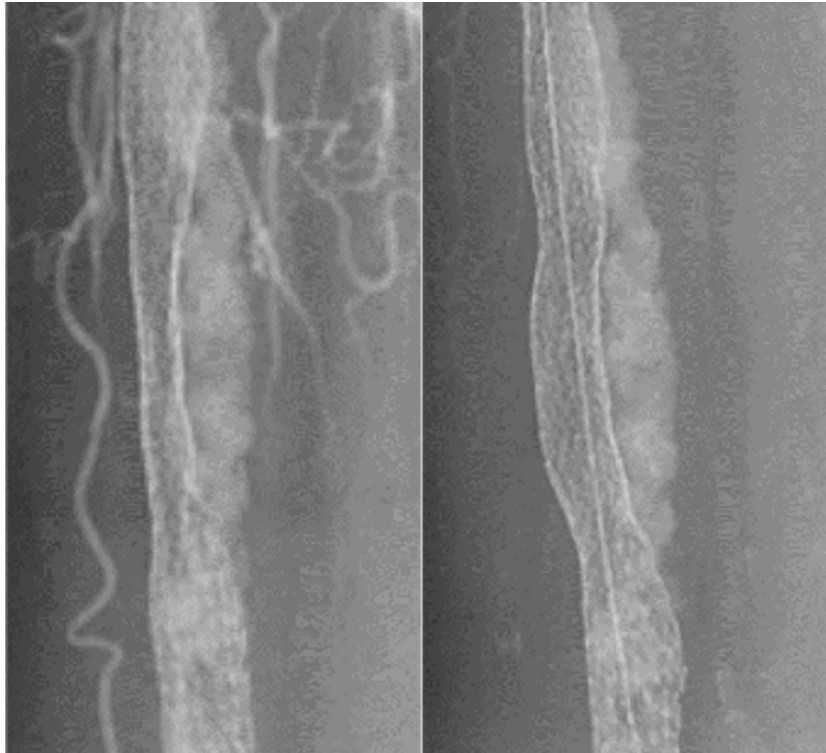
Shock it to expand it

Luís D. Fernandes^{a,b} , Diogo Silveira^{a,b}, Alexandra Canedo^{a,b} 

^aServiço de Angiologia e Cirurgia Vascular, Centro Hospitalar de Vila Nova de Gaia/Espinho

^bFaculdade de Medicina da Universidade do Porto

Submitted: May 18, 2025; Reviewed: May 26, 2025; Accepted: May 26, 2025



A 65-year-old male with Rutherford class 6 disease and multiple comorbidities underwent complex endovascular recanalisation (GLASS III, FP4, IP4) using the SAFARI technique. A bare metal self-expandable stent (BM-SES) 6.0 x 120 mm was implanted in the superficial femoral artery. Due to severe calcification, stent underexpansion persisted despite post-dilation at 30 atmospheres (left). Due to the immediate unavailability of alternative adjuncts, the patient was rescheduled. Four days later, intravascular lithotripsy with a 6.0 x 60 mm Shockwave™ IVL balloon (5 cycles at 4 atm, post-dilated to 6 atm) achieved optimal stent

expansion. Final angiography showed marked improvement without complications (right).

Acknowledgements: None

Conflicts of interest: None

Funding: None

Ethics Approval: Not applicable

Informed Consent: Written informed consent was obtained

Declaration of Generative AI and AI-Assisted Technologies in the Writing

Process: No generative AI or AI-assisted technologies were used in the writing process

Corresponding Author:

Luís Fernandes | luisdiogoffernandes@gmail.com

Serviço de Angiologia e Cirurgia Vascular do Centro Hospitalar de Vila Nova de Gaia/Espinho,
Rua Conceição Fernandes, s/n, 4434-502 Vila Nova de Gaia

Angiol Vasc Surg 2025;21(4):188

DOI: <https://doi.org/10.48750/acv693>

