Laparoscopic repair of post-hysterectomy vesicovaginal fistula

Correção laparoscópica de fístula vesico-vaginal pós-histerectomia

Sofia Saramago[1], Luísa Alves[2], José Reis[3], Bruno Graça[4]
Hospital Beatriz Ângelo

Abstract

Currently, in developed countries, vesicovaginal fistulas are mostly complications of gynecologic surgery. Laparoscopic vesicovaginal fistula repair has been reported with good results. We describe a technique to successfully repair, by laparoscopy, a vesicovaginal fistula following total laparoscopic hysterectomy for benign pathology. To our knowledge, this is the first reported case of vesicovaginal fistula repair using a laparoscopic technique in Portugal.

Keywords: Vesicovaginal fistula, Hysterectomy, Laparoscopy.

INTRODUCTION

A vesicovaginal fistula (VVF) is an abnormal communication between the bladder and the vagina, resulting in continuous leakage of urine through the vagina. VVF can have serious medical, psychological and social consequences.

In developing countries, prolonged obstructed labor without access to timely cesarean delivery is the main cause of VVF. In contrast, in developed countries obstetric fistulas are uncommon and VVF are usually sequelae of gynecologic surgery.

Although virtually any pelvic surgery can result in urogenital fistula formation[1], most surgical fistulas occur post-hysterectomy. Pelvic malignancy and radiotherapy may also cause VVF.

Laparoscopic VVF repair has been reported with good results. We describe the successful laparoscopic repair of a VVF following total laparoscopic hysterectomy for benign pathology. To our knowledge, this is the first reported case of laparoscopic VVF repair in Portugal.

1. Interna de Ginecologia e Obstetrícia do Hospital de Cascais Dr. José de Almeida
2. Interna de Urologia do Hospital Beatriz Ângelo
3. Assistente Hospitalar de Ginecologia e Obstetrícia do Hospital Beatriz Ângelo
4. Assistente Hospitalar de Urologia do Hospital Beatriz Ângelo

Case Report

A 41-year-old female underwent total laparoscopic hysterectomy as treatment for uterine leiomyomas and abnormal uterine bleeding.

She presented 11 days postoperatively with involuntary continuous leakage of urine.

On speculum examination urine was seen pooling in the vaginal fornix. Methylene blue was instilled into the bladder and dye was seen leaking through the left angle of the vaginal vault.

Computed tomography (CT) urography revealed an irregular air-liquid collection with contrast uptake adjacent to the vaginal cuff, apparently in communication with the vagina. It did not show contrast leaking from the ureters.

Cystoscopy showed a single supratrigonal fistula, medial to both ureteral orifices with approximately 10 mm.

It was decided to proceed with laparoscopic repair of the VVF, performed by Gynecology and Urology surgical teams. Surgery was scheduled 2 months after the hysterectomy, until then a Foley catheter was left in place.

Prior to laparoscopy, cystoscopy was performed.

Cystoscopy allowed to identify the fistula, which had diminished in size, and both ureteral orifices (Figure 1).

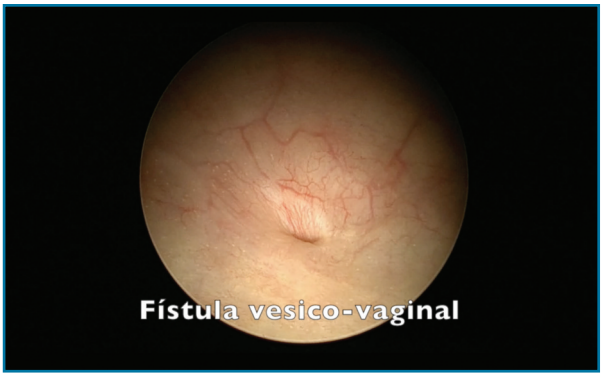

FIGURE 1. Cystoscopic view: vesicovaginal fistula

FIGURE 2. Cystoscopic view: clamp inserted through the vaginal orifice of the fistula and grasping a catheter that will mark the fistulous tract

Catheterization of the fistula tract was done to facilitate its identification during laparoscopic dissection. A clamp was placed through the vaginal orifice of the fistula; and through cystoscopy a catheter was introduced, grasped by the clamp and pulled into the vagina (Figure 2).

FIGURE 3. Cystoscopic view: catheters passing through the fistula (yellow) and right ureteral orifice (blue)

Retrograde pyelography was performed and documented ureteral integrity. Ureteral stents with different color from the catheter were placed bilaterally (Figure 3).

Laparoscopy revealed bowel loops adherent to the vaginal cuff and adhesiolysis was undertaken, exposing it (Figure 4).

An extravesical technique was used. The bladder was dissected off the vagina to the catheter marking the fistulous tract. This dissection was challenging due to the previous inflammatory process. The catheter was removed leaving separate vaginal and vesical defects. Dissection with adequate mobilization of tissue around both defects was done to allow their independent closure, without overlapping the sutures (Figures 5, 6, 7 e 8).

The edges of the vaginal defect were trimmed and closed with a 0 Vicryl® interrupted suture (Figure 9). The bladder was closed in two 00 Vicryl® layers, first a continuous running suture and a second invaginating

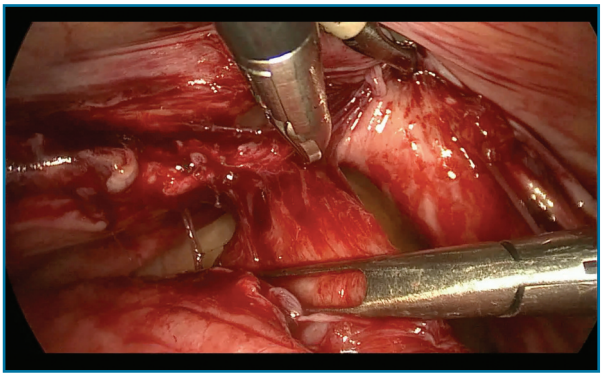

FIGURE 4. Laparoscopic view: lysis of adhesions between a bowel loop and the vaginal cuff

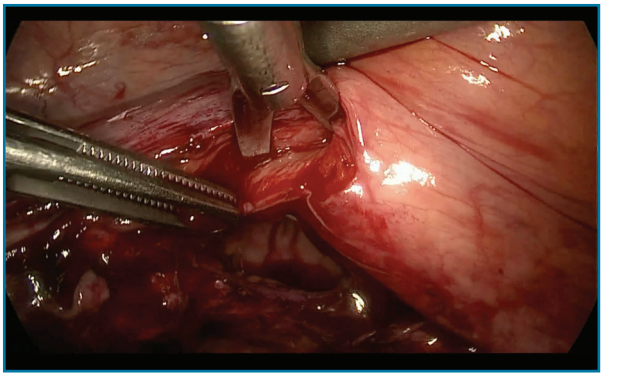

FIGURE 5. Laparoscopic view: dissection of the vesicovaginal space

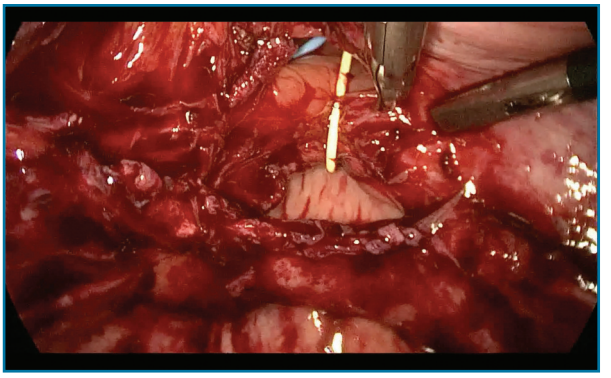

FIGURE 6. Laparoscopic view: yellow catheter marking the fistulous tract

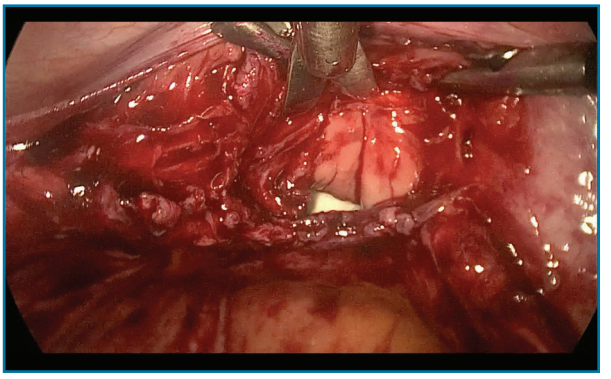

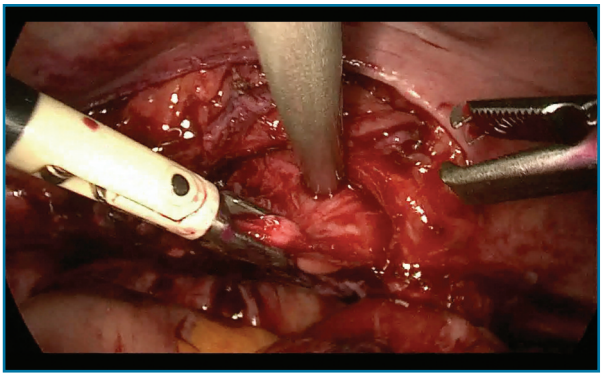

FIGURE 7 and 8. Laparoscopic view: further dissection of the vesicovaginal space after the catheter was removed

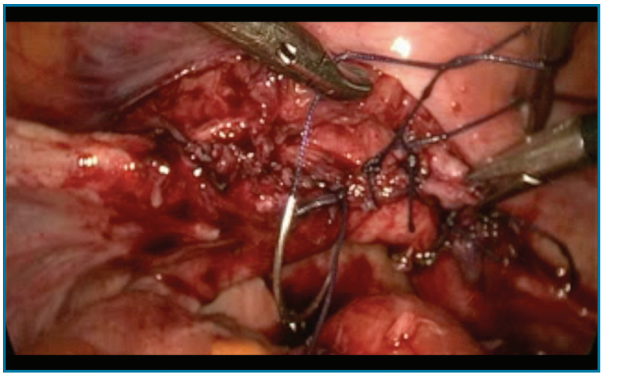

FIGURE 9. Laparoscopic view: suture of vaginal defect

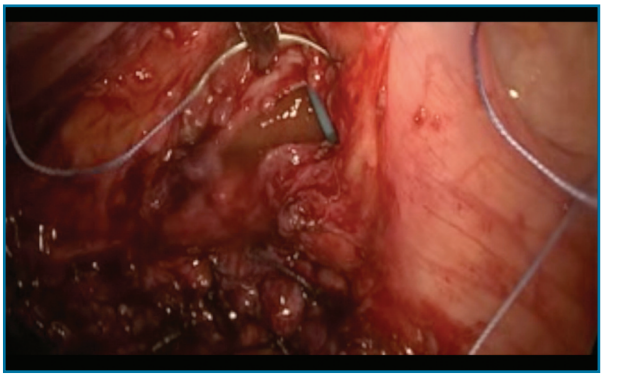

FIGURE 10. Laparoscopic view: suture of the vesical defect

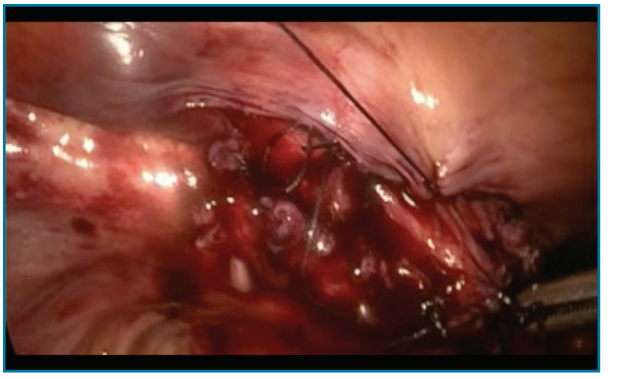

FIGURE 11. Laparoscopic view: Flap of anterior cul-de-sac peritoneum covering the cystorraphy

suture (Figure 10).

A peritoneal flap was added. Dissection was continued anteriorly to allow mobilization of the anterior cul-de-sac peritoneum that was brought over the cystorraphy, providing an additional barrier between the bladder and vaginal cuff (Figure 11).

Closure integrity was confirmed by retrogradely filling the bladder with methylene blue dye. As no ureteral injury occurred, stents were removed immediately.

There were no postoperative complications. The patient was discharged 2 days following surgery. A Foley catheter was left in place until postoperative day 14.

Six months after surgery, the patient had no complaints and there were no vaginal defects.

DISCUSSION

A large retrospective study in the United Kingdom showed an incidence of vesicovaginal or urethrovaginal fistula following hysterectomy of 0.13% (1/788). The incidence was highest following radical hysterectomy for cervical cancer (1/87) and lowest following vaginal hysterectomy for pelvic organ prolapse (1/3861). Total abdominal hysterectomy undertaken for fibroids, endometriosis and menstrual disorders resulted in an fistula rate of 1 in 540. For the same benign indications, the rate was 1/2279 for subtotal hysterectomy. This study did not discriminate abdominal hysterectomies performed through laparotomy or laparoscopy[2].

A Cochrane systematic review concluded that there are insufficient data to compare the risk of fistula following different types of hysterectomy for benign pathology (laparotomic, vaginal or laparoscopic)[3].

Compared to obstetric and radiotherapy-associated fistulas, post-hysterectomy fistulas often result from more circumscribed trauma to healthy tissue. While obstetric fistulas usually are more distal, larger and more frequently associated with urethral involvement, post-hysterectomy fistulas typically are located in the vaginal cuff, medial to both ureteral orifices, and above the vesical trigone.

VVF typically present with continuous vaginal urine leakage. This symptom can first appear 3 days to 8 weeks after hysterectomy[1].

Clinical diagnosis is often straightforward. Physical examination can be aided by various dye tests performed in the office. The number, dimension and location of the fistula(s) should be evaluated. Its relation to the urethra and tissue inflammation and fibrosis should also be noted.

Cystoscopy and imaging studies (retrograde pyelography, intravenous urography, CT urography) are useful to better characterize the fistula and to exclude upper urinary tract involvement.

Treatment of VVF includes both conservative and surgical options. Surgical treatment can be accomplished using different surgical approaches (vaginal, laparotomy, laparoscopy, robotic) and multiple surgical techniques. The lack of standardization regarding the techniques used, the outcomes measured and follow-up makes difficult the comparison of the different therapeutic options. The quality of evidence available is limited, consisting of case reports, case series and observational studies.

Spontaneous closure of VVF is possible, using only bladder drainage for variable periods, but the rate at which occurs is not established[4]. Conservative treatment can be considered in recent, small VVF.

Post-hysterectomy VVF have a good surgical prognosis. In a systematic review and meta-analysis of management of VVF following benign gynecologic surgery, most patients (1379/1430) were surgically treated, with a success rate of 97.98% (95%-CI: 96.13±99.29)[5]. The possibility of underreporting and selection bias should be considered.

Respecting some key surgical principles is essential to successfully repair VVF: adequate exposure and visualization of the surgical field, identification of the ureters, adequate dissection and mobilization of the vagina and bladder tissue before suturing their defects, tension-free multilayer suturing, confirmation of watertight closure and postoperative bladder drainage.

There is no agreement on several fundamental surgical aspects, as the ideal surgical timing, the best surgical approach, the use of interposition flaps, the need to excise the fistulous tract and the duration of postoperative urinary drainage.

Concerning optimal surgical timing, there is no proven benefit of delayed intervention. The moment of surgery should be tailored to the individual patient and surgery can be performed as soon as tissue inflammation, necrosis and infection have subsided[6].

In a systematic review and meta-analysis on the management of benign gynecological VVF, including a total of 1430 patients, similar high success rates were found for vaginal, laparotomic and laparoscopic/robotic repairs, respectively 93.82%, 97.05% and 98.87%[5]. No randomized controlled trials and no case-control studies have compared these approaches.

Abdominal repair can be open or laparoscopic/robotic and transvesical or extravesical techniques can be used.

Using the transvesical or O'Connor technique, the bladder is incised vertically at its dome down to the fistula tract. The bladder mucosa around the fistula is excised and the bladder is dissected off the vagina. The bladder and vagina are then closed in layers.

In the extravesical or intraperitoneal approach, there is no intentional cystotomy. Site-specific dissection is used to mobilize the bladder from the vagina and both defects are closed in layers.

Nezhat et al. first reported the laparoscopic repair of a VVF in 1994[7]. A systematic review of the literature found 256 cases of laparoscopic and robotic-assisted

VVF repair reported until 2014, 81% following hysterectomy (including for malignant disease), with success rates varying from 80-100%[8].

A variety of interposition flaps can be used in either abdominal or vaginal procedures, as an additional barrier, aiming to improve vascularization and lymphatic drainage. Such tissue flaps are often applied to recurrent, obstetric, radiotherapy-associated or large fistulas, although there is little evidence for their use in any of these specific situations. Labial fat pads (Martius flap) or peritoneal flaps are often applied in transvaginal repairs. In abdominal procedures, greater omentum is a popular graft source.

Both vaginal and abdominal techniques have an established role in VVF surgery.

Abdominal repair is preferred in high, fixed fistula, difficult to reach through the vagina or when there is the need of other simultaneous abdominal procedures, as augmentation cystoplasty or ureteral reimplantation.

As in many other settings, laparoscopy is being increasingly used as an alternative to laparotomy in fistula surgery, allowing magnified visualization and excellent exposure of the surgical field, with reduced postoperative pain and rapid recovery. Disadvantages include a steeper learning curve.

In this case, a laparoscopic extravesical site-specific dissection and layered-closure was chosen, using a peritoneal interposition flap, with good results.

There is no agreement on the best treatment approach to VVF. Existing data suggest comparable success rates for each technique but available evidence is of low quality. Management decisions are based primarily on the preference and expertise of the individual surgeon. Laparoscopic techniques are viable treatment options.

REFERENCES

1. Hilton P. Urogenital fistula in the UK: a personal case series managed over 25 years. BJU Int. 2012 Jul;110(1):102-110

2. Hilton P, Cromwell DA. The risk of vesicovaginal and urethrovaginal fistula after hysterectomy performed in the English National Health Service--a retrospective cohort study examining patterns of care between 2000 and 2008. BJOG. 2012 Nov;119(12): 1447-1454

3. Aarts JW, Nieboer TE, Johnson N, Tavender E, Garry R, Mol BW, Kluivers KB. Surgical approach to hysterectomy for benign gynaecological disease. Cochrane Database Syst Rev. 2015 Aug 12;(8):CD003677.

4. Bazi T. Spontaneous closure of vesicovaginal fistulas after bladder drainage alone: review of the evidence. Int Urogynecol J 2007;18:4.

5. Bodner-Adler B, Hanzal E, Pablik E, Koelbl H, Bodner K. Management of vesicovaginal fistulas (VVFs) in women following benign gynaecologic surgery: A systematic review and meta-analysis. PLoS One. 2017 Feb 22;12(2):e0171554.

6. De Ridder D. Committee 18 – Fistula. In: Abrams P, Cardozo L, Wagg A, Wein A, editors. Incontinence, 6th EDITION 2017. p. 2143-2202.

7. Nezhat CH, Nezhat F, Nezhat C, Rottenberg H. Laparoscopic repair of a vesicovaginal fistula: a case report. Obstet Gynecol. 1994 May;83(5 Pt 2):899-901.

8. Miklos JR, Moore RD, Chinthakanan O. Laparoscopic and Robotic-assisted Vesicovaginal Fistula Repair: A Systematic Review of the Literature. J Minim Invasive Gynecol. 2015 Jul-Aug; 22(5):727-736

ENDEREÇO PARA CORRESPONDÊNCIA

Sofia Saramago
Hospital de Cascais Dr. José de Almeida
Cascais, Portugal
E-mail: sofia.modesto.saramago@hospitaldecascais.pt

RECEBIDO EM: 14/02/2019
ACEITE PARA PUBLICAÇÃO: 09/03/2019