 DOI: 10.69729/aogp.v19i1a08

# Spontaneous postpartum rupture of an ovarian artery pseudoaneurysm: for a rare case, an effective treatment

# Rotura espontânea de um pseudoaneurisma da artéria ovárica no pós-parto: para um caso raro, um tratamento eficaz

Ana Beatriz De Almeida[1], Mariana Coroado[2], Carlos Fernandes Veiga[3], Cláudia Macário Lourenço[1,4], Márcia Barreiro[1,4]
Serviço de Ginecologia e Obstetrícia, Centro Materno-Infantil do Norte Albino Aroso, Unidade Local de Saúde de Santo António, Porto, Portugal
Serviço de Cirurgia Vascular, Unidade Local de Saúde de Santo António, Porto, Portugal

## Abstract

Spontaneous rupture of an ovarian artery aneurysm or pseudoaneurysm (OAA) is a rare, life-threatening cause of retroperitoneal hemorrhage. We present a patient with an undiagnosed left ovarian pseudoaneurysm that ruptured two days after an uneventful vaginal delivery. This condition was initially masked by typical puerperal changes and postpartum complications, however, an urgent transcatheter arterial embolization (TAE) led to a successful outcome. This case report and a literature review highlight the need for awareness of ruptured OAA in the differential diagnosis of severe abdominal pain after childbirth, especially in high-parity women, to improve maternal and perinatal outcomes.

**Keywords:** Ovarian artery pseudoaneurysm; Retroperitoneal hemorrhage; Postpartum; Angiography; Transcatheter arterial embolization.

## Resumo

A rotura espontânea de um aneurisma ou pseudoaneurisma da artéria ovárica (AAO) é uma causa rara e potencialmente fatal de hemorragia retroperitoneal. Apresentamos o caso de uma paciente com rotura de um pseudoaneurisma da artéria ovárica esquerda, dois dias após um parto vaginal normal. O quadro clínico foi inicialmente mascarado por alterações fisiológicas típicas e potenciais complicações puerperais, porém uma embolização transarterial (ET) atempada resultou num desfecho favorável. Com este caso clínico e após uma revisão da literatura, podemos concluir que o diagnóstico de rotura de AAO, embora difícil, deve ser considerado no diagnóstico diferencial em mulheres com dor abdominal intensa no periparto, especialmente em grandes multíparas, de forma a melhorar os desfechos maternos e perinatais.

**Palavras-chave:** Pseudoaneurisma da artéria ovárica; Hemorragia retroperitoneal; Período de pós-parto; Angiografia; Embolização transarterial.

## INTRODUCTION

The spontaneous rupture of an OAA is a rare condition with a significant risk of life-threatening retroperitoneal hemorrhage. Over half of ruptured OAA among young women occur during pregnancy, mainly in the peripartum or postpartum periods. Despite its clinical significance, its true incidence remains unknown, as current knowledge is based on limited cases[1,2].

The clinical presentation often mimics mild conditions or physiologic changes of peripartum status,

potentially delaying diagnosis and leading to adverse outcomes. A high index of suspicion, along with early diagnosis and treatment, becomes essential to optimize the survival rates for both the patient and newborn in antepartum-related cases[2].

In this context, we report and discuss the management of a postpartum patient with retroperitoneal hemorrhage following spontaneous rupture of a left ovarian artery (LOA) pseudoaneurysm. The patient was successfully treated with TAE, marking the 31st pregnancy-related case reported in English literature since 1963[3].

## CASE REPORT

A 27-year-old Caucasian woman, gravida 3 para 2, was admitted at 38 weeks and 5 days of gestation for spontaneous labor. She delivered a male newborn weighing 2720 grams through uncomplicated vaginal delivery. Her medical records included Hashimoto's thyroiditis, with no previous surgeries. The pregnancy was uneventful, aside from asymptomatic multiresistant *Escherichia Coli* bacteriuria at admission. Piperacillin-tazobactam was initiated in the immediate postpartum period.

On the 2nd postpartum day, the patient developed acute, severe left-sided flank pain, oliguria, and hypotension (70/50 mmHg). Physical examination revealed pallor, left-sided abdominal and lumbar pain, and abdominal distension unresponsive to analgesia.

Initial laboratory tests revealed a hemoglobin drop from 11 g/dL in late pregnancy to 9.3 g/dL, suggesting mild postpartum anemia. A renal-bladder ultrasound and an abdominal X-ray imaging (Figure 1) were performed, excluding urinary and intestinal complications. Persistent pain along with an episode of lipothymia prompted an urgent abdominopelvic contrast-enhanced CT-scan, revealing a 19 cm retroperitoneal hematoma in the left flank and iliac fossa (Figure 2). Additionally, a 7 mm pseudoaneurysm in the LOA was identified as the source of intermittent hemorrhage (Figure 3A).

**FIGURE 1.** Abdominal X-ray performed due to suspected intestinal obstruction, revealing displaced and distended intestinal loops with obscuration of the psoas muscle contour. These findings are nonspecific and have low sensitivity for detecting retroperitoneal hemorrhage, notably in low- to moderate-volume hematomas.

Hemoglobin dropped to 5.2 g/dL within a few hours, and the patient was transferred to the ICU to immediate resuscitation with 1 L crystalloid, 1 gram of tranexamic acid, and 3 units of red blood cells. After consultation with the vascular surgical team, the patient was taken to the Angio-Suite for urgent TAE. Approaching the common femoral artery, the LOA was selectively catheterized, and a diagnostic angiography confirmed the pseudoaneurysm (Figure 3B), with active bleeding at its proximal segment. Embolization of the proximal LOA was performed with 3.0- and 4.0-mm micro-coils. In attempting to microcatheterize the distal LOA, a new bleeding episode was identified, requiring additional embolization with thrombin and a 6.0-mm micro-coil (Figure 4A). Post-embolization angiography of the left hypogastric and common

1. Serviço de Ginecologia e Obstetrícia, Departamento da Mulher e Medicina Reprodutiva, Centro Materno-Infantil do Norte Albino Aroso, Unidade Local de Saúde de Santo António, Porto, Portugal.
2. Serviço de Ginecologia e Obstetrícia, Unidade Local de Saúde de Entre Douro e Vouga, Santa Maria da Feira, Portugal.
3. Serviço de Angiologia e Cirurgia Vascular, Unidade Local de Saúde de Braga, Braga, Portugal.
4. Centro de Procriação Medicamente Assistida (CPMA), Centro Materno-Infantil do Norte Albino Aroso, Unidade Local de Saúde de Santo António, Porto, Portugal.

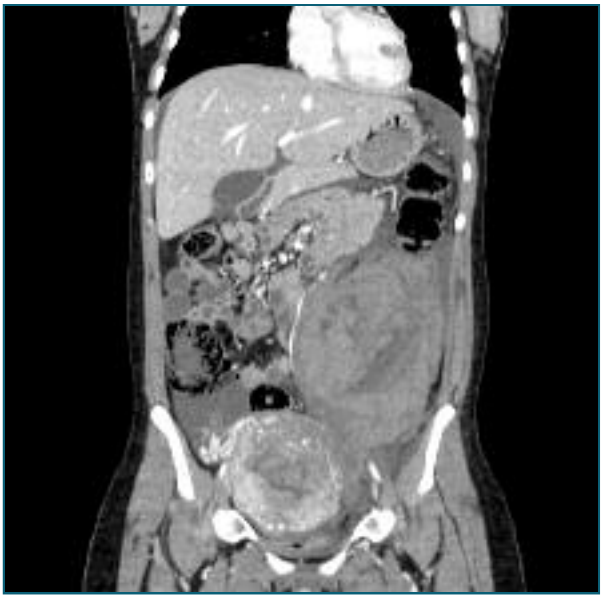

**FIGURE 2.** Abdominal-pelvic CT scan performed 2 days postpartum, showing a retroperitoneal hematoma measuring at least 12 × 13.4 × 19 cm (anteroposterior × transverse × longitudinal), localized in the left flank and iliac fossa. An enlarged uterus with a heterogeneous enhancement pattern results from normal postpartum changes.

iliac arteries confirmed successful occlusion of LOA. (Figure 4B). Post-TAE, the patient was transfused an additional unit of erythrocytes, achieving a hemoglobin level of 8.5 g/dL. The patient had an uneventful recovery and was discharged within 5 days.

By the 4th week postpartum, the patient presented a normal-ranged hemoglobin level (12.1 g/dL) with a normal physical examination. The patient underwent a multidisciplinary follow-up which included gynecology, internal medicine, genetics, and vascular surgery. At 6 months postpartum, a Next Generation Sequencing panel ruled out any causal variants of connective tissue disorders. Sequential CT-scans revealed retroperitoneal hematoma regression from 97 mm to 52 mm at 3 and 8 months postpartum, with complete resolution by 23 months (Figure 5). The patient remains under gynecological follow-up, being asymptomatic since post-TAE discharge.

## DISCUSSION

Acute retroperitoneal hemorrhage is a critical situation that may arise from various conditions, including

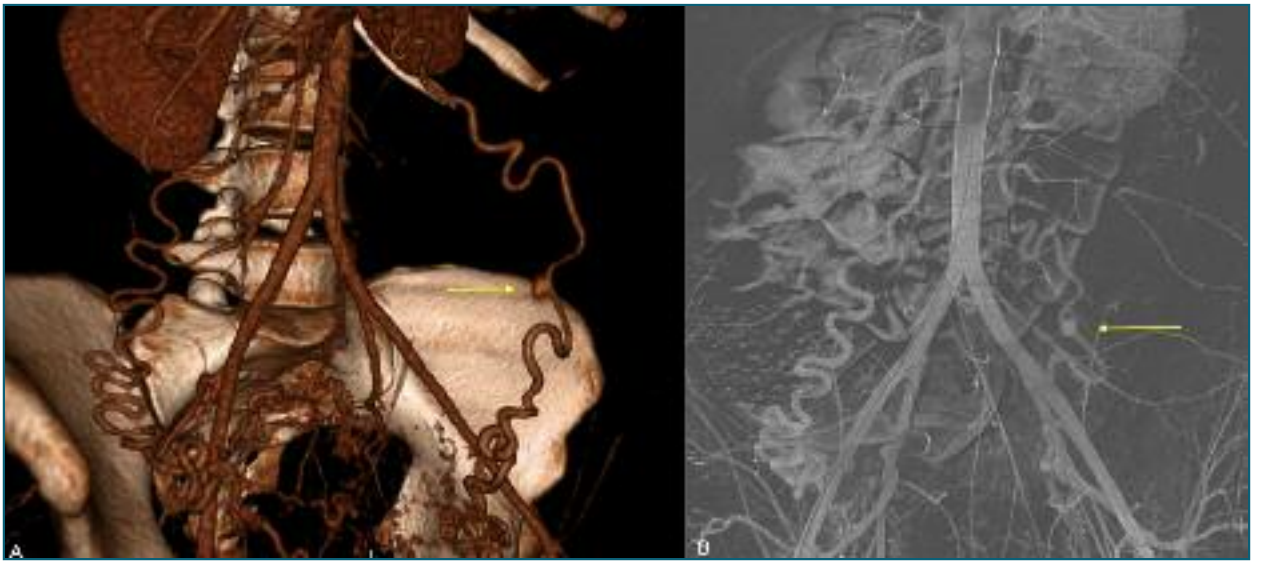

**FIGURE 3.** **(A)** Three-dimensional CT scan reconstruction showing a 7 mm saccular structure in the LOA, consistent with an ovarian artery pseudoaneurysm. No active bleeding was observed at the time of image acquisition, though intermittent hemorrhage was suspected; **(B)** Diagnostic angiography confirming the OAA in the LOA with active bleeding proximally to the pseudoaneurysm. The yellow arrows represent the OAA identified in both imaging diagnostic tools.

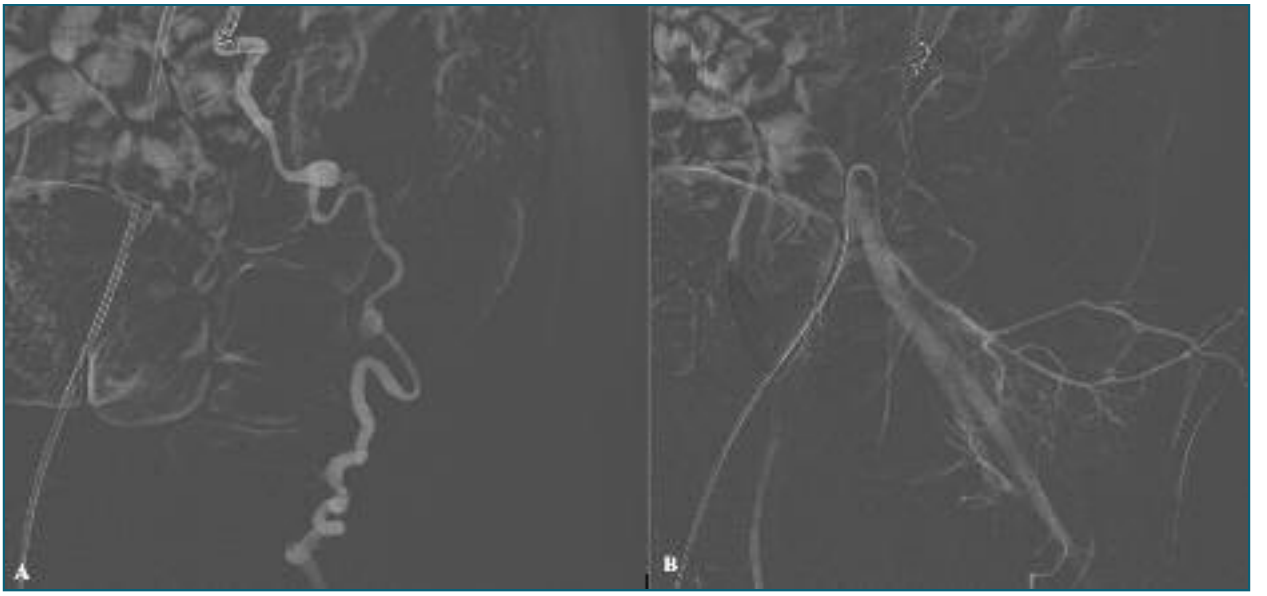


**FIGURE 4.** **(A)** Using a Cobra catheter via the common femoral artery, the proximal segment of the LOA was accessed and embolization with micro-coil was performed (MReye® coils, 3.0- and 4.0-mm). Due to contrast leakage after catheterization of the distal LOA, additional embolization with thrombin and a 6.0-mm micro-coil was performed. **(B)** Post-embolization control angiography through the left hypogastric and left common iliac arteries showed no evidence of active bleeding, confirming successful occlusion of the LOA.

**FIGURE 5.** Complete spontaneous resolution of the retroperitoneal hematoma after 23 months of postpartum and post-TAE, with neither early nor long-term complications reported.

iatrogenic (e.g abdominal trauma, surgical interventions) and spontaneous causes of arterial rupture, generally due to oncological or vascular disorders[1]. Arterial aneurysms and pseudoaneurysms are recognized causes, both distinguished by vessel wall integrity. Regarding pseudoaneurysms, the vessel's wall becomes disrupted, potentially leading to the formation of periarterial hematomas and subsequent significant hemorrhage. Although vascular rupture has been documented in postmenopausal women, most cases occur during pregnancy or the peripartum period. The affected vessels often include the aorta, splenic, and renal arteries[1,4]. Since the first documented case of pregnancy-related OAA rupture in 1963, only 30 other cases, including ours, have been reported[1-4]. Pseudoaneurysms are even rarer than OAA, making this case of particular interest.

A literature review of pregnancy-related OAA rupture cases, summarized in Table I, shows a median patient's age of 35 years (±4.4 years), with most being multiparous. Eighty-seven percent of cases occurred postpartum, with a mean onset of symptoms on the 4$^{th}$ day. Only 3 postpartum cases followed cesarean

**TABLE I. REPORTED 31 CASES OF PREGNANCY-RELATED SPONTANEOUS RUPTURE OF THE OVARIAN ARTERY[1,5-8,14,11-20].**

| Age (y) | Parity | Side | Onset | Type of delivery | Presenting symptoms | Treatment | Author, year |
|---|---|---|---|---|---|---|---|
| 29 | 4 | L | 2d PP | VD | Flank pain; Dizziness | Laparotomy (SO) | *Caillouette and Owen, 1963* |
| 35 | 3 | L | 3d PP | VD | Abdominal pain radiating to lumbar region and right shoulder; Nausea | Laparotomy (SO) | *Tsoutsoplides, 1967* |
| 38 | 6 | R | Delivery | VD | Abdominal pain; Dizziness | Laparotomy (Ovarian AL) | *Riley, 1975* |
| 32 | 3 | R | 4d PP | VD | Lipothymia | Laparotomy (AR) | *Burnett and Carfrae, 1976* |
| 26 | 4 | R | 1d PP | VD | Lower abdomen and flank pain | Laparotomy (SO) | *Jafari and Saleh, 1977* |
| 23 | n/a | R | 1mo PP | VD | Lumbar and flank pain | Laparotomy (AL, SO and hysterectomy) | *Mojab and Rodriguez, 1977* |
| 31 | 3 | R | 39w | CS | Abdominal pain; Lipothymia | Laparotomy (during CS – AL) | *Høgdall et al., 1989* |
| 36 | 5 | R | 4d PP | VD | Flank pain | TAE | *King, 1990* |
| 38 | 2 | R | Delivery | VD | Flank pain | Laparotomy (n/a) | *Belfort et al., 1993* |
| 38 | 2 | R | 6d PP | VD | Lower abdomen and flank pain; Ileus | TAE → lomboscopic drainage | *Guillem et al., 1999* |
| 38 | 11 | R | 3d PP | VD | Lower abdomen and flank pain | Laparotomy (AR) | *Blachar et al., 2000* |
| 37 | 4 | L | 38w+1d | CS | Abdominal pain; Dyspnea | Laparotomy (during CS – Hematoma Evacuation and Vascular Sutures) | *Panoskaltsis et al., 2000* |
| 30 | 5 | L | 5h PP | VD | Abdominal pain; Nausea; Vomiting | Laparotomy (n/a) | *Kale et al., 2005* |
| 39 | 4 | R | 5d PP | VD | Abdominal pain | TAE | *Poilblanc et al., 2008* |
| 30 | n/a | R | 12d PP | VD | Flank pain; Flank mass | TAE | Schouwenburg, 2011 |
| 32 | 4 | L | 2d PP | VD | Abdominal pain | Laparotomy (Exploratory) → TAE | *Mohammed et al., 2011* |
| 31 | 4 | L | 2d PP | VD | Abdominal pain | TAE | *Sakaguchi et al., 2015* |
| 35 | 3 | L | 3d PP | VD | Abdominal pain | Laparotomy (SO) → TAE | *Ola et al., 2015* |
| 37 | 4 | L | 4d PP | VD | Abdominal pain | TAE | *Wakimoto et al., 2015* |
| 38 | 5 | L | 4d PP | VD | Abdominal pain; Weakness; Dizziness | TAE → laparotomy (Hematoma Evacuation) | *Enakpene et al., 2016* |
| 39 | 8 | L | 1d PP | VD | Lower abdominal pain; Dizziness | TAE | *Garg et al., 2016* |
| 31 | 5 | R | 5d PP | VD | Lower abdomen and flank pain | TAE | *Stanborough et al., 2017* |
| 34 | 4 | R | 7d PP | CS | Abdominal and flank pain; Lipothymia | TAE | *Horwitz et al., 2019* |
| 38 | 3 | R | 4d PP | CS | Flank pain; Fever | TAE | *Yin et al., 2020* |
| 32 | 5 | R | 5h PP | VD | Hypotension | Laparotomy (Exploratory) → TAE | *Arleo et al., 2022* |
| 28 | 3 | L | 3d PP | VD | Flank pain | TAE | *Arleo et al., 2022* |
| 41 | 2 | R | 4d PP | CS | Lower abdomen and flank pain | TAE | *Shibahara et al., 2022* |
| 35 | 7 | R | 3d PP | VD | Lower abdomen and flank pain; Weakness; Dizziness | Laparotomy (Exploratory) → 2nd laparotomy (Hematoma Evacuation and AL) | *Rasti et al., 2023* |
| 37 | 4 | R | 6h PP | VD | Flank pain | TAE | *Van Kalsbeek et al., 2023* |
| 34 | 6 | R | 2d PP | VD | Abdomen pain and distension; Hypotension; Tachycardia | Laparotomy (Ovarian AL) → TAE | *Speier L et al., 2024* |
| 27 | 3 | L | 2d PP | VD | Flank pain; Hypotension; Oliguria | TAE | *Our case* |

Abbreviations: AL – Artery ligation; AR – Aneurysm resection; CS – Cesarean Section; d – days; h- hours; L – Left; M – Multiparous; mo – months; n/a – not available; PP – Postpartum R – Right; SO – Salpingo-oophorectomy; VD – Vaginal Delivery; w – weeks; y – years.

sections, and 61% of OAA ruptures were right-sided. This higher frequency of right OAA may be due to anatomical variations during pregnancy, as the uterus tends to deviate to this side[5].

Spontaneous peripartum hemorrhage from ruptured OAA mostly affects multiparous women, with pregnancy-related hemodynamic, anatomical, and hormonal changes playing a significant role in its pathophysiology[6]. Increased plasma volume and cardiac output, along with decreased vascular resistance, enhances utero-ovarian perfusion, predisposing ovarian vessels to vascular remodeling. Following uterine involution after childbirth, these vessels may become distorted as they regress, raising the risk of aneurysm formation and rupture[4]. Moreover, the increased circulatory sex steroids promote fragmentation of arterial elastic fibers and damage of the intimal layer, raising this risk with repeated pregnancies[5-7]. The link between delivery mode and OAA rupture remains unclear, though hormonal changes and expulsive efforts during delivery may explain its higher frequency among vaginal births[5]. Additional risk factors like uterine fibroids, hypertension, and connective tissue disorders (e.g. Marfan and Ehlers-Danlos Syndromes) were excluded in our case[4]. These findings emphasize the complexity of physiological changes in pregnancy. Therefore, the implementation of a preconception cardiovascular assessment and monitoring protocol could be beneficial in high-parity women. Currently, there are no established guidelines for managing asymptomatic OAAs, with recommendations based on limited reported cases[8]. However, secondary prevention strategies may include surgical correction before or during pregnancy, controlling blood pressure in cases of chronic or gestational hypertension, and promoting weight loss and smoking cessation[9].

Typical presentation of ruptured OAA includes acute lower abdominal or flank pain, commonly seen in the reported cases (Table I). In situations of substantial retroperitoneal hemorrhage, clinical signs of hypovolemic shock may appear[6]. Therefore, the initial workup includes the evaluation of vital signs and physical examination, focusing on vaginal bleeding and abdominal findings. Due to its rarity, differential diagnosis barely considers the rupture of abdominal vessels. Their nonspecific symptoms may be easily mistaken with common postpartum conditions such as gastrointestinal and urinary tract disorders, delaying its recognition[1,4]. Its challenging nature was exemplified in our reported case, requiring a systematical workup to rule out the more frequent causes before establishing the final diagnosis. An abdominal CT scan is generally performed for diagnosis at admission, although ultrasound is an alternative approach for pregnant women. Selective angiography, however, remains the gold standard for identifying the bleeding source[4,5].

There is no established treatment algorithm for OAA rupture cases, and both TAE and surgical interventions can be considered based on the patient's hemodynamic stability, gestational age if applicable, and professional's expertise[4]. TAE was performed in 61% of the reported cases, becoming the preferred approach in stable patients since its first use in 1990[1]. Either treatment proved to be successful, with cessation of intraperitoneal bleeding in all patients. The average length of hospital stay was 8 and 14 days after TAE and surgery, respectively. In the literature, both laparotomy and TAE show similar mortality rates, although TAE is favored for its minimally invasive nature, resulting in reduced postoperative pain, fewer complications, and faster recovery[4,10]. A wide range of embolic agents is available for TAE, including temporary (e.g. gelatin sponge particles, thrombin), and permanent agents (e.g. micro-coils, glue, N-butyl cyanoacrylate). Each embolic agent has distinct properties suited to specific clinical scenarios, and experienced vascular teams become essential to select the most appropriate one according to the patient's comorbidities and desired outcome[10]. Nevertheless, surgical interventions including salpingo-oophorectomy, ovarian artery ligation, or aneurysm resection remain viable options in case of embolization failure, patient's instability or limited access to interventional radiology[4,5].

Despite its benefits, selective TAE is not risk-free. Complications such as systemic thromboembolism, intraoperative arterial rupture, and non-target organ infarction, although infrequent, must be considered. Moreover, TAE does not allow hematoma evacuation, so close monitoring for pain and infection on residual hematomas is needed[5,7,10]. Despite the need for hematoma evacuation due to persistent pain in 2/19 cases (10.5%), the only short-term complication post-TAE

registered was a pulmonary embolism after 11 days[2,5]. Of the two antepartum cases registered, emergent cesarean sections were performed, and one neonatal death occurred[11,12]. Most cases lacked long-term follow-up: one reported a subsequent pregnancy 3 months post-TAE, and those with follow-up up to one year showed no complications[5,6,13-15]. Our case stands out in the literature presenting more than 2 years of follow-up, without any complications recorded.

Regarding future fertility, current literature focuses only on non-target ovarian embolization following uterine TAE. Studies report a decrease on ovarian reserve in women over 40 years-old, but no impact was shown in younger ages[16]. Hence, concerns about ovarian ischemia or infarction post-TAE remain poorly understood and in need of primary research.

## CONCLUSION

This case illustrates the need for prompt diagnosis of spontaneous OAA rupture. Although rare, especially for pseudoaneurysms, its presentation during pregnancy or the peripartum period may be masked by other common conditions, misleading the diagnosis. Awareness, particularly in high-parity women, is essential for timely recognition and treatment. While TAE appears effective, its short- and long-term effects, notably on fertility, need to be clarified. Furthermore, limited access to interventional radiology in smaller centers may affect optimal patient care. These challenges emphasize the need for ongoing research into OAA treatment and the establishment of standardized clinical management among affected patients.

### REFERENCES

1. Toyoshima M, Kudo T, Igeta S, Makino H, Momono Y, Shima T, Matsuura R, Ishigaki N, Akagi K, Takeyama Y, Iwahashi H, Rikimaru H, Sato A, Yoshinaga K. Spontaneous retroperitoneal hemorrhage caused by rupture of an ovarian artery aneurysm: a case report and review of the literature. J Med Case Rep. 2015 Apr 18; 9:84. doi: 10.1186/s13256-015-0553-4.

2. Enakpene CA, Stern T, Barzallo Salazar MJ, Mukherjee P. Spontaneous Rupture of an Ovarian Artery Aneurysm: A Rare Postpartum Complication. Case Rep Obstet Gynecol. 2016 Feb 29: 1029561. doi: 10.1155/2016/1029561.

3. Caillouette JC, Owen HW. Postpartum spontaneous rupture of an ovarian-artery aneurysm. Obstet Gynecol. 1963 Apr; 21:510--511. PMID: 14017734.

4. Nguyen KT, Henken-Siefken A, Fincher R, McCague A. Spontaneous Rupture of a Right Gonadal Artery Aneurysm: A Case Report. Cureus 2024;16(3): e57352. doi.org/10.7759/cureus.57352.

5. Guillem P, Bondue X, Chambon JP, Lemaitre L, Bounoua F. Spontaneous retroperitoneal hematoma from rupture of an aneurysm of the ovarian artery following delivery. Ann Vasc Surg. 1999 Jul;13(4):445-448. doi: 10.1007/s100169900281.

6. Sakaguchi I, Ohba T, Ikeda O, Yamashita Y, Katabuchi H. Embolization for post-partum rupture of ovarian artery aneurysm: Case report and review. J Obstet Gynaecol Res. 2015;41(4):623-627. https://doi.org/10.1111/jog.12561.

7. Wakimoto S, Hidaka N, Fukushima K, Kato K. Spontaneous post-partum rupture of an ovarian artery aneurysm: A case report of successful embolization and a review of the published work. J Obstet Gynaecol Res. 2015 Mar; 41(3):456-459. doi: 10.1111/jog.12535.

8. Garg D, McLaren RA, Silverman M. Postpartum Retroperitoneal Hematoma due to Spontaneous Rupture of Ovarian Artery Pseudo-Aneurysm. Obstet Gynecol Int J. 2016;5(6):437-439. doi: 10.15406/ogij.2016.05.00181.

9. la Chapelle CF, Schutte JM, Schuitemaker NW, Steegers EA, van Roosmalen J; Dutch Maternal Mortality Committee. Maternal mortality attributable to vascular dissection and rupture in the Netherlands: a nationwide confidential enquiry. BJOG. 2012 Jan;119(1):86-93. doi: 10.1111/j.1471-0528.2011.03178.x.

10. Obara H, Kentaro M, Inoue M, Kitagawa Y. Current management strategies for visceral artery aneurysms: an overview. Surg Today. 2020 Mar;50(3):320. doi: 10.1007/s00595-019-01947-x.

11. Panoskaltsis T, Padwick M, Thomas JM, El Sayed T. (2000), Spontaneous rupture of ovarian arterial aneurysm in the antenatal period. Acta Obstet Gynecol Scand. 2000; 79: 718-719. doi: 10.1034/j.1600-0412.2000.079008718.x.

12. Høgdall CK, Pedersen SJ, Øvlisen BØ, Helgestrand UJV. Spontaneous Rupture of an Ovarian-Artery Aneurysm in the Third Trimester of Pregnancy. Acta Obstet Gynecol Scand. 1989,68: 651-652. Doi: 10.3109/00016348909013287.

13. Ola PK, Nath RK, Pandit N. Successful Management of a Rare Case of Ruptured Ovarian Artery Aneurysm by Coil Embolization. J Obstet Gynaecol India. 2015 Dec; 65(6):423-5. doi: 10.1007/s13224-014-0613-5.

14. Arleo TL, Peters GL, Kokabi N, Majdalany BS. Peripartum hemorrhage: Two cases of ruptured ovarian artery aneurysms with additional multifocal intact aneurysms. J Clin Imaging Sci. 2022 Mar 16;12:10. doi: 10.25259/JCIS_145_2021.

15. Mojab K, Rodriguez J. Postpartum ovarian artery rupture with retroperitoneal hemorrhage. AJR Am J Roentgenol. 1977 Apr;128(4):695-6. doi: 10.2214/ajr.128.4.695.

16. Czuczwar P, Stepniak A, Wrona W, Wozniak S, Milart P, Paszkowski T. The influence of uterine artery embolisation on ovarian reserve, fertility, and pregnancy outcomes – a review of literature. Prz

Menopauzalny. 2016 Dec;15(4): 205-209. doi: 10.5114/pm.2016.65665.

17. Shibahara M, Kondo E, Shibata E, Uchimura T, Kinjo Y, Murakami M, Fukumitsu S, Anai K, Ishikawa S, Yoshino K. Spontaneous postpartum rupture of an ovarian artery aneurysm treated with embolization: A case report and review of the literature. Authorea. 2022 Feb. doi: 10.22541/au.164479023.38654138/v1.

18. Rasti S, Zarean E, Jafarpisheh MS, Aria A. Preventing thrombotic events in a case of postpartum ovarian artery aneurysm rupture: clinical challenges and management approaches. J Surg Case Rep. 2023 May; 2023(5): rjad282. doi: 10.1093/jscr/rjad282.

19. Van Kalsbeek MB, Morris K, Degen K. Ruptured Ovarian Artery Aneurysm Complicating a Term Vaginal Delivery in the Early Puerperium Period: A Case Study. S D Med. 2023 Apr;76(4): 156-159. PMID: 37566669.

20. Speier L, Ward T, Bednar J, Kramer N, Almario L. Spontaneous Rupture of an Ovarian Artery Aneurysm in the Early Postpartum Period: A Case Report. Cureus 2024 Jul; 16(7): e65137. doi:10.7759/cureus.65137.

## AUTHORS' CONTRIBUTIONS

**AB De Almeida:** Substantial contributions to conception and design, data collection, analysis and interpretation of data; Article writing, reviewing and final editing. **M Coroado:** Contributions to data collection, critical review of article content; Final approval of the version to be published. **CF Veiga:** Critical review of article content; Final approval of the version to be published. **CM Lourenço:** Final approval of the version to be published. **M Barreiro:** Final approval of the version to be published.

## CONFLICT OF INTEREST

The authors declare no conflict of interest.

## PATIENT'S INFORMED CONSENT

The patient provided written informed consent for publication.

## CORRESPONDENCE TO:

Ana Beatriz De Almeida
E-mail: anabeatriz29@gmail.com
https://orcid.org/0000-0002-7898-5132

**RECEIVED:** 07/11/2024
**ACCEPTED:** 15/12/2024