

## ARP Case Report n° 30: What is your diagnosis?

*Caso Clínico ARP n° 30: Qual o seu diagnóstico?*

Nuno Lupi Manso<sup>1</sup>, José Laert<sup>1</sup>, Tomás França de Santana<sup>1</sup>, Sofia Freitas<sup>1</sup>, Luís Gargaté<sup>1</sup>

<sup>1</sup>Serviço de Radiologia, Hospital CUF Tejo, Lisboa, Portugal

### Case Presentation

A 73-year-old man with no relevant past medical history and with complaints of asthenia, fever and weight loss over the past few months was referred for abdominal computer

tomography after an incidental adrenal mass was detected on abdominal ultrasound. What is the diagnosis?

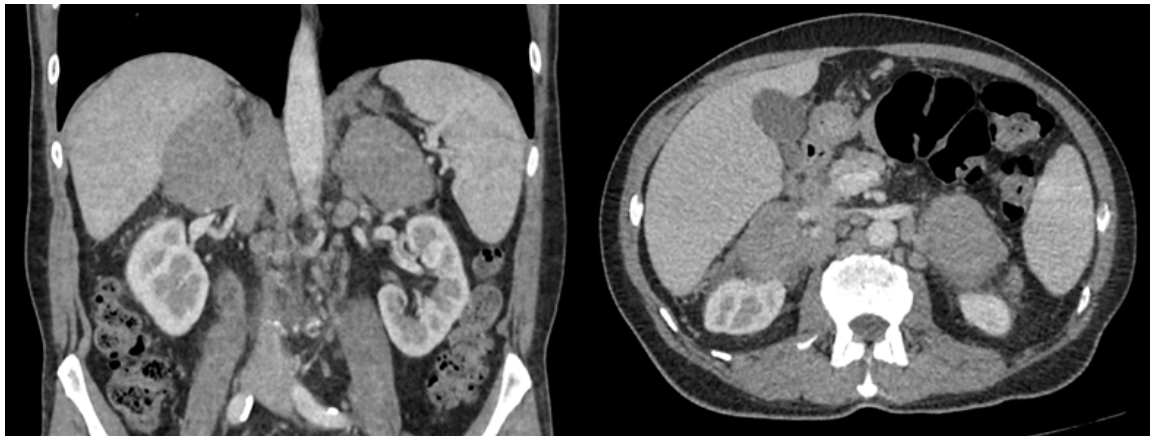


Figure 1 - Coronal and axial slices, soft-tissue window, 1.25 mm thickness, contrast-enhanced CT.

Send your answer containing the diagnosis (s) to the email address [actarp.on@gmail.com](mailto:actarp.on@gmail.com).  
The names of the authors of the correct answers will be published in the next issue of the ARP in the case solution.