

Cytomegalovirus Disease of the Upper Gastrointestinal Tract: A 10-Year Retrospective Study

Susana Marques^a Joana Carmo^a Daniel Pinto^b Miguel Bispo^a
 Sância Ramos^b Cristina Chagas^a

Departments of ^aGastroenterology and ^bPathology, Hospital de Egas Moniz, Centro Hospitalar Lisboa Ocidental, Lisbon, Portugal

Keywords

Cytomegalovirus · Esophagitis · Gastritis · Endoscopy

Abstract

Background and Aims: Cytomegalovirus (CMV) disease of the gastrointestinal (GI) tract is a major cause of morbidity and mortality in immunocompromised patients. The colon is the most commonly affected site, and the literature is scarce regarding CMV disease of the upper GI tract. Therefore, our study aimed to evaluate the clinical and endoscopic features of upper GI CMV disease. **Methods:** This 10-year retrospective study included all patients with a histopathological diagnosis of upper GI CMV infection. Patients' clinical, endoscopic, therapy, and follow-up data were collected from medical records. **Results:** Twelve patients with histopathologically proven upper GI CMV disease were identified (age 61 ± 18 years, 50% men). Most of the patients were immunocompromised (75%) due to acquired immunodeficiency syndrome (AIDS), malignancy, and/or immunosuppressive therapy. In the remainder (25%), the disease occurred in the absence of immunodeficiency and immuno-

suppression. Three patients (all with AIDS) presented with disseminated CMV infection. In the majority of the cases (83%), upper GI CMV disease was symptomatic, and the most common clinical presentations were odynophagia/dysphagia (25%) and nausea/vomiting (25%). Endoscopically, there were 5 cases of esophagitis (42%) and 7 cases of gastritis (58%). The lower esophagus (33%) and the gastric antrum (42%) were the most frequently affected GI sites. Regardless of the location, mucosal ulceration was the most common endoscopic finding (75%) and was associated with very deep ulceration resembling cavitation in 2 cases. Other endoscopic features were mucosal edema, hyperemia, and nodularity (25%). Eleven patients (92%) received antiviral treatment (duration 26 ± 12 days). The 1-month and 1-year mortality rates were 16.7 and 25%, respectively. **Conclusions:** Upper GI CMV disease can occur in the absence of immunodeficiency and immunosuppression. It is usually symptomatic, and mucosal ulceration is often evident at endoscopy. It is associated with significant mortality; therefore, early diagnosis and adequate antiviral treatment are essential.

© 2017 Sociedade Portuguesa de Gastreterologia
 Published by S. Karger AG, Basel

KARGER

E-Mail karger@karger.com
 www.karger.com/pjg

© 2017 Sociedade Portuguesa de Gastreterologia
 Published by S. Karger AG, Basel

 Karger
Open access

This article is licensed under the Creative Commons Attribution-NonCommercial-NoDerivatives 4.0 International License (CC BY-NC-ND) (<http://www.karger.com/Services/OpenAccessLicense>). Usage and distribution for commercial purposes as well as any distribution of modified material requires written permission.

Dr. Susana Marques
 Department of Gastroenterology, Centro Hospitalar Lisboa Ocidental
 Rua da Junqueira 126
 PT-1349-019 Lisbon (Portugal)
 E-Mail xsusanamarx@gmail.com

Estudo Retrospectivo a 10 Anos sobre os Aspectos Clínicos e Achados Endoscópicos da Infecção a Citomegalovírus do Tubo Digestivo Alto

Palavras Chave

Citomegalovírus · Esofagite · Gastrite · Endoscopia

Resumo

Introdução: A doença gastrointestinal (GI) por Citomegalovírus (CMV) é uma causa importante de morbidade e mortalidade em doentes imunocomprometidos. O cólon é o local mais comumente afectado e a literatura é escassa em relação à doença por CMV do tracto GI alto. Dessa forma, o nosso estudo teve como objectivo avaliar as características clínicas e endoscópicas da doença por CMV do tracto GI alto. **Métodos:** Trata-se de um estudo retrospectivo de 10 anos, que incluiu todos os doentes com o diagnóstico histopatológico de doença por CMV do tracto GI alto. Os dados clínicos, endoscópicos e sobre a terapêutica e o *follow-up* dos doentes foram obtidos por consulta de processos clínicos. **Resultados:** Foram identificados 12 doentes com o diagnóstico histopatológico de doença por CMV do tracto GI alto (idade 61 ± 18 anos, 50% homens). A maioria dos doentes era imunocomprometida (75%) no contexto de síndrome de imunodeficiência adquirida (SIDA), malignidade e/ou terapêutica imunossupressora. Nos restantes doentes (25%), a doença ocorreu na ausência de imunodeficiência ou imunossupressão. Três doentes (todos com SIDA) apresentaram infecção por CMV disseminada. Na maioria dos casos (83%), a doença por CMV do tracto GI alto foi sintomática e as apresentações clínicas mais comuns foram odinofagia/disfagia (25%) e náuseas/vômitos (25%). Endoscopicamente, registaram-se 5 casos de esofagite (42%) e 7 casos de gastrite (58%). O esfago inferior (33%) e o antro gástrico (42%) foram os locais mais frequentemente envolvidos. Independentemente da localização, a ulceração da mucosa foi o achado endoscópico mais comum (75%) e associou-se a ulceração muito profunda semelhante a cavitação em 2 casos. Outros achados endoscópicos foram edema, hiperémia e nodularidade da mucosa (25%). Onze doentes (92%) receberam terapêutica antiviral (duração 26 ± 12 dias). As taxas de mortalidade a 1 mês e a 1 ano foram 16,7 e 25%, respectivamente. **Conclusões:** A doença por CMV do tracto GI alto pode ocorrer na ausência de imunodeficiência e de imunossupressão. É geralmente sintomática e apresenta com frequência ulceração da mucosa na endoscopia. Associa-se

a mortalidade significativa, pelo que o diagnóstico precoce e a instigação adequada de tratamento antiviral são essenciais.

© 2017 Sociedade Portuguesa de Gastrenterologia
Publicado por S. Karger AG, Basel

Introduction

Cytomegalovirus (CMV) disease of the gastrointestinal (GI) tract is a major cause of morbidity and mortality in immunocompromised patients [1–3]. Patients at increased risk for GI CMV infection are those with acquired immunodeficiency syndrome (AIDS), recipients of solid and bone marrow transplants, those receiving immunosuppressive therapy, and patients with malignancies, especially those under chemotherapy or with hematological malignancies [1–3]. The colon is the most commonly affected site in GI CMV disease. However, the literature is limited regarding CMV disease of the upper GI tract.

The clinical presentation of GI CMV disease is variable and depends on the location and severity of the disease. Symptomatic patients may complain of dysphagia/odynophagia, nausea/vomiting, abdominal pain, and weight loss [1, 4]. Diagnosis of GI CMV disease relies mostly on endoscopy and GI biopsy. Histopathological diagnosis is made with the identification of CMV inclusion bodies on histology or with a positive immunohistochemical staining using anti-CMV monoclonal antibodies (Fig. 1) [1, 3]. A 2- to 3-week course of antiviral treatment with intravenous (i.v.) ganciclovir or per os (p.o.) valganciclovir is successful in most cases [5–7]. Nonetheless, GI CMV can cause serious disease in immunocompromised patients and has been associated with significant morbidity and mortality [8, 9]. Our study aimed to evaluate the clinical and endoscopic features of upper GI CMV disease, which have still not been well defined in the literature.

Material and Methods

Upper GI CMV disease was defined as the histological detection of CMV inclusion bodies in routine hematoxylin and eosin staining or a positive immunohistochemistry staining using anti-CMV monoclonal antibodies, and presenting signs or symptoms consistent with upper GI disease [3]. Disseminated CMV disease was defined as involvement of one or more organs besides the upper GI tract.

We retrospectively identified and reviewed the medical records of patients with histopathologically proven upper GI CMV disease who were hospitalized in our medical center between January 2006 and December 2015 (10-year period).

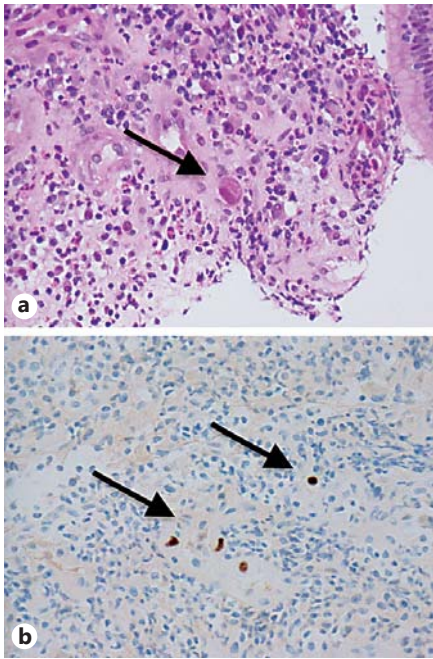


Fig. 1. Histopathological images of upper gastrointestinal cytomegalovirus (CMV) disease (patient 6, biopsy specimen of a gastric ulcer). **a** Histological detection of CMV inclusion bodies (arrow). Hematoxylin and eosin. $\times 400$. **b** Positive CMV immunohistochemistry (arrows). $\times 400$.

Patients' demographic, clinical, endoscopic, therapy, and follow-up data were collected from medical records. The following parameters were recorded: age, sex, underlying systemic diseases, disseminated CMV disease, symptoms and signs at the time of diagnosis, involved site of the upper GI tract at endoscopy, endoscopic findings, antiviral treatment, and 1-month and 1-year mortality.

Statistical analysis was performed using IBM SPSS Statistics, 22.0 (IBM Corp., USA).

Results

A total of 12 patients with histopathologically proven upper GI CMV disease were identified. The mean patient age at diagnosis was 61 ± 18 years (range 39–94 years) and there was no gender predilection (male:female ratio 1.0) (Table 1).

Most of the patients were immunocompromised (9/12, 75%) (Table 2). Five patients had AIDS and all were stage C2 or C3 by the CDC definition. Two AIDS patients also had a malignancy (1 had a diffuse large B-cell lymphoma and the other had a lung tumor and was receiving chemotherapy). In the immunocompromised non-AIDS group,

Table 1. Summary of the clinical, endoscopic, therapy, and follow-up data of the patients with upper GI CMV disease ($n = 12$)

Mean age \pm SD (range), years	61 \pm 18 (39–94)
Sex (M:F)	1.0
Immunocompromised patients, n (%)	9 (75)
(A) AIDS (CDC stage)	5
C2	2
C3	3
(B) Malignancy	4
Lung cancer under chemotherapy	1
Hematological malignancy	3
(C) Immunosuppressive therapy (indication)	3
Post kidney transplant	2
Myasthenia gravis	1
Disseminated CMV disease, n (%)	3 (25)
Retinitis	1
Pneumonitis	1
Hepatitis and bone marrow aplasia	1
Clinical presentation, n (%)	
Odynophagia/dysphagia	3 (25)
Nausea/vomiting	3 (25)
Abdominal pain	2 (17)
Upper GI bleeding	2 (17)
Asymptomatic (gastric wall thickening on CT)	2 (17)
GI CMV disease location, n (%)	
(A) Esophagus	5 (42)
Upper	1
Lower	3
Diffuse involvement	1
(B) Stomach	7 (58)
Fundus	1
Body	1
Antrum	4
Diffuse involvement	1
Endoscopic features, n (%)	
Ulceration	9 (75)
Edema and hyperemia	2 (17)
Mucosal nodularity	1 (8)
Antiviral therapy, n (%)	
Yes	11 (92)
No ^a	1 (8)
Antiviral drug(s), n (%)	
p.o. valganciclovir	3 (25)
i.v. ganciclovir	3 (25)
i.v. ganciclovir, followed by p.o. valganciclovir	5 (42)
Mean antiviral therapy duration \pm SD (range), days	26 \pm 12 (14–60)
Mortality, n (%)	
Within 1 month after diagnosis	2 (17)
Within 1 year after diagnosis	3 (25)

GI, gastrointestinal; CMV cytomegalovirus. ^a Patient died while awaiting histopathological diagnosis.

2 patients were kidney transplant recipients under immunosuppressive treatment (one of which had a concomitant anaplastic lymphoma), 1 patient had myasthenia gravis and was receiving immunosuppression, and 1 patient had a diffuse large B-cell lymphoma. In 3 patients, the disease occurred in the absence of immunodeficiency and

Table 2. Clinical characteristics of the 12 cases of upper GI CMV disease

No.	Age, years/ sex	Immunocompromised conditions	Other underlying diseases	Disseminated CMV disease
1	86/F	None	Cerebral vascular disease (ischemic stroke in the past)	No
2	45/M	AIDS (stage C3 ^a) Lung tumor under chemotherapy	Chronic obstructive lung disease	CMV pneumonitis
3	43/M	Kidney transplant recipient under immunosuppression	No	No
4	54/M	AIDS (stage C2 ^a) Diffuse large B-cell lymphoma	No	No
5	62/M	Kidney transplant recipient under immunosuppression Anaplastic lymphoma	No	No
6	38/M	AIDS (stage C2 ^a)	No	No
7	52/F	AIDS (stage C3 ^a)	Type 2 diabetes mellitus	CMV retinitis
8	59/F	AIDS (stage C3 ^a)	No	CMV hepatitis and bone marrow aplasia
9	51/M	None	Decompensated alcoholic liver cirrhosis Type 2 diabetes mellitus	No
10	94/F	Diffuse large B-cell lymphoma	Congestive heart failure	No
11	87/F	None	No	No
12	63/F	Myasthenia gravis under immunosuppression	No	No

GI, gastrointestinal; CMV, cytomegalovirus. ^a According to the HIV CDC classification.

immunosuppression (25%). In the non-immunocompromised group, there was an 87-year-old patient without known comorbidities, an 86-year-old post-stroke patient, and a 51-year-old patient with decompensated alcoholic liver cirrhosis.

Three patients, all AIDS stage C3 by CDC definition, presented with disseminated CMV infection. Besides upper GI tract involvement, 1 had retinitis, 1 had pneumonitis, and 1 had hepatitis and bone marrow aplasia.

Most of the patients had symptomatic upper GI CMV disease (83%) (Table 3). The most common clinical presentations were odynophagia/dysphagia (25%) and nausea/vomiting (25%). Other reported symptoms were abdominal pain (17%) and upper GI bleeding manifested by melena (17%). Two patients were asymptomatic (17%) and both were referred for upper GI endoscopy because of gastric wall thickening found incidentally on CT.

Endoscopically, there were 5 cases of CMV esophagitis (42%) and 7 cases of CMV gastritis (58%). The lower

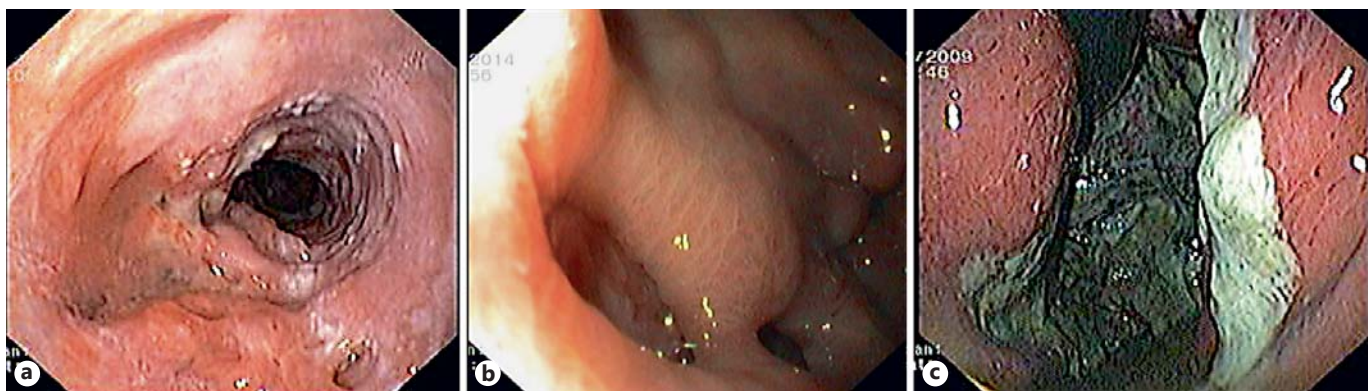esophagus (33%) and the gastric antrum (42%) were the most frequently affected GI sites. Regardless of the location of the upper GI CMV disease, mucosal ulceration was the most frequent endoscopic finding (75%). Ulcers were very deep, resembling the formation of cavities in 2 cases (Fig. 2). Other endoscopic features were mucosal edema and hyperemia (17%) as well as mucosal nodularity (8%).

Except for 1 patient who died while awaiting histopathological diagnosis, all others received antiviral treatment (11/12, 92%). Three patients were treated with p.o. valganciclovir alone, 3 with i.v. ganciclovir alone, and 5 received sequential therapy with i.v. ganciclovir followed by p.o. valganciclovir. The mean duration of the antiviral treatment was 26 ± 12 days (range 14–60 days). Maintenance therapy with a lower dose of p.o. valganciclovir was subsequently given in 3 patients (1 AIDS patient with CMV retinitis and 2 kidney transplant recipients under high-dose immunosuppression).

Table 3. Clinical presentation, endoscopic features, antiviral therapy and follow-up data of the 12 cases of upper GI CMV disease

No.	Clinical presentation	GI CMV location	Endoscopic findings	Antiviral therapy (drugs)	Therapy duration, days	Maintenance therapy	Follow-up 1 year after diagnosis
1	Nausea/vomiting	Lower esophagus	Ulceration	None ^a	–	–	Died within 1 month of diagnosis
2	Odynophagia/dysphagia	Upper esophagus	Ulceration	Ganciclovir	23	No	Died within 2 months after diagnosis
3	Nausea/vomiting	Lower esophagus	Ulceration	Valganciclovir	21	Yes	Alive
4	Upper GI bleeding (melena)	Entire esophagus	Deep ulceration (Fig. 2a)	Ganciclovir followed by valganciclovir	20	No	Alive
5	Odynophagia/dysphagia	Lower esophagus	Ulceration	Valganciclovir	60	Yes	Alive
6	Asymptomatic (gastric wall thickening on CT)	Gastric antrum	Deep ulceration (Fig. 2b)	Ganciclovir followed by valganciclovir	28	No	Alive
7	Abdominal pain (epigastric)	Gastric antrum	Edema and hyperemia	Ganciclovir followed by valganciclovir	21	Yes	Alive
8	Odynophagia/dysphagia	Entire stomach	Edema and hyperemia	Ganciclovir followed by valganciclovir	28	No	Alive
9	Asymptomatic (gastric wall thickening on CT)	Gastric antrum	Mucosal nodularity	Ganciclovir followed by valganciclovir	28	No	Alive
10	Nausea/vomiting	Gastric fundus	Ulceration (Fig. 2c)	Ganciclovir	18	No	Died within 1 month of diagnosis
11	Upper GI bleeding (melena)	Gastric body	Ulceration	Ganciclovir	14	No	Alive
12	Abdominal pain (epigastric)	Gastric antrum	Ulceration	Valganciclovir	21	No	Alive

GI, gastrointestinal; CMV, cytomegalovirus. ^a Patient died while awaiting histopathological diagnosis.

**Fig. 2.** Endoscopic images of upper gastrointestinal cytomegalovirus disease. **a** Deep esophageal ulcers (patient 4). **b** Deep ulcers in the gastric antrum (patient 6). **c** Extensive ulceration of the gastric fundus (patient 10).

Regarding the clinical outcome, 2 patients died within the first month after diagnosis (1-month mortality rate of 17%) and 1 patient died within the first year (1-year mortality rate of 25%).

Discussion

CMV disease of the GI tract is a common manifestation of CMV infection and the colon is the most frequently involved GI segment [1]. However, the literature is scarce regarding CMV disease of the upper GI tract. Two of the largest studies concerning upper GI CMV disease are from Wang et al. [1] and from Péter et al. [10]. The first study identified 16 patients with CMV esophagitis and the second included 91 patients with CMV gastritis and/or duodenitis. Among these and other studies, it has been consistently observed that GI CMV infection is much more common in immunocompromised patients. The immunocompromised conditions most frequently reported are AIDS, solid and bone marrow transplantation, other conditions requiring immunosuppressive therapy, and malignancies, especially if under chemotherapy or hematological malignancies [1–3]. Despite immunocompromised patients being more often affected, Bonetti et al. [4] reported in a case series of 30 patients with upper GI CMV disease that 50% of them were apparently healthy individuals. In a similar way, in the present study, although the majority of patients were immunocompromised, in 25% the disease occurred in the absence of immunodeficiency and immunosuppression.

The clinical presentation of upper GI CMV disease is variable and depends on its location and severity. Wang et al. [1] reported odynophagia/dysphagia (44%) and epigastric pain (31%) as the most common symptoms in CMV esophagitis patients. In contrast, Péter et al. [10] concluded that abdominal pain (39%), anemia/GI bleeding (20%), and nausea/vomiting (13%) were the most frequently complaints in patients with CMV gastritis/duodenitis. Moreover, in up to 7% of the cases, upper GI CMV disease may have an asymptomatic presentation [10]. Our study was consistent with these results as dysphagia (40%) and abdominal pain (29%) were also the most common symptoms in CMV esophagitis and gastritis patients, respectively. Additionally, 17% of the patients were asymptomatic and were referred for upper endoscopy because of gastric wall thickening found incidentally on an abdominal CT scan.

The endoscopic appearance of upper GI CMV disease is also variable and nonspecific. It can range from normal

or minimal inflamed mucosa to deep ulceration [2, 4]. The most documented endoscopic findings depend on the location of the disease. In CMV esophagitis, ulcers are more common than mucosal inflammation (88 vs. 63%) [1], whereas in gastroduodenal disease inflammatory changes may exceed ulceration (54 vs. 18%) [10]. Despite the location in the GI tract, erosions and ulcers tend to be multiple [1, 4]. Extensive and deep ulceration can also be present and may lead to serious GI complications, such as perforation and massive bleeding [2, 11–17]. Therefore, early diagnosis and treatment are of great importance. In our study, mucosal ulceration was observed in the majority of cases (75%). It was documented in 57% of the patients with gastritis and in all patients with esophagitis (100%). Of note, in 2 cases (17%) profound ulcers, resembling the formation of cavities, were observed at endoscopy.

Contrary to previous reports [18–23], the esophagus does not appear to represent the most common site of upper GI tract involvement in our study, as we identified 5 cases of CMV esophagitis (42%) and 7 cases of CMV gastritis (58%). The most frequently affected sites of the upper GI tract were the lower esophagus (33%) and the gastric antrum (42%). Of interest, the lower esophagus was involved in 80% (4/5) of the patients with CMV esophagitis and the antrum in 71% (5/7) of the patients with CMV gastritis. Similar findings were reported in previous studies, which showed that the most commonly affected sites are the mid-distal esophagus (88%) [1] and the antrum (84%) [4] in esophageal and gastric CMV disease, respectively.

In the present study, 2 cases (17%) of diffuse CMV organ involvement were documented (1 patient with diffuse esophagitis and 1 with diffuse gastritis). A few similar cases of diffuse organ involvement and synchronous multiple organ involvement have also been documented in the literature [1, 4]. Synchronous organ involvement seems to be particularly prevalent in duodenal CMV disease, which is associated with gastric disease in 77% of cases [4, 10].

The recommended antiviral therapy for GI CMV disease is i.v. ganciclovir for at least 2–3 weeks [2, 5–6]. Because of its high bioavailability, p.o. valganciclovir is also considered an effective drug [7]. Maintenance therapy with oral valganciclovir is advocated in particular situations, such as in patients with concomitant CMV retinitis and in those receiving high-dose immunosuppression [24, 25]. In this study, sequential therapy with i.v. ganciclovir followed by p.o. valganciclovir was the most common treatment (42%). The antiviral therapy duration ranged between 2 weeks and 2 months, and in 3 patients maintenance therapy was subsequently given.

Although very few studies have assessed patient outcomes, upper GI CMV disease has been associated with significant morbidity and mortality [8, 9]. This was also evident in this study, where the 1-year mortality rate reached 25%.

Conclusion

There is increasing evidence that upper GI CMV disease can occur in both immunocompromised patients and apparently healthy individuals. Future studies are needed to identify other potential risk factors for developing this disease. Patients with upper GI CMV infection are usually symptomatic, and mucosal ulceration is often evident at endoscopy. Upper GI CMV is associated with significant mortality; therefore, early diagnosis and adequate antiviral treatment are essential.

References

- 1 Wang HW, Kuo CJ, Lin WR, et al: The clinical characteristics and manifestations of cytomegalovirus esophagitis. *Dis Esophagus* 2016; 29:392–399.
- 2 Ozaki T, Yamashita H, Kaneko S, et al: Cytomegalovirus disease of the upper gastrointestinal tract in patients with rheumatic diseases: a case series and literature review. *Clin Rheumatol* 2013;32:1683–1690.
- 3 Seo M, Kim do H, Gong EJ, et al: Is follow-up endoscopy necessary in upper gastrointestinal cytomegalovirus disease? *Medicine (Baltimore)* 2016;95:e3389.
- 4 Bonetti LR, Losi L, Greagorio C, et al: Cytomegalovirus infection of the upper gastrointestinal tract: a clinical and pathological study of 30 cases. *Scand J Gastroenterol* 2011;46:1228–1235.
- 5 You DM, Johnson MD: Cytomegalovirus infection and the gastrointestinal tract. *Curr Gastroenterol Rep* 2012;14:334–342.
- 6 Asberg A, Humar A, Rollag H, et al: Oral valganciclovir is noninferior to intravenous ganciclovir for the treatment of cytomegalovirus disease in solid organ transplant recipients. *Am J Transplant* 2007;7:2106–2113.
- 7 Len O, Gavalda J, Aguado JM, et al: Valganciclovir as treatment for cytomegalovirus disease in solid organ transplant recipients. *Clin Infect Dis* 2008;46:20–27.
- 8 Siciliano RF, Castelli JB, Randi BA, et al: Cytomegalovirus colitis in immunocompetent critically ill patients. *Int J Infect Dis* 2014;20:71–73.
- 9 Galiatsatos P, Shrier I, Lamoureux E, Szilagyi A: Meta-analysis of outcome of cytomegalovirus colitis in immunocompetent hosts. *Dig Dis Sci* 2005;50:609–616.
- 10 Péter A, Telkes G, Varga M, et al: Endoscopic diagnosis of cytomegalovirus infection of upper gastrointestinal tract in solid organ transplant recipients: Hungarian single-center experience. *Clin Transplant* 2004;18:580–584.
- 11 Featherstone RJ, Camero LG, Khatib R, et al: Massive esophageal bleeding in achalasia complicated by cytomegalovirus esophagitis. *Ann Thorac Surg* 2004;78:1021–1022.
- 12 Kanda K, Kume K, Yoshikawa I, et al: Cytomegalovirus esophagitis with massive upper-GI hemorrhage. *Gastrointest Endosc* 2004;59:741–743.
- 13 Kaplan CS, Petersen EA, Icenogle TB, et al: Gastrointestinal cytomegalovirus infection in heart and heart-lung transplant recipients. *Arch Intern Med* 1989;149:2095–2100.
- 14 Aqel NM, Tanner P, Drury A, et al: Cytomegalovirus gastritis with perforation and gastrocolic fistula formation. *Histopathology* 1991; 18:165–168.
- 15 Lee HK, Chung DH, Jung J, et al: Three cases of pancreas allograft dysfunction. *J Korean Med Sci* 2001;15:105–110.
- 16 Howaizi M, Abboura M, Sbai-Idrissi MS, et al: Cytomegalovirus-associated perforated gastric ulcer healing under antiviral therapy. *Dig Dis Sci* 2002;47:2380–2382.
- 17 Mayeux GP, Smith JW: Massive esophageal bleeding from cytomegalovirus esophagitis. *Am J Gastroenterol* 1990;85:626.
- 18 Lin WR, Su MY, Hsu CM, et al: Clinical and endoscopic features for alimentary tract cytomegalovirus disease: report of 20 cases with gastrointestinal cytomegalovirus disease. *Chang Gung Med J* 2005;28:476–484.
- 19 Goodgame RW: Gastrointestinal cytomegalovirus disease. *Ann Intern Med* 1993;119:924–935.
- 20 Chuah SK, Changchien CS, Kuo CM, et al: Gastrointestinal tract cytomegalovirus disease in southwestern Taiwan: a clinical study of 1950 endoscopic biopsies. *Chang Gung Med J* 2005;28:467–475.
- 21 Péter A, Telkes G, Varga M, et al: Gastrointestinal cytomegalovirus infections in organ transplant patients. *Orv Hetil* 2008;149:2463–2470.
- 22 Ohnuma H, Sato Y, Takayama T, et al: Esophageal cancer complicated by cytomegalovirus esophagitis during chemoradiotherapy: case report. *Gastrointest Endosc* 2003;57:622–626.
- 23 Francis ND, Boylston AW, Roberts AH, et al: Cytomegalovirus infection in gastrointestinal tracts of patients infected with HIV-1 or AIDS. *J Clin Pathol* 1989;42:1055–1064.
- 24 Patil AJ, Sharma A, Kenney MC, et al: Valganciclovir in the treatment of cytomegalovirus retinitis in HIV-infected patients. *Clin Ophthalmol* 2010;4:111–119.
- 25 Kotton CN, Kumar D, Caliendo AM, et al: Transplantation Society International CMV Consensus Group: International consensus guidelines on the management of cytomegalovirus in solid organ transplantation. *Transplantation* 2010;89:779–795.

Statement of Ethics

This study did not require informed consent or review/approval by the appropriate ethics committee.

Disclosure Statement

All authors approved the manuscript and agree with its submission to *GE – Portuguese Journal of Gastroenterology*. All authors have nothing to disclose.

Author Contributions

S. Marques and J. Carmo wrote the manuscript. M. Bispo, S. Ramos, and C. Chagas were responsible for the revision of its contents.