

# Management of Nonmalignant Portal Vein Thrombosis in Cirrhosis

Francisco Capinha<sup>a</sup> Carlos Noronha Ferreira<sup>a, b</sup>

<sup>a</sup>Serviço de Gastreenterologia e Hepatologia, Hospital de Santa Maria, Centro Hospitalar Universitário Lisboa Norte, Lisbon, Portugal; <sup>b</sup>Clínica Universitária de Gastreenterologia, Faculdade de Medicina de Lisboa, Universidade de Lisboa, Lisbon, Portugal

## Keywords

Portal vein thrombosis · Cirrhosis · Anticoagulation · Transjugular intrahepatic portosystemic shunt · Prognosis

## Abstract

Nonmalignant portal vein thrombosis (PVT) is a common complication of cirrhosis especially at the stage of decompensations. The diagnosis of PVT in cirrhosis is often incidental and it may be detected during routine semestral abdominal ultrasound with Doppler during screening for hepatocellular carcinoma or during hospitalization for decompensated cirrhosis. After detection of PVT on abdominal ultrasound, it is important to evaluate patients with cross-sectional imaging to determine the age of thrombus, whether acute or chronic, the extent and degree of luminal occlusion of the portal vein, and to rule out hepatocellular carcinoma or other underlying malignancy. Factors influencing management include the degree and extent of luminal occlusion of PVT, potential listing for liver transplantation, and portal hypertension (PHT) complications such as variceal hemorrhage and refractory ascites, severity of thrombocytopenia, and other comorbidities including chronic kidney disease. Anticoagulation is the most common therapeutic option and it is specially indicated in patients who are candidates for liver transplantation. Interventional procedures including transjugular intrahepatic portosystemic shunt (TIPS) placement and mechanical

thrombectomy may be used on a case-by-case basis in patients with contraindications or adverse events related to anticoagulation, who develop worsening PVT while on anticoagulant therapy, or have chronic PVT and PHT complications that are not manageable medically or endoscopically.

© 2023 The Author(s).  
Published by S. Karger AG, Basel

## Abordagem à trombose não neoplásica da veia porta no doente cirrótico

### Palavras Chave

Trombose da veia porta · Cirrose · Anticoagulação · TIPS · Prognóstico

### Resumo

A trombose da veia porta (TVP) é uma complicação frequente na cirrose, especialmente na fase de descompensação. O diagnóstico é na maioria das vezes realizado de forma incidental, durante o rastreio semestral para o carcinoma hepatocelular com ecografia abdominal com doppler ou durante o internamento por episódio de descompensação da cirrose. Após a deteção de TVP numa ecografia abdominal com doppler, é importante a realização de um método de imagem

complementar de corte axial para avaliar a idade do trombo, se agudo ou crônico, a extensão e grau de oclusão luminal da veia porta e para excluir carcinoma hepatocelular ou outra neoplasia subjacente. A gestão do doente depende do grau de oclusão e da extensão do trombo na circulação portal, mas também da possibilidade de ser candidato para transplante hepático, complicações da hipertensão portal, gravidade de trombocitopenia e da existência de outras comorbidades relevantes como a doença renal crônica. A anticoagulação é a principal opção terapêutica mas outros procedimentos como a colocação de TIPS e tromboectomia mecânica devem ser pensados caso a caso, quando existem contra-indicações à anticoagulação, a resposta à terapêutica anticoagulante não é adequada ou existem complicações da hipertensão portal não abordáveis com terapêutica médica ou endoscópica.

© 2023 The Author(s).  
Published by S. Karger AG, Basel

## Introduction

Nonmalignant portal vein thrombosis (PVT) is a common vascular disorder that develops in advanced liver disease [1]. Patients with cirrhosis have a higher risk of developing hepatocellular carcinoma (HCC), and therefore, it is very important to rule out tumoral invasion in those who develop PVT since this influences therapeutic strategy [1].

The management of PVT starts with an adequate evaluation and risk stratification of the patient at the time of diagnosis. This implies an estimate of the age of the thrombus, whether acute (<6 months) or chronic (>6 months) and the extension and degree of luminal occlusion of the portal vein (PV), splenic and superior mesenteric veins, and exclusion of HCC with cross-sectional imaging with either contrast enhanced computed tomography (CT) or magnetic resonance imaging (MRI) [2].

As the incidence of PVT increases with increasing severity of liver disease, the clinical challenge is to choose the patients who will benefit most from treatment, which in most cases relies on anticoagulation [3]. However, as these are very complex patients often with alcohol dependence, concomitant thrombocytopenia, and comorbidities including chronic kidney disease, management of PVT should be individualized [4].

## Epidemiology

PVT is common in patients with cirrhosis but is relatively rare in the general population [1]. In a study involving more than 20,000 autopsied patients, the prevalence of PVT was 1%, with patients with cirrhosis being almost 8 times more prone to develop this condition [5]. The incidence of PVT increases with increasing severity of cirrhosis and is more common in patients belonging to Child-Pugh class B and C and those with high MELD score [6].

In the study by Nery et al. [7], in which 1,243 patients with cirrhosis were prospectively evaluated, the 5-year cumulative incidence of PVT was 10.7%. In a prospective study involving 241 patients, the 1- and 3-year incidence of PVT was 3.7% and 7.6%, respectively [8]. In another prospective study involving 369 patients, the incidence of nontumoral PVT was 1.6%, 6%, and 8.4% at 1, 3, and 5 years, respectively [3]. The prevalence of PVT increases with the severity of the cirrhosis, being less than 1% in patients with compensated cirrhosis and varying between 8% and 25% in those who are candidates for liver transplantation [9].

PVT is partial in 73%–86% of patients and is often asymptomatic [7]. Approximately 40% of PVT will have spontaneous resolution, typically within 3 months, although there are no clearly identified clinical predictors of recanalization [1]. Nonetheless, progression or stability is more common than regression in untreated PVT [10]. The risk of rethrombosis is also significant in these patients and may occur in a third of patients, and therefore, surveillance for de novo PVT should be continued after recanalization [11].

## Risk Factors

The pathophysiology of PVT is multifactorial and, like other venous thrombosis, is believed that thrombotic risk is due to blood stasis, hypercoagulability, and endothelial injury, which are the components of Virchow's triad [1]. Nonetheless, the pathophysiology of PVT seems to be unique, and the relation of these three with it is not totally clear [12].

The splanchnic circulation has unique conditions related to its slow-flow and high-volume hemodynamics that are disturbed by cirrhosis and subsequent portal hypertension (PHT) [1]. The velocity of PV flow is an independent predictor of PVT development, especially in patients with PV blood flow velocity <15 cm/s, making these patients a high-risk subgroup, probably due to blood stasis [6, 13].

Presence of esophageal varices and prolonged prothrombin time are independent predictors of development of PVT [7]. Additionally, previous decompensation

of cirrhosis and thrombocytopenia has been found to be independent predictors of development of PVT [8].

A study conducted in virus-related cirrhosis suggested that large portosystemic collateral vessels contribute to increased risk of PVT, which could be explained by the steal effect that reduces the PV blood flow [14]. A recent meta-analysis concluded that nonselective  $\beta$ -blockers, used for primary and secondary prophylaxis of variceal bleeding, could increase the risk of PVT in cirrhotic patients [15]. However, some authors defend that the main driver for the higher risk of developing PVT is the severity of PHT, which often correlates with more advanced liver disease and leads to the prescription of nonselective  $\beta$ -blockers, and not the use of the medication itself [3].

Patients with cirrhosis have complex hemostatic alterations with a delicate balance between procoagulant or anticoagulant factors, with a tendency to tip toward thrombosis in the presence of inflammation and infection [3]. The assessment of prothrombin time and international normalized ratio does not truly represent the hemostatic balance of these patients who are not naturally anticoagulated but who actually have a tendency for thrombosis [16]. Although prothrombotic disorders, like congenital or acquired thrombophilias or myeloproliferative neoplasms, are associated with noncirrhotic PVT, the screening for thrombophilic disorders in patients with cirrhosis is currently not yet recommended [2]. A large recent prospective study could not prove a direct link between genetic and acquired prothrombotic factors and the development of PVT in cirrhotic patients [12].

It has been postulated that the direct and indirect damage to portal venous endothelium is mostly promoted by bacterial translocation, inflammation, and endotoxemia in patients with cirrhosis due to the underlying PHT [10]. The association of these conditions with development of PVT needs confirmation with robust studies, but previous decompensation of cirrhosis and thrombocytopenia appear to correlate well with its development, indirectly reflecting the pathophysiological role of the severity of PHT in the development of thrombosis in the splanchnic circulation [8]. Other independent risk factors for the development of PVT in cirrhosis that have been determined include obesity, metabolic syndrome, and nonalcoholic steatohepatitis [17, 18].

The gap between pathophysiology of systemic venous thrombosis and thrombosis in portal vascular territory has been a matter of debate [12]. A recent study in a series of 63 nonmalignant PVT in patients with cirrhosis showed that tunica intima thickening of the vessel wall prevails in a significant proportion of patients rather than fibrin-rich

thrombus, which may explain the lower PVT recanalization rates with anticoagulant therapy. This could offer an explanation for the limitations of anticoagulant therapy in some patients. Nonetheless, the study has important limitations and more studies are required to validate this new paradigm in the pathophysiology of PVT [19].

---

## Diagnosis and Classification

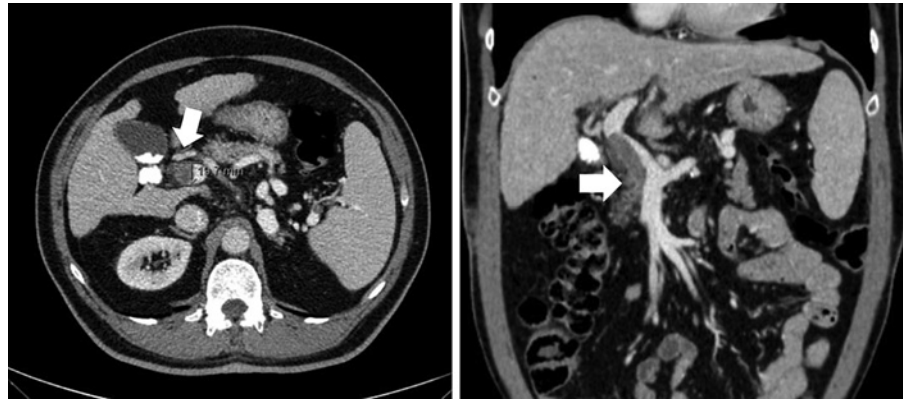In patients with cirrhosis, PVT is often asymptomatic and it is diagnosed incidentally during semestral screening for HCC with abdominal ultrasound with Doppler [20]. Nonetheless, PVT should be suspected in any patient with cirrhosis who develops a clinical decompensating event or abdominal pain [1].

The current guidelines [9, 21] do not provide a formal recommendation to screen these patients for PVT, but as they already undergo abdominal ultrasound screening for HCC every 6 months, the assessment of PV could be done at the same time with abdominal ultrasound ideally with Doppler, which has a higher sensitivity to detect a thrombus in the PV without consuming additional resources and time [11].

Abdominal ultrasound with Doppler is the first-line approach to detect PVT and some imaging features may allow distinction between acute or recent (<6 months) and chronic (>6 months) thrombosis [2]. In an acute PVT, the clot is normally hypoechoic or isoechoic with a mildly dilated PV, in contrast to the hyperechoic material and the cavernous transformation with multiple small vessels in chronic PVT [2]. The performance of abdominal ultrasound with Doppler is not perfect, with a sensitivity of 90% for complete PVT and 50% for partial PVT, with the additional limitation of being operator-dependent [11]. Additionally, there may be technical difficulties in evaluating concomitant superior mesenteric vein (SMV) thrombosis in these patients [10].

The detection of PVT on abdominal ultrasound with Doppler should be followed by a cross-sectional imaging method, contrast-enhanced abdominal CT, or MRI to confirm the diagnosis, to determine the age of the thrombus and extent and degree of luminal occlusion of the splanchnic circulation by the thrombus, and to rule out HCC and other abdominal malignancies [10]. Anatomically, PVT involves mainly the PV trunk and branches and may involve the SMV and splenic vein [13] (shown in Fig. 1).

The lack of standardized nomenclature in PVT has been a problem, and in order to address this issue, the American Association for the Study of Liver Disease (AASLD) proposed a new standardized nomenclature for the description of PVT [22]. In terms of time course, PVT



**Fig. 1.** Images of a thrombus occupying more than 50% of the PV trunk.

is classified as recent (<6 months) or chronic (>6 months) and a reference is made to cavernous transformation, which is associated with chronic PVT and lower probability of PVT recanalization [22]. With regard to the severity of occlusion of the main PV, degree of luminal occlusion is classified as <50% and >50%. Finally, during the follow-up, PVT should be defined as progressive, stable, or regressive [22]. All these definitions have important implications on management and outcome.

Despite several proposed classification systems, the one suggested by Yerdel et al. [23] using anatomic criteria continues to be widely used, because of its simplicity and reproducibility, which includes: site, degree of occlusion, and extension of the thrombus as shown in Figure 2 [24]. As this classification is only anatomical, although it is useful for surgical management, including liver transplantation, it lacks information for a clinical therapeutic decision [25].

Recently, Sarin et al. [25] proposed a more integrated classification taking into account also functional aspects including the occurrence of symptoms and timing of thrombosis. This classification has been developed for patients with cirrhosis, with the possibility of adding other variables like anticoagulation, type of underlying liver disease, and presence of clinical significant PHT [25].

After detection of PVT, an upper endoscopy should be performed to assess the presence and size of esophageal varices and/or gastric varices, and if required, primary or secondary prophylaxis of variceal bleeding should be initiated promptly prior to anticoagulant therapy [11].

## Treatment

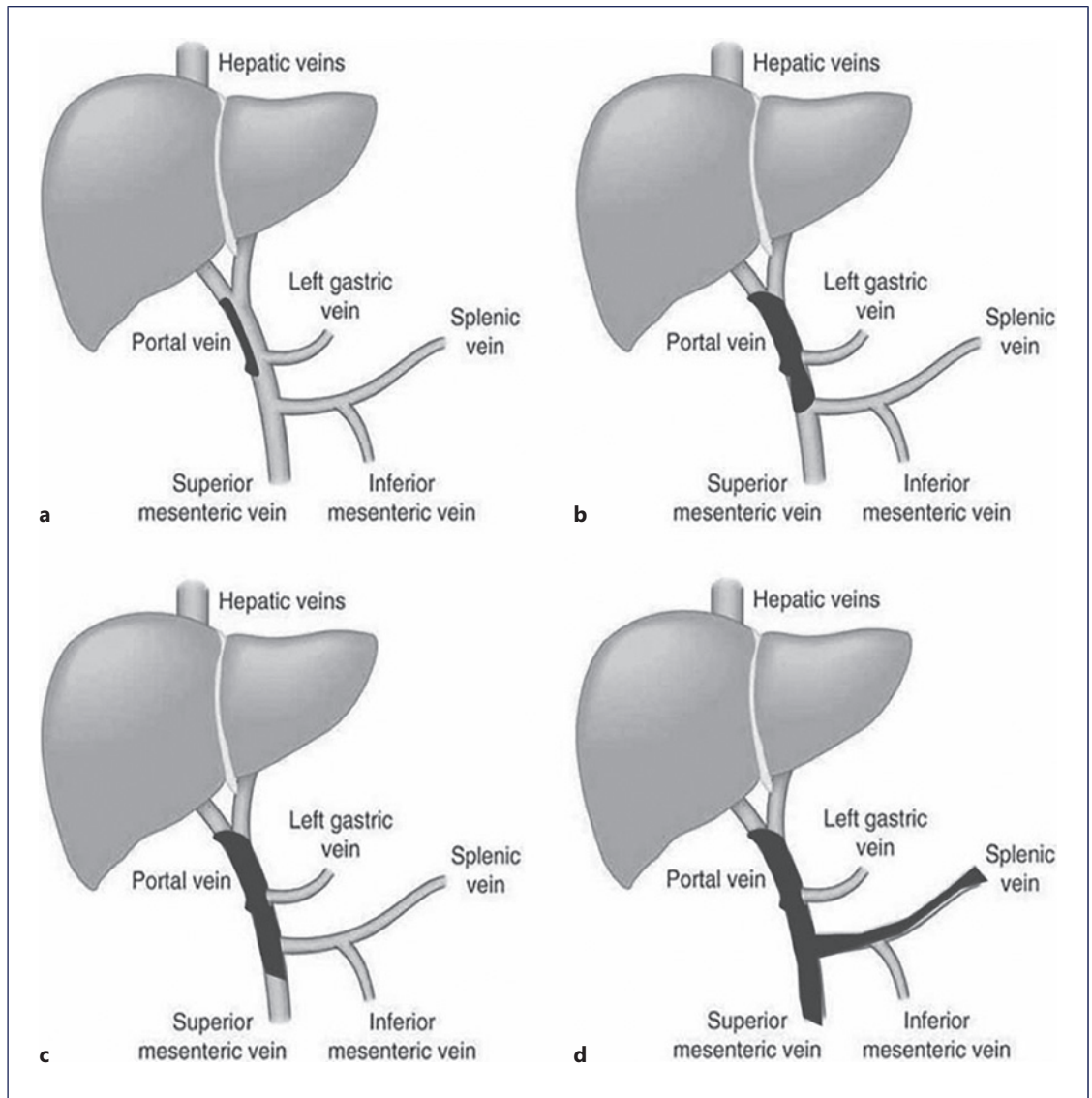
After confirming the diagnosis of nontumoral PVT and its extent and degree of luminal occlusion, it is important to stratify patients according to the possibility of undergoing liver transplantation, presence of concomitant PHT

complications like variceal hemorrhage and refractory ascites, age, thrombocytopenia, and comorbidities including chronic kidney disease, in order to individualize clinical management decisions that primarily involve anticoagulant therapy [26]. In potential candidates to OLT, the extent and degree of luminal occlusion in PVT have implications on liver transplant surgery strategy as well as postoperative morbidity and early mortality. The outcome of grade 1 PVT patients (<50% luminal occlusion) does not differ from non-PVT patients, but grades 2–4 have poorer outcomes [23]. This highlights the importance of 50% luminal occlusion cutoff to determine which patients should be promptly treated. Fortunately, majority of patients with cirrhosis have partial thrombosis of the PVT often causing <50% luminal occlusion and were transient and completely disappeared spontaneously during the follow-up in two-third of the patients as was shown in the study by Nery et al. [7].

The therapeutic options include anticoagulation with conventional anticoagulants or direct oral anticoagulants in compensated (Child-Pugh A) cirrhosis and low molecular weight heparin (LMWH) in advanced cirrhosis (Child-Pugh B and C). In patients with contraindications, adverse events related to anticoagulation, progression of PVT on anticoagulation, or that have concomitant clinical indication for it, and interventional radiology techniques such as transjugular intrahepatic portosystemic shunt (TIPS) and mechanical thrombectomy are recommended [2]. A multidisciplinary team involving gastroenterologists, imaging specialists, interventional radiologists, and surgeons could be useful to provide the best treatment option for patients with cirrhosis and nontumoral PVT [27].

### Anticoagulation

The aim of anticoagulant therapy is to recanalize the thrombosed veins and prevent further extension of the thrombus and complications such as intestinal ischemia due to extension of the PVT into the SMV [7]. An upper



**Fig. 2. a–d** Yerdel classification of PVT. Adapted from Chen et al. [24].

endoscopy for screening of esophageal varices and gastric varices is recommended in all patients candidates for anticoagulant therapy, and when indicated, primary or secondary prophylaxis of variceal bleeding should be initiated prior to starting anticoagulation [4]. However, this recommendation is not consensual and recent practice guidelines from the AASLD suggest that endoscopic band ligation is safe under therapeutic anticoagulation, and therefore, anticoagulant therapy, if indicated, should not be delayed until varices are eradicated [22].

In patients with cirrhosis and PVT, especially in liver transplant candidates, anticoagulation is indicated for those who are symptomatic, have luminal occlusion of the PV

trunk over 50%, have extension to the SMV, and do not meet these criteria at the time of diagnosis but show progression of PVT during the follow-up [2]. Patients with chronic occlusion of PV or cavernous transformation with collaterals may not have a clear benefit of anticoagulation in terms of recanalization of occluded segment of PV [22]. In patients with thrombosis involving <50% of the lumen of PV trunk and/or branches, follow-up abdominal ultrasound with Doppler is recommended every 3 months to detect progression or resolution of the thrombus [1].

The strategy and clinical decisions guiding management of nontumoral PVT in patients with cirrhosis are shown in Figure 3. Nonetheless, it is important to make

individualized decisions, taking into account, ongoing alcohol abuse, compliance to treatment of complications of cirrhosis, patient fragility, and comorbidities such as chronic renal failure and the risk of fall [2].

The success of anticoagulation is correlated with early diagnosis of PVT and early initiation of anticoagulant therapy with patients that start anticoagulation within 6 months of detection of PVT being more likely to successfully recanalize PVT [28]. The pooled recanalization rates of PVT with anticoagulant therapy have been shown to be around 58% in a recent meta-analysis [29]. Factors like Child-Pugh class A, less extensive PVT, and absence of prior variceal bleeding appear to predict higher recanalization rates [30]. Anticoagulation significantly reduces all-cause mortality, compared to no treatment, and this benefit appears to be independent from PVT recanalization itself [29].

Anticoagulation appears to be safe in patients with cirrhosis when correctly selected, and a large systematic review showed that PVT patients treated with LMWH or vitamin K antagonists (VKA) achieved higher recanalization rates compared to placebo (72% vs. 40%), without significant differences in bleeding complications [31]. In the meta-analysis evaluating anticoagulant therapy in nontumoral PVT in cirrhosis by Guerrero A et al. [29], the bleeding rate was similar between the groups (anticoagulation and no treatment), with no significant differences in PHT-related bleeding in the 2 groups of patients. The risk of bleeding appears to correlate with platelet counts at baseline  $<50,000$  cells/ $\mu\text{L}$ , low serum albumin, and prior variceal bleeding [31].

The incidence of variceal bleeding in patients with cirrhosis and PVT was found to be significantly lower in those receiving anticoagulation compared to untreated ones (2% vs. 12%) [32], highlighting the benefit of anticoagulation in preventing future decompensations of cirrhosis. However, potential biases involving prophylaxis of variceal bleeding in patients receiving anticoagulation compared to untreated ones may have explained differences in variceal bleeding rates.

LMWH and VKA are considered as first choice in patients with cirrhosis and PVT, but the patient profile is extremely important [11]. LMWH is the initial treatment of choice at the standard dose of 1 mg/kg twice a day subcutaneously (with the necessary adjustments for kidney function). In patients with thrombocytopenia and renal failure, half the conventional dose of LMWH is often administered [4].

The main advantages of LMWH when compared to VKA are the fixed dose without the need for laboratory monitorization [33]. However, due to the need for parenteral administration and cost issues, oral options are

normally preferred for long-term treatment [2]. VKA appear to be a safe option for Child-Pugh A and B (7 points). However, maintaining the international normalized ratio between 2 and 3 could be a challenge in these patients [2].

Direct oral anticoagulants (DOACs) are becoming an alternative to VKA [34]. However, despite several cohort studies confirming their efficacy and safety, there are still limited data from large studies regarding their safety in patients with cirrhosis as most of these patients were excluded from clinical trials [35]. In Child-Pugh class A patients, DOACs seem to be safe, but caution is needed in Child-Pugh class B patients and they are not indicated in Child Pugh class C [36]. Dose adjustment of DOACs is required in patients with renal impairment as shown in Table 1.

In patients with advanced cirrhosis (Child-Pugh B  $\geq 8$  points and Child-Pugh C), LMWH seems to be a safer option for long-term treatment [4]. During the course of treatment, an abdominal CT or MRI should be done after 3 months and then at 6 months to evaluate the efficacy of anticoagulation [1]. Anticoagulant treatment should be maintained for at least 6 months or indefinitely in patients on liver transplant waiting list and in those with SMV involvement [2]. The recurrence of thrombosis after stopping anticoagulant therapy in these patients is high with rates varying between 27% and 38%, and therefore, maintaining patients on anticoagulation should be considered especially in the absence of contraindications or adverse events [4, 29].

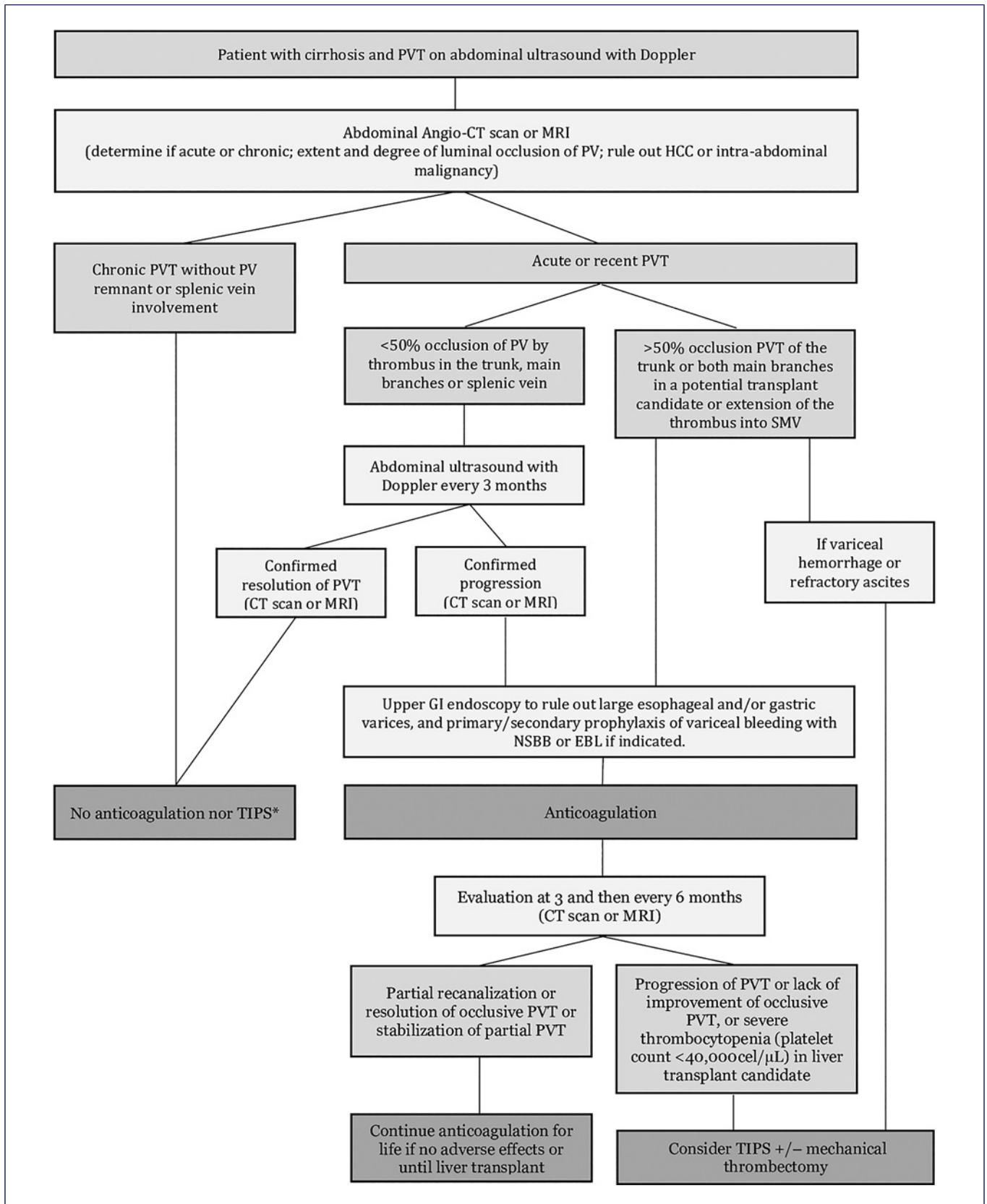
#### *Thrombolysis*

Thrombolysis, as used in other venous territories, has been reported to be effective in patients with cirrhosis who develop PVT, but significant procedure-related morbidity and mortality have been reported and there is no evidence that it is superior to anticoagulation alone in recent or acute PVT and therefore the most recent guidelines do not recommend this approach routinely [2]. In selected cases of recent PVT in whom intestinal ischemia persists despite anticoagulation, this approach could be an option [22].

#### *Transjugular Intrahepatic Portosystemic Shunt*

TIPS creates a low-pressure channel to bypass portal venous flow directly to the hepatic veins through a stent [11]. TIPS can be placed in a recanalized main PV or in a dominant collateral [37]. Often, the aim of TIPS is not to recanalize the thrombus, but to treat the PH-related complications due to it and guarantee the patency of portal tract [2].

TIPS may be useful in selected patients with PVT who have contraindications for anticoagulant therapy due to severe thrombocytopenia or in those who develop adverse events related to anticoagulant therapy, have progression of



**Fig. 3.** Flowchart illustrating management of nontumoral PVT in cirrhosis. Adapted from Senzolo et al. [2].

**Table 1.** DOAC treatment doses for PVT treatment

DOAC	Hepatic metabolism	Dose adjustment for renal impairment	Standard manutention dose for PVT treatment	Child-pugh class
Rivaroxaban	Yes	Yes	20 mg once daily 15 mg once daily if creatinine clearance $\leq 50$ mL/min	Safe in child-pugh A; use with caution in child-pugh B; contraindicated in child-pugh C
Apixaban			5 mg twice daily 2.5 mg twice daily if at least two of the following conditions: age $\geq 80$ years old, $\leq 60$ kg, or creatinine $\geq 1.5$ mg/dL	
Edoxaban			60 mg once daily 30 mg once daily if at least one of the following conditions: $\leq 60$ kg and creatinine clearance $\leq 50$ mL/min	
Dabigatran			150 mg twice daily 110 mg twice daily if the age is $\geq 80$ years old or increased bleeding risk Not recommended if creatinine clearance $\leq 30$ mL/min	

PVT on anticoagulation, and have PHT complications or no response after 6 months of anticoagulation [2, 38]. In some patients with cirrhosis, PVT is detected at the time of a clinical decompensation event such as acute variceal bleeding. The indication for TIPS placement in refractory variceal bleeding or preemptive TIPS (Child-Pugh C  $< 14$  or Child-Pugh B  $> 7$  with active bleeding at index endoscopy or HVPG  $> 20$  mm Hg at the time of hemorrhage) is not affected in those patients who have concomitant PVT [39].

A recent meta-analysis demonstrated that TIPS for PVT recanalization was feasible, effective, and safe [38]. The technical success is around 95% [38], and failure to place TIPS was closely related to associated portal cavernoma and the degree of thrombosis within each venous segment of the portal venous system and extension into the SMV and splenic vein [37, 38]. In potential OLT candidates with chronic and complete PVT, PV recanalization and TIPS creation could also be considered to facilitate transplant eligibility [40]. Another key point in TIPS is the patency of the stent (around 89%), with a better performance with covered stents [38]. The use of a trans-splenic approach followed by TIPS creation in order to reestablish a patent main PV has been reported in a single-center case series [41].

There is controversy about post-TIPS anticoagulation to prevent de novo PVT as well as to prevent thrombus extension and maintain the recanalization of PV achieved [42, 43]. In the meta-analysis by Guo et al. [44], post-TIPS anticoagulation was found to be associated with a higher risk of rebleeding. A recent

randomized control trial suggested that TIPS placement alone can achieve high PVT recanalization rates possibly due to an increase in blood flow velocity in the splanchnic circulation [45]. However, the study results require validation and a risk-benefit evaluation should always be considered. We continue to favor anticoagulant therapy in extensive PVT especially when the SMV is involved.

The TIPS procedure is invasive, with risks that increase when this technique is combined with mechanical thrombectomy and direct catheter thrombolysis [38]. Also, post-TIPS cardiac dysfunction and encephalopathy are important safety concerns [46]. Post-TIPS encephalopathy has been reported to occur in 17–29% of patients [38].

The TIPS studies on PVT have some limitations. First of all, in most of the studies the indication for TIPS was PHT complications such as variceal hemorrhage and refractory ascites, and not the PVT itself, and most studies excluded chronic PVT, with an unknown impact on the technical success rates and adverse events [46].

The differences in PVT recanalization rates and adverse events and limitations of anticoagulant therapy and TIPS placement for management of PVT are summarized in Table 2. After TIPS placement in patients with cirrhosis and PVT, a careful follow-up with scheduled TIPS venography in the first 2 months is crucial to access its patency and existence of residual PVT. Depending on the findings, interventions to perform additional PV recanalization or embolize spontaneous competing portosystemic shunts could be needed to maintain efficacy [40].



**Table 2.** Comparison of anticoagulant therapy versus TIPS in the management of nontumoral PVT in cirrhosis

	Anticoagulation	TIPS
Indications according to clinical orientations/guidelines	Recent occlusive or partially occlusive (>50%) thrombosis of the main PV or mesenteric veins [22] In PVT, consider anticoagulation at the therapeutic dose for at least 6 months [21] In patients with SMV thrombosis, with a past history suggestive of intestinal ischemia or liver transplant candidates, consider lifelong anticoagulation [21] Once PVT has recanalized, consider prolonging anticoagulation for some months and until transplant in liver transplant candidates [21]	TIPS should be considered in liver transplantation patients with chronic PVT that hinders a physiological anastomosis between graft and recipient PV [22] TIPS should be considered in patients with chronic PVT and recurrent bleeding and/or refractory ascites not manageable medically or endoscopically [22] In liver transplant candidates, who have progressive PVT not responding to anticoagulation, consider referring the patients for TIPS [21]
Recanalization success	57.6% of patients receiving anticoagulation achieved partial or total recanalization rate [29]	The 12-month recanalization rate in cirrhotic patients was 81% [38] Recanalization rates between 57.1% and 91.7% [44]
Complications	Bleeding rate was similar between groups (anticoagulation and no treatment), with no differences between hypertension-related bleeding [29]	Encephalopathy at 12 months varying between 17% and 29%. [38] Encephalopathy after TIPS in almost one-third of the patients [44] Post-TIPS encephalopathy and cardiac dysfunction are important safety concerns [47]
Procedure technical execution		TIPS creation was feasible in 95% of patients [38]
Procedure complications		The 12-month TIPS patency was 89%, with a better performance with covered stents [38] Anticoagulation post-TIPS was associated with more risk of rebleeding [44]
Impact on survival	Anticoagulation significantly reduced all-cause mortality, compared to no treatment. The benefit is independent from recanalization itself [29]	Survival of 89% at 12 months [38] No studies comparing TIPS versus anticoagulation in the management of PVT in cirrhosis
Bias and conditionings	Patients receiving anticoagulant therapy were more likely to receive prophylaxis of variceal bleeding compared to those who did not	The TIPS procedure is combined in some cases with mechanical thrombectomy and direct catheter thrombolysis [38] Some studies combined anticoagulation after TIPS [38, 44] In most of the studies, the indication for TIPS was PH complications like variceal hemorrhage and refractory ascites, and not the PVT itself [47] Most exclude chronic PVT, with an unknown impact on the procedure technical execution success rates [47]

PVT, portal vein thrombosis; TIPS, transjugular intrahepatic portosystemic shunt scan.

---

## Prognosis

The impact of PVT on hepatic decompensation and mortality in cirrhosis is still unclear. A large multicenter study showed that while the development of PVT correlates with the severity of liver disease at baseline, there was no association between PVT and progression of hepatic decompensation over time [7]. A small prospective randomized controlled trial comparing enoxaparin to placebo in the prevention of PVT in high-risk patients with cirrhosis without PVT at baseline showed not only efficacy in the prevention of development of PVT but also a higher survival and lower risk of decompensation in those who received enoxaparin during 1 year [48]. In this study, patients receiving anticoagulation were found to have lower rates of bacterial translocation and lower levels of inflammatory markers in the serum compared to those who did not receive anticoagulation [48].

There are no clear data about the impact of PVT on pretransplant mortality, with studies being contradictory [49, 50]. The same applies to posttransplant survival, with some studies showing no differences between patients with PVT and without and other studies showing higher morbidity and short-term mortality post liver transplant in those patients who had PVT at the time of liver transplantation [49, 51, 52]. In a recent study, comparing PVT recanalization or progression of the thrombus in cirrhosis, there were no differences observed between these patients in terms of 2-year survival, episodes of hepatic decompensation, hospital admissions, or need for liver transplantation [53].

In another study, in a subgroup analysis, any anticoagulant therapy in Child-Pugh B and C patients with PVT was associated with significant improvement in OLT-free survival [4]. In the same study, there was no overall difference in OLT-free survival in patients with any recanalization of PVT compared to no recanalization. These findings suggest that the potential benefit of anticoagulant therapy may go beyond macroscopic recanalization of PVT and may improve survival in patients with advanced cirrhosis [4]. Recently, in a meta-analysis by Guerrero et al. [29], anticoagulant therapy in nontumoral PVT in cirrhosis was found to significantly improve survival compared to no anticoagulation and this benefit was independent of the degree of PVT recanalization.

---

## Conclusion

PVT is a common complication in patients with advanced cirrhosis. Cross-sectional imaging with CT scan or MRI is essential to correctly determine the age of

thrombus whether acute or chronic and the extent and degree of luminal occlusion in PVT and to rule out malignancy.

Anticoagulation is the cornerstone of PVT treatment especially in those patients who are candidates for liver transplantation, who are symptomatic, and in those with concomitant thrombosis of the SMV. Management decisions should be individualized after carefully evaluating potential risks and benefits of anticoagulant therapy. The risk of rethrombosis is not negligible, and the anticoagulant therapy should not be stopped, especially in liver transplant candidates. TIPS should be considered in patients who have contraindications to anticoagulation, have concomitant PH complications, develop adverse events, or have progression of thrombosis on anticoagulant therapy.

---

## Acknowledgments

We would like to express our gratitude to Dr. Inês Leite, Consultant Radiologist, Hospital de Santa Maria – Centro Hospitalar Universitário Lisboa Norte, for her enthusiasm and expertise in evaluating patients with vascular pathology of the liver and for helpful advice in preparation of this manuscript. We are grateful to Dr. João Pereira da Silva, Consultant Gastroenterologist, Hospital dos Lusíadas and Dr. Ana Júlia Pedro, Consultant Internist, Hospital de Santa Maria – Centro Hospitalar Universitário Lisboa Norte, for their valuable comments and suggestions.

---

## Statement of Ethics

Ethical review and approval were not required, as the study is based exclusively on the published literature.

---

## Conflict of Interest Statement

The authors have no conflicts of interest to declare.

---

## Funding Sources

This review had no funding resources.

---

## Author Contributions

All the authors made substantial contributions to the article, critically revised the manuscript, and have approved the final version of the manuscript.

## References

- Intagliata NM, Caldwell SH, Tripodi A. Diagnosis, development, and treatment of portal vein thrombosis in patients with and without cirrhosis. *Gastroenterology*. 2019;156(6):1582–99.e1.
- Senzolo M, Garcia-Tsao G, García-Pagán JC. Current knowledge and management of portal vein thrombosis in cirrhosis. *J Hepatol*. 2021;75(2):442–53.
- Turon F, Driever EG, Baiges A, Cerda E, García-Criado Á, Gilbert R, et al. Predicting portal thrombosis in cirrhosis: a prospective study of clinical, ultrasonographic and hemostatic factors. *J Hepatol*. 2021;75(6):1367–76.
- Noronha Ferreira C, Reis D, Cortez-Pinto H, Tato Marinho R, Gonçalves A, Palma S, et al. Anticoagulation in cirrhosis and portal vein thrombosis is safe and improves prognosis in advanced cirrhosis. *Dig Dis Sci*. 2019;64(9):2671–83.
- Ögren M, Bergqvist D, Björck M, Acosta S, Eriksson H, Sternby NH. Portal vein thrombosis: prevalence, patient characteristics and lifetime risk: a population study based on 23796 consecutive autopsies. *World J Gastroenterol*. 2006;12(13):2115–9.
- Zocco MA, Di Stasio E, De Cristofaro R, Novi M, Ainora ME, Ponziani F, et al. Thrombotic risk factors in patients with liver cirrhosis: correlation with MELD scoring system and portal vein thrombosis development. *J Hepatol*. 2009;51(4):682–9.
- Nery F, Chevret S, Condat B, de Raucourt E, Boudaoud L, Rautou PE, et al. Causes and consequences of portal vein thrombosis in 1,243 patients with cirrhosis: results of a longitudinal study. *Hepatology*. 2015;61(2):660–7.
- Noronha Ferreira C, Marinho RT, Cortez-Pinto H, Ferreira P, Dias MS, Vasconcelos M, et al. Incidence, predictive factors and clinical significance of development of portal vein thrombosis in cirrhosis: a prospective study. *Liver Int*. 2019;39(8):1459–67.
- DeLeve LD, Valla DC, Garcia-Tsao G; American Association for the Study Liver Diseases. Vascular disorders of the liver. *Hepatology*. 2009;49(5):1729–64.
- Xu S, Guo X, Yang B, Romeiro FG, Prignano M, Méndez-Sánchez N, et al. Evolution of nonmalignant portal vein thrombosis in liver cirrhosis: a pictorial review. *Clin Transl Gastroenterol*. 2021;12(10):e00409–8.
- Faccia M, Ainora ME, Ponziani FR, Riccardi L, Garcovich M, Gasbarrini A, et al. Portal vein thrombosis in cirrhosis: why a well-known complication is still matter of debate. *World J Gastroenterol*. 2019;25(31):4437–51.
- Anton A, Campreciós G, Pérez-Campuzano V, Orts L, García-Pagán JC, Hernández-Gea V. The pathophysiology of portal vein thrombosis in cirrhosis: getting deeper into virchow's triad. *J Clin Med*. 2022;11(3):800.
- Abdel-Razik A, Mousa N, Elhelaly R, Tawfik A. De-novo portal vein thrombosis in liver cirrhosis: risk factors and correlation with the Model for End-stage Liver Disease scoring system. *Eur J Gastroenterol Hepatol*. 2015;27(5):585–92.
- Maruyama H, Okugawa H, Takahashi M, Yokosuka O. De novo portal vein thrombosis in virus-related cirrhosis: predictive factors and long-term outcomes. *Am J Gastroenterol*. 2013;108(4):568–74.
- Xu X, Guo X, De Stefano V, Silva-Junior G, Goyal H, Bai Z, et al. Nonselective beta-blockers and development of portal vein thrombosis in liver cirrhosis: a systematic review and meta-analysis. *Hepatol Int*. 2019;13(4):468–81.
- Lisman T, Hernandez-Gea V, Magnusson M, Roberts L, Stanworth S, Thachil J, et al. The concept of rebalanced hemostasis in patients with liver disease: communication from the ISTH SSC working group on hemostatic management of patients with liver disease. *J Thromb Haemost*. 2021;19(4):1116–22.
- Stine JG, Argo CK, Pelletier SJ, Maluf DG, Caldwell SH, Northup PG. Advanced non-alcoholic steatohepatitis cirrhosis: a high-risk population for pre-liver transplant portal vein thrombosis. *World J Hepatol*. 2017;9(3):139–46.
- Ayala R, Grande S, Bustelos R, Ribera C, García-Sesma A, Jimenez C, et al. Obesity is an independent risk factor for pre-transplant portal vein thrombosis in liver recipients. *BMC Gastroenterol*. 2012;12:114.
- Driever EG, von Meijenfeldt FA, Adelmeijer J, de Haas RJ, van den Heuvel MC, Nagasami C, et al. Nonmalignant portal vein thrombi in patients with cirrhosis consist of intimal fibrosis with or without a fibrin-rich thrombus. *Hepatology*. 2022;75(4):898–911.
- Nicoară-Farcău O, Soy G, Magaz M, Baiges A, Turon F, Garcia-Criado A, et al. New insights into the pathogenesis, risk factors, and treatment of portal vein thrombosis in patients with cirrhosis. *Semin Thromb Hemost*. 2020;46(6):673–81.
- European Association for the Study of the Liver Electronic address easloffice@easloffice.eu. EASL clinical practice guidelines: vascular diseases of the liver. *J Hepatol*. 2016;64(1):179–202.
- Northup PG, Garcia-Pagan JC, Garcia-Tsao G, Intagliata NM, Superina RA, Roberts LN, et al. Vascular liver disorders, portal vein thrombosis, and procedural bleeding in patients with liver disease: 2020 practice guidance by the American association for the study of liver diseases. *Hepatology*. 2021;73(1):366–413.
- Yerdel MA, Gunson B, Mirza D, Karayalin K, Olliff S, Buckels J. Portal vein thrombosis in adults undergoing liver transplantation: risk factors, screening, management, and outcome. *Transplantation*. 2000;69(9):1873–81.
- Chen H, Turon F, Hernández-Gea V, Fuster J, Garcia-Criado A, Barrufet M, et al. Non-tumoral portal vein thrombosis in patients awaiting liver transplantation. *Liver Transpl*. 2016;22(3):352–65.
- Sarin SK, Philips CA, Kamath PS, Choudhury A, Maruyama H, Nery FG, et al. Toward a comprehensive new classification of portal vein thrombosis in patients with cirrhosis. *Gastroenterology*. 2016;151(4):574–7.e3.
- Ferreira CN. Anticoagulation for nontumoral portal vein thrombosis portal vein thrombosis. *Portal vein thrombosis*. 2021. vol. 10; p. 89–102.
- Sharma AM, Zhu D, Henry Z. Portal vein thrombosis: when to treat and how? *Vasc Med*. 2016;21(1):61–9.
- Wang L, Guo X, Xu X, De Stefano V, Plessier A, Noronha Ferreira C, et al. Anticoagulation improves survival in patients with cirrhosis and portal vein thrombosis: results of a meta-analysis. *Adv Ther*. 2021;38(1):495–520.
- Guerrero A, Campo LD, Piscaglia F, Scheiner B, Han G, Violi F, et al. Anticoagulation improves survival in patients with cirrhosis and portal vein thrombosis: the IMPORTANT competing-risk meta-analysis. *J Hepatol*. 2023;79(1):69–78.
- Rodriguez-Castro KI, Vitale A, Fadin M, Shalaby S, Zerbinati P, Sartori MT, et al. A prediction model for successful anticoagulation in cirrhotic portal vein thrombosis. *Eur J Gastroenterol Hepatol*. 2019;31(1):34–42.
- Delgado MG, Seijo S, Yepes I, Achécar L, Catalina MV, García-Criado A, et al. Efficacy and safety of anticoagulation on patients with cirrhosis and portal vein thrombosis. *Clin Gastroenterol Hepatol*. 2012;10(7):776–83.
- Loffredo L, Pastori D, Farcomeni A, Violi F. Effects of anticoagulants in patients with cirrhosis and portal vein thrombosis: a systematic review and meta-analysis. *Gastroenterology*. 2017;153(2):480–7.e1.
- Nery F, Valadares D, Morais S, Gomes MT, De Gottardi A. Efficacy and safety of direct-acting oral anticoagulants use in acute portal vein thrombosis unrelated to cirrhosis. *Gastroenterol Res*. 2017;10(2):141–3.
- Lv Y, Bai W, Li K, Wang Z, Guo W, Luo B, et al. Anticoagulation and transjugular intrahepatic portosystemic shunt for the management of portal vein thrombosis in cirrhosis: a prospective observational study. *Am J Gastroenterol*. 2021;116(7):1447–64.
- Elhosseiny S, Al Moussawi H, Chalhoub JM, Lafferty J, Deeb L. Direct oral anticoagulants in cirrhotic patients: current evidence and clinical observations. *Can J Gastroenterol Hepatol*. 2019;2019:4383269.

- 36 European Association for the Study of the Liver Electronic address easloffice@easloffice.eu European Association for the Study of the Liver. EASL Clinical Practice Guidelines on prevention and management of bleeding and thrombosis in patients with cirrhosis. *J Hepatol*. 2022;76(5):1151–84.
- 37 Han G, Qi X, He C, Yin Z, Wang J, Xia J, et al. Transjugular intrahepatic portosystemic shunt for portal vein thrombosis with symptomatic portal hypertension in liver cirrhosis. *J Hepatol*. 2011;54(1):78–88.
- 38 Rodrigues SG, Sixt S, Abraldes JG, De Gottardi A, Klinger C, Bosch J, et al. Systematic review with meta-analysis: portal vein recanalisation and transjugular intrahepatic portosystemic shunt for portal vein thrombosis. *Aliment Pharmacol Ther*. 2019;49(1):20–30.
- 39 de Franchis R, Bosch J, Garcia-Tsao G, Reiberger T, Ripoll C; Baveno VII Faculty. Baveno VII – renewing consensus in portal hypertension. *J Hepatol*. 2022;76(4):959–74.
- 40 Boike JR, Thornburg BG, Asrani SK, Fallon MB, Fortune BE, Izzy MJ, et al. North American practice-based recommendations for transjugular intrahepatic portosystemic shunts in portal hypertension. *Clin Gastroenterol Hepatol*. 2022 Aug;20(8):1636–62.e36.
- 41 Thornburg B, Desai K, Hickey R, Hohlastos E, Kulik L, Ganger D, et al. Pretransplantation portal vein recanalization and transjugular intrahepatic portosystemic shunt creation for chronic portal vein thrombosis: final analysis of a 61-patient cohort. *J Vasc Interv Radiol*. 2017;28(12):1714–21.e2.
- 42 Jiao P, Chen XY, Zheng HY, Qin J, Li C, Zhang XL. Anticoagulation after transjugular intrahepatic portosystemic shunt for portal hypertension: a systematic review and meta analysis. *Med*. 2022;101(26):E29742.
- 43 Senzolo M, Tibbals J, Cholongitas E, Triantos CK, Burroughs AK, Patch D. Transjugular intrahepatic portosystemic shunt for portal vein thrombosis with and without cavernous transformation. *Aliment Pharmacol Ther*. 2006;23(6):767–75.
- 44 Guo DF, Fan LW, Le Q, Huang CB. Transjugular intrahepatic portosystemic shunt for the prevention of rebleeding in patients with cirrhosis and portal vein thrombosis: systematic review and meta-analysis. *Front Pharmacol*. 2022;13:968988.
- 45 Wang Z, Jiang MS, Zhang HL, Weng NN, Luo XF, Li X, et al. Is post-TIPS anticoagulation therapy necessary in patients with cirrhosis and portal vein thrombosis? A randomized controlled trial. *Radiology*. 2016;279(3):943–51.
- 46 García-Pagán JC, Saffo S, Mandorfer M, García-Tsao G. Where does TIPS fit in the management of patients with cirrhosis? *JHEP Rep*. 2020;2(4):100122.
- 47 García-Pagán JC, Saffo S, Mandorfer M, Garcia-Tsao G. Where does TIPS fit in the management of patients with cirrhosis? *JHEP Rep*. 2020 May 23;2(4):100122.
- 48 Villa E, Cammà C, Marietta M, Luongo M, Critelli R, Colopi S, et al. Enoxaparin prevents portal vein thrombosis and liver decompensation in patients with advanced cirrhosis. *Gastroenterology*. 2012;143(5):1253–60.e4.
- 49 Englesbe MJ, Schaubel DE, Cai S, Guidinger MK, Merion RM. Portal vein thrombosis and liver transplant survival benefit. *Liver Transpl*. 2010;16(8):999–1005.
- 50 Ghabril M, Agarwal S, Lacerda M, Chalasani N, Kwo P, Tector AJ. Portal vein thrombosis is a risk factor for poor early outcomes after liver transplantation: analysis of risk factors and outcomes for portal vein thrombosis in waitlisted patients. *Transplantation*. 2016;100(1):126–33.
- 51 Zanetto A, Rodriguez-Kastro KI, Germani G, Ferrarese A, Cillo U, Burra P, et al. Mortality in liver transplant recipients with portal vein thrombosis: an updated meta-analysis. *Transpl Int*. 2018;31(12):1318–29.
- 52 Ravaioi M, Zanello M, Grazi GL, Ercolani G, Cescon M, Del Gaudio M, et al. Portal vein thrombosis and liver transplantation: evolution during 10 years of experience at the university of bologna. *Ann Surg*. 2011;253(2):378–84.
- 53 Luca A, Caruso S, Milazzo M, Marrone G, Mamone G, Crinò F, et al. Natural course of extrahepatic nonmalignant partial portal vein thrombosis in patients with cirrhosis. *Radiology*. 2012;265(1):124–32.