

Percutaneous Endoscopic Sigmoidopexy: Still a Way to Go

Isabel Garrido^{a, b} Armando Peixoto^{a, b} Guilherme Macedo^{a, b}

^aGastroenterology Department, Centro Hospitalar Universitário de São João, Porto, Portugal; ^bWorld Gastroenterology Organization (WGO) Porto Training Center, Porto, Portugal

Keywords

Percutaneous endoscopic sigmoidopexy · Sigmoid volvulus · Colonoscopy

Sigmoidopexia endoscópica percutânea: um caminho ainda a percorrer

Palavras Chave

Sigmoidopexia endoscópica percutânea · Vólvulo do simgoide · Colonoscopia

An 85-year-old man with a past medical history of Parkinson's disease, ischemic cardiomyopathy, and osteo-articular pathology presented to the emergency department with acute colonic obstruction. Plain abdominal radiograph showed a sigmoid volvulus, and endoscopic decompression was performed. Ten days later, the patient presented a new episode of sigmoid volvulus. Endoscopic detorsion was repeated. Given the poor performance status and advanced dementia, the patient was considered unfit of surgery. After a multidisciplinary team discussion, it was decided to perform a percutaneous endoscopic sigmoidopexy (PES), and bowel preparation was initiated.

Cefazolin was administered 30 min before the procedure. A complete colonoscopy was performed under sedation with midazolam. The patient was then mobilized into supine position, so that it was possible to identify the



Fig. 1. Entuit Scure system (Cook Medical®).

transillumination through the abdominal wall in the site of the sigmoid colon. The abdominal operator performed digital compression to assure that the bowel wall was in contact with the abdominal wall. Following lidocaine injection, the abdominal operator punctured the distal sigmoid colon wall under endoscopic guidance, using three Entuit Scure systems, Cook Medical® (Fig. 1) with a 1-cm distance between each other in a triangular disposition (online suppl. Video 1; for all online suppl. material, see <https://doi.org/10.1159/000534801>). Another fixation was made in the proximal sigmoid colon using the same technique (Fig. 2a, b).

An abdominal radiograph was performed on the day of the procedure, with no evidence of complications besides mild pneumoperitoneum (Fig. 2c). The patient completed

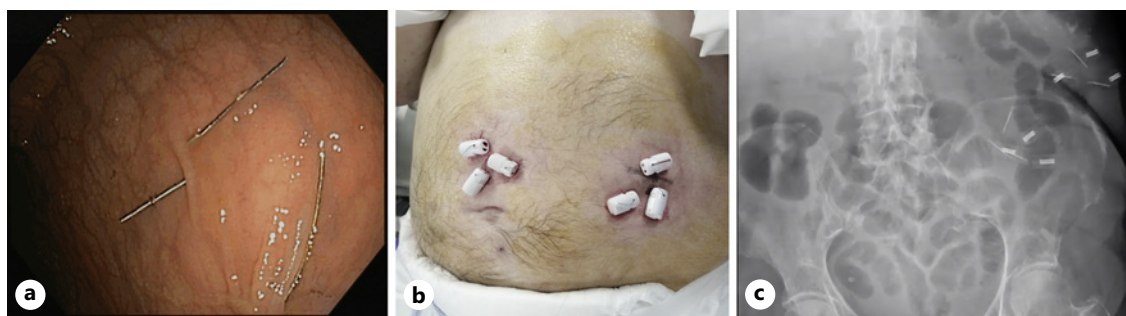


Fig. 2. Fixation of sigmoid colon to the abdominal wall in a triangular disposition. **a** Endoscopic view. **b** External view. **c** Radiological view.

5 days of prophylactic antibiotic therapy (ciprofloxacin and metronidazole). Except for mild abdominal pain, there were no complications. After 4 months of follow-up, there was no further recurrence of the sigmoid volvulus.

The treatment of recurrent sigmoid volvulus typically involves endoscopic decompression followed by surgical resection due to the high risk of recurrence [1]. However, most cases occur in elderly patients with multiple comorbidities who are not suitable candidates for surgery. PES has been seldom described as an effective and safe procedure to prevent the recurrence of sigmoid volvulus in selected patients who are non-surgical candidates [2, 3]. We present a successful case of PES as an alternative in the treatment of recurrent sigmoid volvulus, using a new device, that is, equally effective but more accessible and practical.

Statement of Ethics

Written informed consent was obtained from the participant for publication of the details of his medical case and any accompanying images.

References

- 1 Naveed M, Jamil LH, Fujii-Lau LL, Al-Haddad M, Buxbaum JL, Fishman DS, et al. American Society for Gastrointestinal Endoscopy guideline on the role of endoscopy in the management of acute colonic pseudo-obstruction and colonic volvulus. *Gastrointest Endosc.* 2020;91(2):228–35.
- 2 Pinedo G, Kirberg A. Percutaneous endoscopic sigmoidopexy in sigmoid volvulus with T-fasteners: report of two cases. *Dis Colon Rectum.* 2001;44(12):1867–9; discussion 9–70.
- 3 Tin K, Sobani ZA, Anyadike N, Serur A, Mayer I, Iswara K, et al. Percutaneous endoscopic sigmoidopexy using T-fasteners for management of sigmoid volvulus. *Int J Colorectal Dis.* 2017;32(7):1073–6.

Conflict of Interest Statement

The authors have no disclosures to report.

Funding Sources

The authors have no funding sources to declare.

Authors contributions

Isabel Garrido did literature review and drafted the manuscript. Isabel Garrido, Armando Peixoto, and Guilherme Macedo have critically revised and finalized the manuscript. All authors have approved the final version of the manuscript.

Data Availability Statement

All data generated or analyzed during this study are included in this article. Further inquiries can be directed to the corresponding author.