




## CASE REPORTS

### Phytophotodermatitis: a challenging diagnosis in children

#### Fitofotodermatite: um desafio diagnóstico em idade pediátrica

Ana Isabel Costa<sup>1</sup> , Catarina Vilarinho<sup>2</sup> , Olga Pereira<sup>2</sup> 

#### ABSTRACT

Phytophotodermatitis, a form of plant dermatitis, is a common phototoxic reaction resulting from the interaction between photosensitising botanical substances present in several common plant families and ultraviolet radiation. We report a case of phytophotodermatitis in an 8-month-old infant who presented a progressively well-demarcated erythematous rash with blisters and subsequent erosions covering both upper limbs and feet. Additionally, asymmetric hyperpigmented streaks with bizarre configurations, were observed in photo-exposed areas. The diagnosis of phytophotodermatitis was established based on the history of outdoor activities with sun exposure and physical examination findings. Topical treatment with antibiotic and corticosteroid cream was started. The phytophotodermatitis is a self-limiting condition, which can be challenging to diagnosis in this age group due to heterogeneity of clinical manifestations, which can mimic a range of different diseases, such as non-accidental injury in the context of child abuse, potentially delaying timely diagnosis and treatment.

**Keywords:** erythematous rash; furocumarin; hyperpigmentation streaks; photodermatitis; phototoxic reaction; phytophotodermatitis

#### RESUMO

A fitofotodermatite é uma reação cutânea fototóxica comum, que resulta da interação entre substâncias botânicas fotossensibilizantes presentes em algumas plantas e a exposição a radiação ultravioleta. Descrevemos um caso de fitofotodermatite num lactente de 8 meses de idade que apresentou lesões cutâneas eritematosas progressivas, bem delimitadas, com bolhas e algumas erosões, ao nível dos membros superiores e pés. Adicionalmente, foram observadas máculas lineares de hiperpigmentação, com configurações bizarras, nas áreas foto-expostas. O diagnóstico de fitofotodermatite foi estabelecido com base na história clínica de atividades ao ar livre com exposição solar e os achados no exame físico. Iniciou tratamento com corticoide e antibiótico tópico. A fitofotodermatite é uma condição autolimitada, que pode ser um desafio diagnóstico em idade pediátria, relacionado com a heterogeneidade das manifestações clínicas que podem mimetizar um conjunto diversificado de patologias, como as lesões não-acidentais em contexto de abuso infantil, o que pode atrasar o seu diagnóstico e tratamento.

**Palavras-Chaves:** fitofotodermatite; fotodermatite; furanocumarinas; hiperpigmentação; rash eritematoso; reação fototóxica

1. General and Family Medicine, USF Nova Estação, Unidade Local de Saúde Médio Ave. 4760-101 Vila Nova de Famalicão, Portugal. ana.if.costa29@gmail.com
2. Department of Dermatology, Unidade Local de Saúde Alto Ave. 4835-044 Guimarães, Portugal. catarinavilarinho@hospitaldeguimaraes.min-saude.pt; olgapereira@hospitaldeguimaraes.min-saude.pt

## KEY POINTS

### What is known:

- phytophotodermatitis is a common phototoxic non-immunologic cutaneous reaction;
- phytophotodermatitis should be considered in any child presenting with erythematous areas with vesicles, blisters or erosions and hyperpigmented macules;
- the diagnosis of phytophotodermatitis is clinical, based on clinical history and physical examination.

### What is added:

- the main differential diagnosis include sunburn, drug-related photosensitivity, bullous impetigo, contact dermatitis and child abuse;
- treatment is mainly symptomatic;
- The prognosis is favorable, with spontaneous healing.

## INTRODUCTION

Phytophotodermatitis is a phototoxic, non-immunologic cutaneous reaction resulting from contact with photosensitizing botanical substances and ultraviolet radiation.<sup>(1,2)</sup> The incidence rate is unknown. It may occur in children who play outdoors and are unaware of the risk associated with furanocoumarins, which are found in the leaves, roots and fruits of numerous plants.<sup>(3,4)</sup>

Furanocoumarins are phototoxic compounds present in several common plant families, including Umbelliferae (e.g., parsley, celery, parsnip, carrot), Rutaceae (e.g., lime, bitter orange) and Moraceae (e.g., fig). These compounds are capable of inducing an acute phototoxic reaction.<sup>(2,4)</sup>

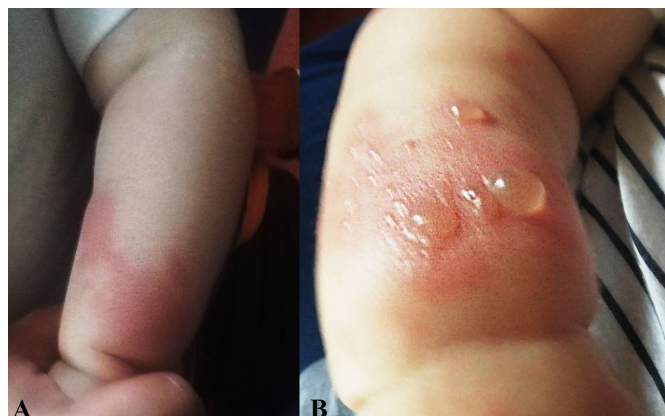Diagnosis is based on clinical findings. Clinically, it manifests with variable reaction patterns, ranging from eczema, erythema, edema, vesicles or blisters, followed by hyperpigmentation. Lesions typically appear 24 hours after exposure, peak at 48-72 hours, and, in most cases, resolve with minimal complications.<sup>(2-5)</sup>

This clinical report aims to highlight the main challenges in diagnosing phytophotodermatitis in pediatric patients.

## CASE REPORT

An eight-month-old boy was brought to a dermatology emergency consultation by his mother with a one-week history of a progressive erythematous rash on his arms and feet with associated blistering. The child was otherwise healthy, with no relevant medical history. There was no family history of cutaneous disorders reported. A detailed history revealed that the dermatitis lesions appeared a day after the boy had played in the family garden during sun exposure. His parents initially noticed erythematous rashes on his right upper limb, which progressed the following week to his left upper limb and

feet, eventually developing blisters (**Figure 1**). His parent did not report pruritus.



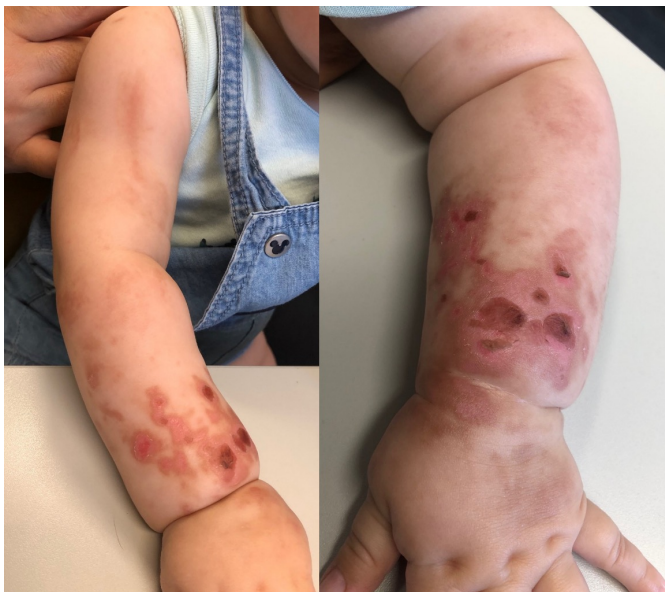**Figure 1** - Diffuse erythema (A) and multiples blisters on erythematous plaques (B), on upper limbs

On physical examination, he had a well-demarcated erythematous rash with erosions and some blisters distributed across both upper limbs and feet. On his arms, there were asymmetric hyperpigmentation streaks in a bizarre configuration consistent with a linear drip pattern in sun-exposed areas (**Figure 2**). The face, trunk, mucous membranes, palms and soles were spared. The infant was in good general health and afebrile. No laboratory studies or other exams were performed.

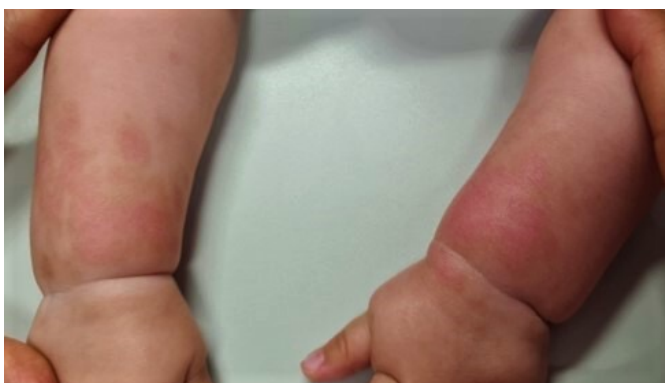The diagnosis of phytophotodermatitis was established based on the history of outdoor play with sun exposure and the streaky appearance of the rash, corresponding to areas where a plant-derived photosensitizing compound had come into contact with his skin. The plant responsible was not identified.

Topical treatment with an antibiotic (fusidic acid) and betamethasone cream was prescribed. In addition, the use of a mineral sunscreen with high UV protection, along with other measures to prevent further sun exposure, was recommended to minimize the severity of post-inflammatory hyperpigmentation.

A month after the injury, at the outpatient follow-up, the erythematous rash had significantly diminished and replaced with mild residual areas of post-inflammatory hyperpigmentation. His skin lesions healed well without evidence of scarring or others complications (Figure 3).



**Figure 2** - Erosions and blisters under erythematous skin and asymmetric bizarre hyperpigmentation streaks, on both upper limb



**Figure 3** - One month after injury, diminished erythema and small areas of postinflammatory hyperpigmentation

## DISCUSSION

Phytophotodermatitis is a type of contact dermatitis predominantly linked to cutaneous inflammatory phototoxic reactions. It is entirely independent of immunologic or allergic mechanisms and is induced by a photochemical mechanism.<sup>(6,7)</sup> The incidence is unknown. It is unquestionable that it can occur in any individual without particular predisposition, provided there is temporal exposure to both photosensitizing compounds and artificial or solar radiation. The cutaneous inflammatory reaction usually appears upon first exposure, without a refractory period, and remains consistent in later exposures.<sup>(3,4,6)</sup> Even though photodermatoses are common in adults, their diagnosis may be challenging in children due to the heterogeneity of clinical presentations and the difficulty in identifying trigger factors.<sup>(5)</sup>

Furanocoumarins are a group of phototoxic substances found in the sap of various plants or on the surface of fruits. Psoralens are the most common bioactive components of furanocoumarins.<sup>(4,6,8)</sup> It is well established that furanocoumarins sensitize epithelial DNA molecules when exposed to certain wavelengths of sunlight. Although all natural sunlight spectrum reaches the earth, only light spectra that are absorbed by the skin can cause photochemical reactions. Within this light spectra, ultraviolet light, in particular ultraviolet-A light (wavelengths between 320 - 400nm), is responsible for the majority of photoreactions leading to phytophotodermatitis. This photochemical interaction may result in cell death by damaging cell membranes and inducing cross-linking of pyrimidine bases in DNA (thymines and cytosines), thereby inhibiting cell division, DNA repair and DNA synthesis, ultimately leading to epidermal, dermal and endothelial cell damage. (6-8) Indeed, photodermatoses frequently occurs during spring and summer when furanocoumarins concentrations are higher and UV exposure is at its peak.<sup>(4,9)</sup>

Phytophotodermatitis is most commonly caused by ingestion or topical exposure to furanocoumarins, which are present in several common plant families, in particular Umbelliferae family which includes wild plants, food plants such as parsley, celery, parsnip, or carrot, and numerous garden plants.<sup>(6)</sup> Outside activities, as seen in our patient, may lead to contact with meadow grass, which belongs to the Umbelliferae family. Cases of phototoxic reactions have also been reported with the Rutaceae family which includes citrus species such as limes, and Moraceae family.<sup>(4,6)</sup>

The cutaneous phototoxic reaction is limited to areas of skin contaminated by photosensitizing plant substances and exposed to sunlight. The first dermatitis lesions usually appear 24 to 48 hours after contact, and the intensity of this interaction determines the severity of epidermal damage.<sup>(3,10)</sup> Patients can present with diverse clinical features, ranging from erythematous areas with associated erosions or blisters/vesicles in an eccentric and bizarre linear streaky configuration to well-demarcated lesions contrasting with healthy skin. Edema and bullae formation can occur in some cases. Pain and pruritus are uncommon. As acute-phase lesions heal, they are

replaced by pigmented macules resulting from post-inflammatory pigmentary alteration. These aesthetic consequences can persist for several weeks to months.<sup>(5-7,10)</sup> Some mild contact cases may present only with hyperpigmented macules, resembling streak-like marks (linear or serpiginous), drips, fingerprints or handprints, due to plant contact or secondary transfer of furanocoumarins from contaminated skin to unaffected areas.<sup>(7)</sup>

Diagnosis is based on clinical findings, through clinical history and physical examination. Skin biopsy or additional laboratory studies are usually unnecessary. However, phytophotodermatitis can mimic a range of different diseases, due to its bizarre lesions configurations, particularly in children. Differential diagnosis, in the acute phase, include sunburn, drug-related photosensitivity, herpes simplex lesions, infectious exanthema, bullous impetigo, contact dermatitis and non-accidental injury in context of child abuse.<sup>(6,7,9,11)</sup>

Phytophotodermatitis is a self-limited condition, usually without long-term sequelae, and treatment depends on the extent of the injuries. There are no treatment guidelines for phytophotodermatitis. The main therapeutic goals are symptom relief, morbidity reduction and prevention of complications. Topic steroids and emollients are recommended for moderate lesions, however in severe lesions, a short course of oral corticotherapy may be beneficial. Antibiotics, topical and/or systemic, are reserved for suspected secondary bacterial infections, a possible complication.<sup>(6,7,11)</sup> Additionally, the use of high-UVA-protection sunscreen, protecting clothing, such as gloves, long-sleeved shirts and trousers, can help prevent further light exposure and reduce the risk of post-inflammatory hyperpigmentation.<sup>(2)</sup>

This report highlights the importance of a detailed clinical interview and physical examination in the evaluation of dermatological lesions, especially in pediatric patients. The prognosis of phytophotodermatitis in children is favorable and avoiding suspected triggers is crucial to preventing recurrence.<sup>(6)</sup>

## AUTHORSHIP

Ana Isabel Costa – Investigation; Writing – original draft; Writing – review & editing

Catarina Vilarinho – Investigation; Writing – review & editing

Olga Pereira – Investigation; Writing – review & editing

## REFERENCES

1. Smith LG, Kabhrel C. Phytophotodermatitis. *Clin Pract Cases Emerg Med* 2017; 1(2):146-147. DOI: <https://doi.org/10.5811/cpcem.2017.1.32739>.
2. Coulson I. Phytophotodermatitis. *Dermnet*. Last Updated Nov 2021. <https://dermnetnz.org/topics/phytophotodermatitis>.
3. Harshman J, Quan Y, Hsiang D. Phytophotodermatitis: Rash with many faces. *Can Fam Physician*. 2017 Dec;63(12):938-940.
4. Moreau JF, English JC III, Gehris RP. Phytophotodermatitis. *J Pediatr Adolesc Gynecol* 2014; 27(2): 93-94. DOI: <https://doi.org/10.1016/j.jpag.2013.11.001>.
5. Machado M, Vidal RL, Cardoso P, Coelho S. Phytophotodermatitis: a diagnosis to consider. *BMJ Case Rep* 2015. DOI: <https://doi.org/10.1136/bcr-2015-213388>.
6. Picard C, Morice C, Moreau A, Domp Martin A, Stefan A, Verneuil L. Phytophotodermatitis in children: A difficult diagnosis Mimicking other Dermatitis. *J Dermatol Clin Res* 2017; 5(3): 1101. DOI : <https://doi.org/10.47739/2373-9371/1101>.
7. Abugroun A, Gaznabi S, Natarajan A, Dound H. Lime-induced phytophotodermatitis. *Oxford Medical Case Reports* 2019; 11,470-472. DOI: <https://doi.org/10.1093/omcr/omz113>.
8. Synder M, Turrentine JE, Cruz Jr PC. Photocontact Dermatitis and Its Clinical Mimics: an Overview for the Allergist. *Clinical Reviews in Allergy & Immunology* 2018 Feb. 56(1):32-40. DOI: 10.1007/s12016-018-8696-x.
9. Hill PF, Pickford M, Parkhouse N. Phytophotodermatitis mimicking child abuse. *J R Soc Med* 1998. 91:58. DOI: <https://doi.org/10.1177/014107689709001008>.
10. Byrne B, Mahmood W, Ramsay B, Ahmad K. Outdoor dining causing blisters: think infantile phytophotodermatitis. *BMJ Case Rep* 2021;14:e241631. Doi: <https://doi.org/10.1136/bcr-2021-241631>.
11. Papazoglou A, Mantadakis E. Fig Tree Leaves Phytophotodermatitis. *The journal of Pediatrics* 2021; 239:245-6. DOI: <https://doi.org/10.1016/j.jpeds.2021.08.029>.

## CORRESPONDENCE TO

Ana Isabel Costa  
General and Family Medicine  
USF Nova Estação  
Unidade Local de Saúde Médio Ave  
Av. 25 de Abril, 4760-101  
Vila Nova de Famalicão  
Email: ana.if.costa29@gmail.com

Received for publication: 19.12.2023

Accepted in revised form: 17.05.2024